

Antegrade cholecystectomy before ligating the elements.

A technique that reduces complications



Ann. Ital. Chir., 2019 90, 2: 162-164
pii: S0003469X19029543

Nicola Tartaglia, Fabio Petruzzelli, Fernanda Vovola, Alberto Fersini, Antonio Ambrosi

Department of Medical and Surgical Sciences, University of Foggia, Foggia, Italy

Antegrade cholecystectomy before ligating the elements. A technique that reduces complications.

BACKGROUND: In open surgery, the most common approach is Retrograde approach ("fundus first"), while is less frequent in laparoscopic cholecystectomy. Antegrade access, is obtained by putting in traction the infundibulum and reaching up to the fundus right before clipping the cystic. Our study analyzes a number of surgical procedures performed by surgeons with long experience in laparoscopy.

METHODS: From 2002 to 2017, 2020 laparoscopic cholecystectomies were performed at our Institution. The operative technique used since 2002 is the following: incision of the visceral peritoneum from the infundibulum away from Calot's triangle along the gallbladder bed up to the fundus and then to the infundibulum.

RESULTS: No bile duct injuries happened. Average operative time was 38 min. 30 conversions to an open procedure (1.5%) occurred, in patients with cholecystitis and cirrhosis Postoperative stay was mean 2 days with no delayed complications on follow up.

CONCLUSIONS: Gallbladder antegrade dissection for laparoscopic cholecystectomy may be an easier approach and may reduce the time of surgery. So it may be used as the standard procedure and not only be used for complicated cholecystectomies.

KEY WORDS: Difficult cholecystectomy, Laparoscopy, Antegrade dissection, Cholecystectomy, Cholecystitis, Fundus first

Introduction

Laparoscopic cholecystectomy (LC) represents one the most common surgical procedures in Europe (and all over the world). It is the standard procedure for the surgical therapy of patients with symptomatic cholelithiasis or acute cholecystitis.

The most significant LC complication is bile duct injury, which determines as consequence not only difficult procedures of repair (surgery, radiology and endoscopy), but

may have a serious impact on patients outcomes^{1,2}. In patients with acute cholecystitis, there are some difficulties in defining the biliary and vascular structures due to the inflammation of Calot. Gallbladder antegrade dissection (GAD) during laparoscopic cholecystectomy is a well-known technique in surgical practice.

The goal of this study was to demonstrate the validity of a surgical procedure that is safer than the routine operation and to evaluate the usefulness of Gallbladder antegrade dissection for reducing the risk of common biliary duct injuries and to show an easier and faster method than the traditional one.

Methods

From 2002 to 2017, 2020 laparoscopic cholecystectomies were performed at our Institution (University of Foggia, Department of Medical and Surgical Sciences, Division of General Surgery, Polyclinic of Foggia, Italy): 1390 for

Pervenuto in Redazione Settembre 2018. Accettato per la pubblicazione Ottobre 2018

Correspondence to: Nicola Tartaglia M.D. Riuniti Hospital, University of Foggia, Viale Pinto 1, 71122 Foggia, Italy (e-mail: nicola.tartaglia@unifg.it)

simple cholelithiasis, 630 for acute cholecystitis, it was introduced a change of surgical technique, so that antegrade dissection substituted retrograde dissection.

LC was performed using standard technique with 3 or 4 ports, electrocautery and a 30° laparoscope.

The procedure involves incision of the visceral peritoneum from the infundibulum away from Calot's triangle along the gallbladder bed up to the fundus; and then to the infundibulum so that the gallbladder is left pedunculated by the cystic artery and cystic duct, which can be clipped and divided in turn. This method of dissection has permitted safe and complete preparation of the cystic duct so that the cystic duct is isolated, identified, clipped, and divided easily and its position and connections with the principal biliary duct (PBD) may be easily seen. The data are summarized in Table I.

The cholecystectomies were made difficult by the following conditions: simple cholelithiasis, acute cholecystitis, cholelithiasis in a cirrhotic patients.

In each type of pathology, the clinical scenarios were the following:

- patients with uncomplicated cholelithiasis had pain in upper right quadrant, nausea, and vomiting;
- patients with acute cholecystitis had upper right quadrant pain and tenderness with rebound pain in some cases, fever (up to 39.5°C), nausea, and vomiting;
- patients with cirrhosis had pain in upper right quadrant, nausea, and sometimes vomiting.

Biochemical laboratories studies showed that:

- patients with acute cholecystitis had leukocytosis (up to 21000/ L) and an increase in GOT/GPT (up to 4 times the normal values);
- patients with non complicated cholelithiasis had a modest increase in the hepatic transaminases;
- in the patients with cirrhosis, we observed all the alterations of the hepatic function tests; all patients had up to an A6 Child-Pugh score.

The ultrasound imaging study showed that:

- in non complicated cholelithiasis, the US evaluation showed a normal thickness of the gallbladder wall (up to 6 mm);

- in the acute cholecystitis, the abdominal US evaluation showed signs of local gallbladder inflammation with an increase in the thickness of the gallbladder wall associated in some patients with empyema and pericholecystic fluid collection;

- cirrhotic patients had all the ultrasound signs of portal hypertension and no signs of gallbladder phlogosis .

All patients affected by simple cholelithiasis and the cirrhotic patients underwent a programmed laparoscopic cholecystectomy.

Patients with choledocholithiasis underwent endoscopic-retrograde-colangio-pancreatography (ERCP) with sphincterotomy before cholecystectomy.

All patients affected by acute cholecystitis underwent laparoscopic cholecystectomy within 24 hours to 72 hours after the admission.

We analyzed, the operative time, the conversions, the major morbidity, hemorrhages, PBD injury, and residual PBD stones.

Results

The elements analyzed were: accidental lesion of the PBD, dehiscence of the cystic duct, hemorrhage, choledocholithiasis, conversions to an open surgery, mean operative time, and hospital stay (Table II).

In this study, complications like PBD injuries were not reported.

Hemorrhagic complications and a more representative conversion rate are in evidence. Average operative time was 38 min. 30 conversions to an open procedure (1.5%) occurred, in patients with acute cholecystitis and cirrhosis.

Moreover, we noticed a decrease in the conversions to an open procedure with the GAD technique.

In our study complications didn't include ileus, but there were patients with surgical wound infections and in one case a wound seroma. The incidence complications was very low because of decreased wall dissection in laparoscopic approach. No mortality was observed.

Table I - Demographic Data

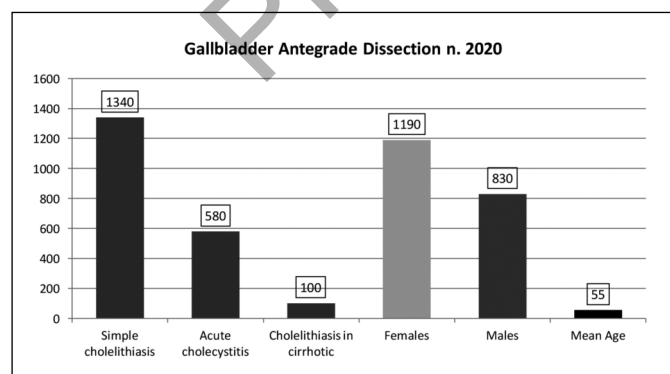
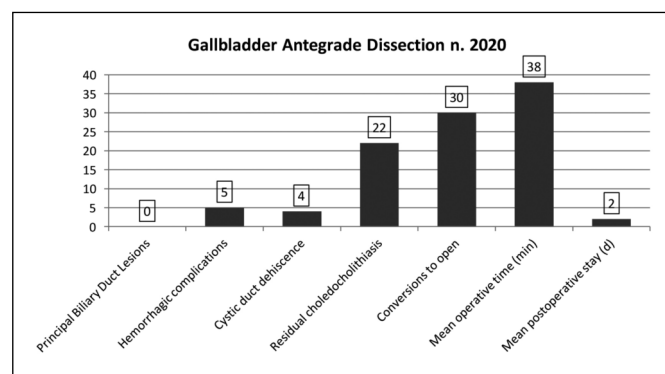


Table I - Results



Discussion

In our study cholelithiasis was the most frequent indication for cholecystectomy. Chronic cholecystitis is characterized by chronic inflammatory process of the gallbladder mainly caused by gallstones. These frequent attacks may cause gallbladder sclerosis.

The preoperative diagnosis of cholelithiasis was made by clinical and instrumental evaluation. Abdominal Ultrasonography (US) was the most common diagnostic tool used for the diagnosis of cholelithiasis. MRCP, prior to intervention, has been used in patients with clinical signs such as biliary colics with jaundice, fever, etc. or altered indexes of cholestasis, or dilation of common bile duct (CBD) greater than 8 mm³.

While in the subjects with acute cholecystitis there used to be a laparoscopic cholecystectomy (LC) relative indication, today this LC is also commonly applied on such subjects. But where anatomic and pathological problems cannot allow to identify with precision biliary tracts and cystic artery, open operation approach is more indicated. The rate of open operation in the laparoscopic surgery of acute cholecystitis is 4-35%^{4,5}. The aim of the antegrade laparoscopic approach is not at eliminating conversion to an open procedure⁶, which is safer for the patient, in some complicated cases. We think that antegrade dissection, used during laparoscopic cholecystectomy is not only safe and easy but it may also reduce the operation time as well.

In order to avoid CBD, it is recommended a full dissection of Calot's triangle with the neck of the gallbladder mobilized from the liver bed. In this study, the results of the intraoperative lesions are quite positive. Normally, antegrade dissection is the best choice for cholecystectomies made difficult by inflammation of Calot's triangle, fibrosis, or both, presence of fatty tissue, and portal hypertension⁷⁻¹⁰.

Moreover, the lesions of the CBD occur also in patients without any anatomic-pathologic alteration of Calot's triangle. In fact, the literature refers to a global incidence of about 1% (0.85%: one case every 120 laparoscopic cholecystectomies)⁵. In this study the low incidence of such complications like CBD injuries and hemorrhage may allow us to say that this surgical technique is extremely safe.

We also think that the laparoscopic cholecystectomy must always be performed by reducing as low as possible all the risks of iatrogenic injuries regardless of the presence of inflammation or fibrosis.

In this way, GAD may be used as an easy, safe, and time-sparing technique, and it may also used as a procedure for training all general surgery residents.

Another element of discussion is the possible migration of stones during GAD laparoscopic cholecystectomy.

In our study, the residual choledocholithiasis after laparoscopic cholecystectomy was the same as international literature, 0.9%. So the antegrade dissection technique has not confirmed the fear of the residual choledocholithiasis.

Conclusion

The conversion is the best choice when the dissection of triangle of Calot becomes too difficult, because of the higher risk of vascular or biliary lesions^{11,12}.

The GAD procedure has been widely accepted and performed until now only when it is difficult to dissect Calot's triangle because of the presence of inflammation, portal hypertension or fibrosis. So GAD for laparoscopic cholecystectomy represents an easier procedure that seems to reduce the operative time. So it may be proposed as a standard procedure and not only suited for difficult cholecystectomies.

References

1. Zha Y, Chen XR, Luo D, Jin Y: *The prevention of major bile duct injuries in laparoscopic cholecystectomy: The Diagnostic and experience with 13,000 patients in a single center.* Surg Laparosc Endosc Percutan Tech, 2010; 20:378-83. PMID:21150413.
2. Neri V, Ambrosi A, Fersini A, Tartaglia N, Lapolla F, Forlano I: *Severe acute pancreatitis Clinical forms of different gravity.* Ann Ital Chir, 2013; 84:47-53, ISSN: 0003-469X
3. Neri V, Ambrosi A, Fersini A, Tartaglia N, Lapolla F: *Common bile duct lithiasis: Therapeutic approach..* Ann Ital Chir, 2013; 84:405-10. ISSN: 0003-469X
4. Aygen E, Dogru O, Baktyr HA, Basbug M: *Yanlys drenaj nedeniyile kapanmayan safra fistulu: Olgu sunumu.* Firat University Journal of Health Sciences (Medicine), 2008; 22(2):101-04.
5. Ahrendt SA, Pitt HA, Biliary Tract., In: Townsend CM, Beauchamp RD, Evers BM, Mattox KL: *Sabiston Text-book of Surgery 17th edition.* Pennsylvania: Saunders. 2004; 1609-615.
6. Tayeb M, Raza SA, Khan MR, Azami R: *Conversion from laparoscopic to open cholecystectomy: Multivariate analysis of preoperative risk factors.* J Postgrad Med, 2005; 51(1):17-20.
7. Ota A, Kano N, Kusanagi H, Yamada S, Garg A: *Techniques for difficult cases of laparoscopic cholecystectomy.* J Hepatobiliary Pancreat Surg, 2003; 10:172-75.
8. Mahmud S, Masaud M, Canna K, Nassar AH: *Fundus-first laparoscopic cholecystectomy.* Surg Endosc, 2002; 16:581-84.
9. Kato K, Kasai S, Matsuda M, et al.: *A new technique for laparoscopic cholecystectomy. Retrograde laparoscopic cholecystectomy: An analysis of 81 cases.* Endoscopy, 1996; 28:356-59.
10. Forlano L, Fersini A, Tartaglia N, Ambrosi A, Neri V: *Biliary papillomatosis: Case report.* Ann Ital Chir, 2011; 82:405-408, ISSN: 0003-469X.
11. Kelly MD: *Laparoscopic retrograde (fundus first) cholecystectomy.* BMC Surgery, 2009, 9:19.
12. Neri V, Ambrosi A, Fersini A, Tartaglia N, Cianci P, Lapolla F, Forlano I: *Laparoscopic cholecystectomy: Evaluation of liver function tests.* Ann Ital Chir, 2014; 85:431-37, ISSN: 0003-469X.