

Rosuvastatin administered intraperitoneally reduces the formation of postoperative adhesions in rats



Ann Ital Chir, 2018 89, 1: 95-100
pii: S0003469X18027586
Epub Ahead of Print - September 26
free reading: www.annitalchir.com

Ștefan Chiorescu, Nicolae Ovidiu Grad, Ion Aurel Mironiuc, Octavian Aurel Andercou

"Iuliu Hatieganu" University of Medicine and Pharmacy, Surgery Clinic n. 2, Cluj-Napoca, Romania

Rosuvastatin administered intraperitoneally reduces the formation of postoperative adhesions in rats

OBJECTIVES: *The purpose of the present experimental research was to assess the efficacy of intraperitoneal administration of rosuvastatin in preventing the formation of postoperative peritoneal adhesions.*

MATERIAL AND METHOD: *Peritoneal adhesions were induced in 120 male rats of the Wistar-Bratislava breed, divided into 4 groups (n=30), using a parietal and visceral abrasion model. Group I was designated as the control group; in the case of group II, a saline solution was administered intraperitoneally, while in the case of groups III and IV, rosuvastatin solution with a concentration of 10 mg/kg and 5 mg/kg, respectively, was administered in a single dose, during laparotomy. All rats were sacrificed on the 14th postoperative day and the peritoneal adhesions were assessed macroscopically and microscopically.*

RESULTS: *The formation of peritoneal adhesions (assessed macroscopically by appreciating their number, the area covered, and the degree of severity) was statistically significantly more reduced in the subjects that received rosuvastatin (groups III and IV) as compared to the control group (p<0.05). The degree of fibrosis assessed microscopically was also statistically significantly reduced in groups III and IV as compared to the control group (p<0.05).*

CONCLUSIONS: *Rosuvastatin administered intraperitoneally correlates with a reduction of peritoneal adhesions in rats.*

KEY WORDS: Rosuvastatin, Peritoneal adhesions, Prevention

Introduction

Postoperative peritoneal adhesions are one of the most frequent complications in abdominal surgery. The incidence of this pathology, as reported in various studies, is as high as 90-95% in the case of patients who underwent laparotomy and even 97% after pelvic gynecological surgery ¹.

This condition is not always symptomatic, but in some cases these adhesions are a major cause of morbidity and

mortality, and their presence may result in multiple complications, many of which occur years after the initial surgical intervention ².

Despite the fact that the development of peritoneal adhesions has been and continues to be studied extensively and despite the data obtained, the exact mechanism by which they are formed and the means of prevention or the therapeutic means remain as yet incompletely elucidated. The suppression of inflammation, the manipulation of coagulation mechanism, and the increase in fibrinolytic activity may represent promising treatment strategies ³.

Statins (HMG-CoA reductase inhibitors) are a class of drugs used in the treatment of hyperlipidemia (through the inhibition of HMG-CoA reductase, an enzyme that plays a central role in the synthesis of cholesterol) and for the prevention of cardiovascular diseases. Besides the hypolipidemic effect, a series of biological effects were observed, such as an antifibrotic effect, an anti-inflam-

Pervenuto in Redazione Luglio 2017. Accettato per la pubblicazione Settembre 2017:

Correspondence to: Ștefan Chiorescu, 68 București Street, Cluj-Napoca, 400148, Romania (e-mail: stefanc74@yahoo.com)

matory effect, and the modulation of fibrinolysis, whose role, highlighted in a series of experimental studies, is to reduce the formation of peritoneal adhesions⁴⁻¹⁰. Rosuvastatin is one of the relatively new members of HMG-CoA reductase inhibitors and is considered to be one of the most efficient statins^{11,12}. In the literature, the effect of preventing the formation of postoperative peritoneal adhesions has not been studied in the case of rosuvastatin.

The object of this study is to assess the efficiency of intraperitoneal administration of rosuvastatin in preventing of the formation of postoperative adhesions, using an experimental rat model.

Material and method

White male rats of the Wistar-Bratislava breed were used, provided by the Center for Practical Skills and Experimental Medicine of the Iuliu Hațieganu University of Medicine and Pharmacy, Cluj-Napoca, weighing 200 ± 20 g each. The animals were kept in individual cages, at a constant room temperature, and received standard food. In the 12 hours leading up to the experiment, they received nothing but water.

The experimental protocol was approved by the Ethics Commission of the Iuliu Hațieganu University of Medicine and Pharmacy, Cluj-Napoca. Anesthesia was achieved by intramuscular injection of 60 mg/kg ketamine and 6 mg/kg xylazine. All animals breathed spontaneously throughout the entire procedure. The surgical procedures were conducted under aseptic conditions.

A number of 120 rats were used, which were randomly divided into 4 equal groups (n=30), and in whose case a model for the induction of peritoneal adhesions through the abrasion of the parietal and visceral peritoneum was applied. After a median laparotomy of approximately 3-4 cm, the cecum was exteriorized to the

wound surface. Peritoneal adhesions were induced by abrasion of the parietal and visceral peritoneum at the level of the cecum by means of a Cytobrush – a spiral-type brush for endocervical sampling. Abrasion was performed on a 2.0x2.0 cm area until punctiform bleeding occurred, as a witness to peritoneal trauma. 20 ± 3 abrasions were required (Fig 1). Group I (n=30) was designated as the control group; in the case of group II (n=30), a 1 ml saline solution was administered intraperitoneally before the closure of the abdominal wall (the control group), and in the case of groups III and IV (n=30), a therapeutic procedure was initiated through the intraperitoneal injection of rosuvastatin solution, in different concentrations. In the case of group III, 2 mg rosuvastatin calcium/1 ml (10 mg/kg), in a single dose, was administered, and in the case of group IV, 1 mg rosuvastatin calcium/1ml (5 mg/kg), single dose, was administered, followed by the closure of the abdominal wall. The surgical interventions were limited to less than 20 minutes for each rat and all of the operations were performed by the same surgeon, using surgical gloves without powder.

Rosuvastatin, in the shape of calcium salt, was obtained courtesy of Antibiotice S.A. Iași joint-stock company, and the solutions were prepared at the Pharmacy Department of the Iuliu Hațieganu University of Medicine and Pharmacy, Cluj-Napoca.

On the first day postoperatively, all animals were administered nothing but water, whereas over the days that followed, they were provided with standard food and water. The animals were subsequently observed twice daily for signs of wound infection, dehiscences, or other complications. There were no cases of exclusion from the study.

14 days postoperatively, all of the subjects underwent laparotomy with a view to assessing the formation of peritoneal adhesions. For this purpose, the animals were sacrificed using CO₂.

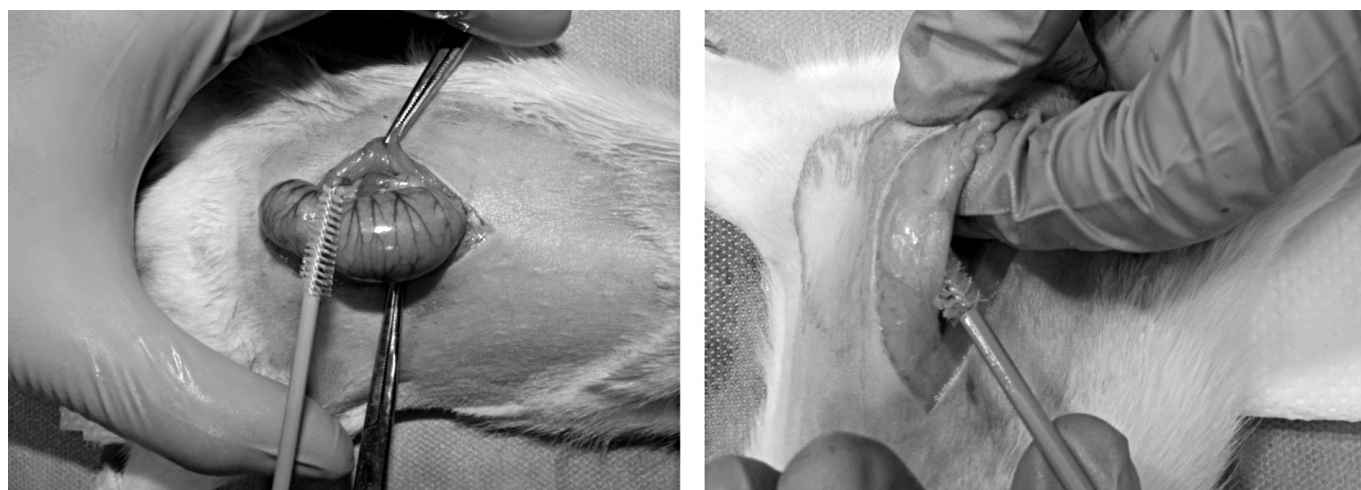


Fig. 1: Experimental model for abrasion of the visceral (cecal) and parietal peritoneum.

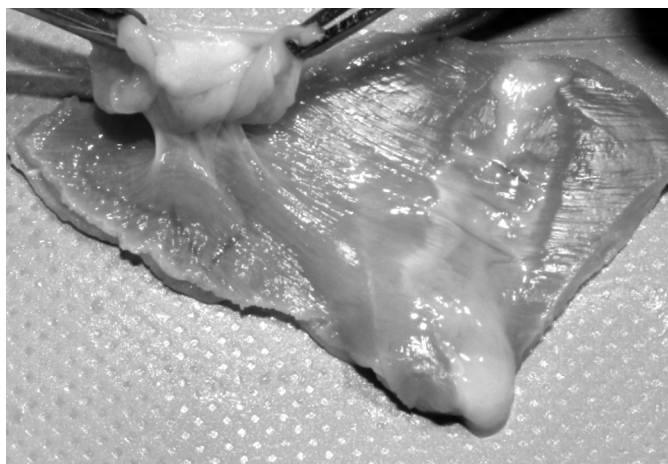


Fig. 2: The abdominal wall/intestinal wall caught in adhesions was excised en bloc.

The assessment of the formation of peritoneal adhesions was conducted from a macroscopic and microscopic point of view. The adhesions were assessed macroscopically at the moment of laparotomy and were immediately documented by means of photography. The abdominal wall / intestinal wall caught in adhesions was excised en bloc for subsequent histological processing (Fig. 2).

The quantity, quality, and macroscopic appearance of the formed adhesions were also observed and quantified. *Quantity* was quantified based on the incidence of adhesion formation at the spot of the trauma and as the extent (percentage) to which the traumatized area was covered by adhesions. The *Quality* of the induced adhesions was determined based on the severity score according to the method of Evans et al. ¹³ (Table I).

TABLE I - The macroscopic degree of severity of peritoneal adhesions.

Degree	Peritoneal adhesions Definition of the macroscopic degree of severity
0	Absence of adhesions
1	Fine, avascular, easily separable adhesions
2	Adhesions separable through traction, with limited vascularization
3	Adhesions separable through dissection, with rich vascularization

TABLE II - The histopathological degree of severity for peritoneal adhesions

Degree	Peritoneal adhesions Definition of the microscopic degree of severity
0	Absence of fibrosis/inflammation
1	Mild fibrosis/inflammation
2	Moderate fibrosis/inflammation
3	Severe fibrosis/inflammation

All samples were assessed histologically. After fixation in formalin (4%), they were embedded in paraffin blocks and sections of 4-5 μm thickness were stained with hematoxylin and eosin (H-E). The assessment of the fibrosis and inflammation score was done according to Hooker ¹⁴ (Table II).

Statistical analysis

The collected data was expressed as mean \pm standard deviation (M \pm SD). In order to assess the differences between groups, a single analysis of variance (ANOVA) was used. A $p < 0.05$ was considered statistically significant.

Results

MACROSCOPIC ASSESSMENT

In the control group (n=30), adhesions occurred in 25 rats (83.33%), of which 4 were of the first degree (13.33%), 6 of the second degree (20%), and 15 of the third degree (50%).

In the case of group II (n=30), where a saline solution was administered intraperitoneally, adhesions were obtained in 24 rats (80%), of which 6 were of the first degree (20%), 4 of the second degree (13.33%), and 14 of the third degree (46.66%). In the case of group III (n=30), where rosuvastatin with a concentration of 10 mg/kg was administered intraperitoneally, adhesions were induced in 16 rats (53.33%), of which 9 were of the first degree (30%), 3 of the second degree (6.66%), and 4 of the third degree (13.33%), and in the case of group IV (n=30), where rosuvastatin with a concentration of 5 mg/kg was administered intraperitoneally, adhesions developed in 15 rats (50%), of which 8 were of the first degree (26.66%), 2 of the second degree (6.66%), and 5 of the third degree (16.66%) (Table III) (Figs. 3, 4). The extent (percentage) to which the traumatized area was covered with adhesions was 51.6% for the control group, 50% for the saline solution group, and 26.66% and 27.5%, respectively, for the groups where rosuvastatin was administered intraperitoneally, with a concentration of 10 mg/kg and 5 mg/kg, respectively.

TABLE III - The macroscopic degree of severity and mean score by group

Groups	Macroscopic degree of severity				M \pm SD
	0 Degree	1 st Degree	2 nd Degree	3 rd Degree	
I	5	4	6	15	2.03 \pm 0.67
II	6	6	4	14	1.86 \pm 0.74
III	14	9	3	4	0.9 \pm 0.56
IV	15	8	2	5	0.9 \pm 0.63

Legend: M – mean SD – standard deviation. I versus II: $p = 0.59$; I versus III: $p = 0.0002151$; I versus IV: $p = 0.00030397$.

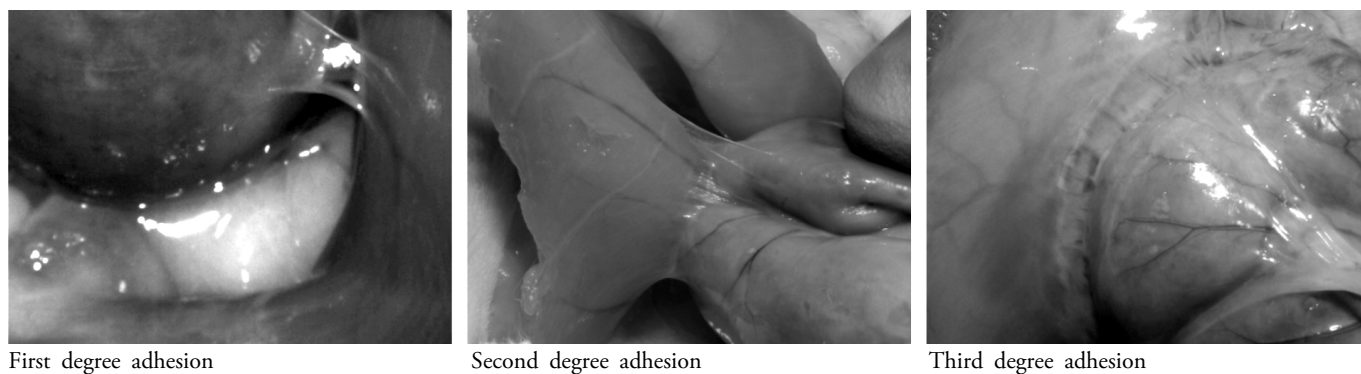


Fig. 3: Macroscopic appearance of peritoneal adhesions.

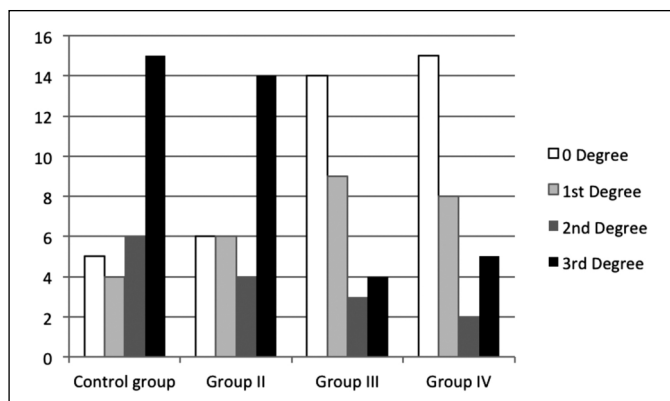


Fig. 4: The macroscopic degree of adhesions for the four groups.

TABLE IV - The microscopic degree of severity and mean score by group

Groups	Microscopic degree of severity				M ± SD
	0 Degree	1 st Degree	2 nd Degree	3 rd Degree	
I	5	3	11	11	1.93±0.58
II	6	6	8	10	1.73±0.65
III	17	7	3	3	0.73±0.51
IV	15	6	5	4	0.93±0.61

M – mean SD – standard deviation. Legend: I versus II: p=0.48; I versus III: p=4.18412E-05; I versus IV: p=0.000815876.

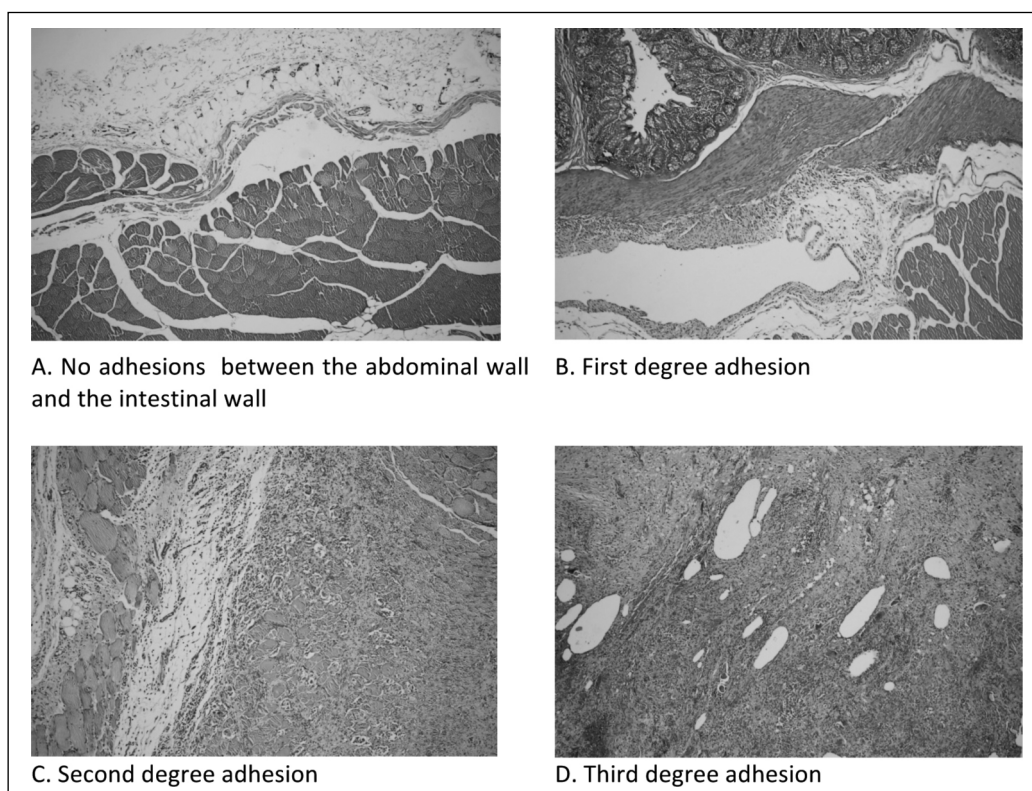


Fig. 5: The microscopic degree of severity for peritoneal adhesions. Hematoxylin-Eosin staining, objective (10x), magnification 100 times

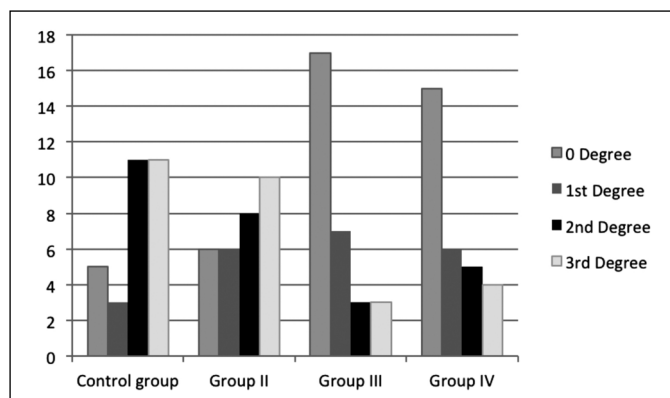


Fig. 6: The microscopic degree of severity of adhesions for the four groups.

MICROSCOPIC ASSESSMENT

In the control group (n=30), mild (1st degree) fibrosis and inflammation was described in 3 rats (10%), moderate (2nd degree) fibrosis and inflammation – in 11 rats (36.66%), and severe (3rd degree) fibrosis and inflammation – in 11 rats (36.66%).

In group II (n=30), 6 rats (20%) showed mild fibrosis and inflammation, 8 (26.66%) – moderate fibrosis and inflammation, and 10 rats (33.33%) – severe fibrosis and inflammation. In groups III and IV (n=30), 6 rats (20%) and 7 rats (23.33%), respectively, showed mild fibrosis and inflammation. 3 rats (10%) and 5 rats (16.66%), respectively, were included in the second degree, and severe fibrosis and inflammation occurred in 3 (10%) and 4 rats (13.33%), respectively (Table IV) (Figs. 5, 6)

Discussions

Postoperative peritoneal adhesions are a major cause of morbidity – abdominal and pelvic pain, infertility, and intestinal obstruction.

Different experimental models were used to induce postoperative adhesions (parietal and visceral peritoneum abrasion, mechanical denudation and suture, ischemic buttons, electrocoagulation, electrocoagulation and suture) ¹⁵. The surgical maneuvers during laparotomy produce mechanical trauma, which are the most frequent cause for postoperative adhesions. We used an experimental model for abrasion of the visceral (cecal) and parietal peritoneum because it replicates the mechanical trauma during a laparotomy, it offers good results from a qualitative and quantitative point of view, and can be easily replicated ¹⁶.

The search for certain efficient methods for preventing the formation of postoperative adhesions has been going on for decades. The strategies used may be grouped into 4 categories – general principles, elements pertaining to

surgical technique, mechanical barriers, and pharmacological agents ¹⁷. Some of these measures have proven to be effective in reducing the number and quality of adhesions in studies on animal models or in clinical studies, but none of them is universally effective, and their mode of action is but little understood.

The peritoneal wounds induced by the surgical procedures or by other factors initially produce an inflammatory response. Procoagulant and antifibrinolytic reactions are produced, with a significant increase in fibrin formation. When these fibrin deposits persist, fibrinous adhesions develop. Subsequently, these organize themselves through collagen deposits and the occurrence of newly-formed vessels, and become permanent.

The strategies for the prevention of the formation of adhesions may include the suppression of inflammation, the manipulation of coagulation, and an increase in the fibrinolytic activity.

The use of statins may represent a treatment option, because they potentially combine the anti-inflammatory effect, the anticoagulant effect, and profibrinolytic properties. Statins, being inhibitors of HMG-CoA reductase, which is an enzyme that plays a key role in cholesterol synthesis, are used on a large scale in the treatment of hyperlipidemia and in the primary and secondary prevention of cardiovascular diseases. According to the literature, statins exert pleiotropic effects independent of the decrease in cholesterol and a significant proportion of these effects are due to the anti-inflammatory effects ⁴. Antifibrotic, antioxidant, and profibrinolytic effects have also been described. It has been demonstrated that rosuvastatin (a relatively new, highly-effective and long-acting statin) ^{11,12} prevents epidural fibrosis following neurosurgical interventions and reduces fibrosis in a rat model of cyclosporine-induced nephropathy ^{5,18,19}, prevents the development of knee intra-articular adhesions, again in an experimental rat model ²⁰, increases the anti-inflammatory activity, and inhibits proinflammatory functions in cultured microglial cells ²¹.

Also, a series of experimental studies involving statin representatives (lovastatin, simvastatin, atorvastatin) proved the efficiency of statins in reducing the formation of peritoneal adhesions ⁶⁻¹⁰.

We have conducted the present research based on this data; that is to say, we have investigated the effect of intraperitoneally-administered rosuvastatin, in a single dose, at the conclusion of the surgical intervention, of preventing the formation of postoperative peritoneal adhesions.

There were no significant differences in terms of the induced adhesions between the control group and the group in whose case a saline solution was administered intraperitoneally, from the point of view of either the macroscopic (p=0.59) or microscopic assessment (p=0.48).

Intraperitoneal administration of rosuvastatin solution is correlated with a reduction in the formation of perito-

neal adhesions. This observation is valid in the case of both groups, in which the number, the area covered, and the degree of the adhesions decreased on macroscopic examination, as did the degree of fibrosis/inflammation on microscopic examination. There is a statistically significant difference between the control group and group III, with a rosuvastatin concentration of 10 mg/kg, and between the control group and group IV, with a rosuvastatin concentration of 5 mg/kg. There were no statistically significant differences between groups III and IV.

In the course of the study there were no side effects or complications associated with the administration of rosuvastatin.

Conclusions

The experimental model for inducing peritoneal adhesions in rats through the abrasion of the parietal and visceral (cecal) peritoneum may be standardized.

Intraperitoneal administration of rosuvastatin correlates with a reduction of peritoneal adhesions in rats and the literature data supports this correlation, but only in the case of the administration of other statins.

Intraperitoneal administration of rosuvastatin is a reliable and efficient method for reducing the formation of peritoneal adhesions in rats.

New experimental studies are needed to identify the mechanisms by which this effect of reducing the formation of peritoneal adhesions is achieved, as well as the optimal therapeutic dose, experimental studies that future clinical trials should rely on.

References

1. Becker JM, Stucchi AF: *Intraabdominal adhesions prevention: are we getting any closer?* Ann Surg, 2004; 240:202-204.
2. Ruggiero R, Gubitosi A, Docimo G, Gili S, Tolone S, Bosco A, Casalino G, Docimo L: *Hyaluronic acid and adhesions on polypropylene endoperitoneal mesh. An experimental study.* Ann Ital Chir, 2013; 84:87-92.
3. Hellebrekers BWJ, Kooistra T: *Pathogenesis of postoperative adhesion formation.* British Journal of Surgery, 2011; 98:1503-516.
4. Bu De-xiu, Griffin G, Lihtman AH: *Mechanism for the anti-inflammatory effects of statins.* Current Opinion in Lipidology, 2011; 22:165-17.
5. Gurer B et al.: *Evaluation of topical application and systemic administration of rosuvastatin in preventing epidural fibrosis in rats.* The Spine Journal, 2015; 15:522-29.
6. Lalountas MA, Ballas KD, Skouras C: *Preventing intraperitoneal adhesions with atorvastatin and sodium hyaluronate/carboxymethylcellulose: A comparative study in rats.* Am J Surg, 2010; 200(1):118-23.
7. Kukuk HF, Kaptanoglu L, Kurt N, Uzun H, Eser M, Bingul S, Torlak OA, Akyol H: *The role of simvastatin on postoperative peritoneal adhesion formation in an animal model.* Eur Surg Res, 2007; 39(2):98-102.
8. Aarons CB, Cohen PA, Gower A, Reed KL, Leeman SE, Stucchi AF, Becker JM: *Statins (HMG-CoA reductase inhibitors) decrease postoperative adhesions by increasing peritoneal fibrinolytic activity.* Ann Surg, 2007; 245(2):176-84.
9. Lalountas M, Ballas KD, Michalakis A, Psarras K, Asteriou C: *Postoperative adhesion prevention using a statin-containing cellulose film in an experimental model.* Br J Surg, 2012; 99(3):423-29.
10. Arslan E, Talih T, Oz B, Halaclar B, Gaglayan K: *Comparison of lovastatin and hyaluronic acid/carboxymethyl cellulose on experimental created peritoneal adhesion model in rats.* International Journal of Surgery, 2014; 12:120-24.
11. McTaggart F, Buckett L, Davidson R, Holdgate G, McCormick A, Schneck D, et al.: *Preclinical and clinical pharmacology of Rosuvastatin, a new 3-hydroxy-3-methylglutaryl coenzyme A reductase inhibitor.* Am J Cardiol, 2001; 87:28B-32B.
12. McKenney JM, Jones PH, Adamczyk MA, Cain VA, Bryzinski BS, Biasetto JW, et al.: *Comparison of the efficacy of rosuvastatin versus atorvastatin, simvastatin and pravastatin in achieving lipid goals: results from STELLAR trial.* Curr Med Res Opin, 2003; 19:689-98.
13. Evans DM, McAree K, Guyton DP, Hawkins N, Stakleff K: *Dose dependency and wound aspects of the use of tissue plasminogen activator in the prevention of intraabdominal adhesions.* American Journal of Surgery, 1993; 165-2:229-32.
14. Hooker GD, Taylor BM, Driman DK: *Prevention of adhesion formation with use of sodium hyaluronate-based bioresorbable membrane in a rat model of ventral hernia repair with polypropylene mesh. A randomized, controlled study.* Surgery, 1999; 125, 211-16.
15. Ozel H, Avsar FM, Topaloglu S, Sahin M: *Induction and assessment methods used in experimental adhesion studies.* Wound Repair and Regeneration, 2005; 13(4):358-64.
16. Kraemer B, Wallwiener C, Rajab TK, Brochhausen C, Wallwiener M, Rothmund R: *Standardised models for inducing experimental peritoneal adhesions in female rats.* Biomed Research International, 2013; 435-56.
17. Schnuriger B, Barmparas G, Branco BC, Lustenberger T, Inaba K, Demetriades D: *Prevention of postoperative peritoneal adhesions: A review of the literature.* Am J Surg, 2011; 201:111-21.
18. Nam HK, Lee SJ, Kim MH, et al.: *Rosuvastatin attenuates inflammation, apoptosis and fibrosis in a rat model of cyclosporine-induced nephropathy.* Am J Nephrol, 2013; 37(1):7-15.
19. Zhang C, Feng S, Hu N, et al.: *Letter to the editor regarding: "Evaluation of topical application and systemic administration of rosuvastatin in preventing epidural fibrosis in rats" by Bora Güreer et al.* Spine J, 2015; 15(5):1165-66.
20. Wu H, Germanov AV, Goryaeva GL, Yachmenev AN, Gordienko DI, Kuzin VV, Skoroglyadov AV: *The topical application of rosuvastatin in preventing knee intra-articular adhesion in rats.* Med Sci Monit, 2016; 22:1403-409.
21. Kata D, Földesi I, Feher LZ, et al.: *Rosuvastatin enhances anti-inflammatory and inhibits pro-inflammatory functions in cultured microglial cells.* Neuroscience, 2016; 314:47-63.