

Primary acquired Grynfeltt Hernia: two new cases and literature review



Ann Ital Chir, 2018 89, 3: 255-260

pii: S0003469X1802746X

Epub Ahead of Print 5 March 2018

free reading: www.annitalchir.com

Lorenzo Capasso, Gaetano Romano, Antonio Alderisio, Giuseppe Loiacò, Giuseppe Rocco, Salvatore Massa, Ferdinando Salzano de Luna

Department of Surgical Oncology, Director: F. Salzano de Luna, "S. Anna e S. Sebastiano", Hospital of Caserta, Italy

Primary acquired Grynfeltt Hernia: two new cases and literature review.

AIM: We report two cases of the very rare Primary Acquired Grynfeltt Hernia. The related abdominal wall defects were repaired, by open surgery, placing a partially absorbable plug and mesh. The observation and management of these two new cases prompted us to review the literature with the purpose of suggesting the most appropriate surgical approach and technique.

MATERIAL OF STUDY: A 60 years old female patient showing a swelling at the left lumbar region, and a 76 years old male patient showing evidence of a tumefaction located at the right lumbar region, were diagnosed at our department with Primary Acquired Grynfeltt Hernia.

RESULTS: Postoperative courses were uneventful and the patients were discharged from hospital respectively on the third and second postoperative day. Follow-up at thirty days, six months, two and three years showed no signs of recurrence.

DISCUSSION: Primary Acquired Grynfeltt Hernia is one of the rarest abdominal hernias. In literature there are no comparative studies showing which type of surgical approach should be preferred for this specific abdominal wall defect. In our department, open surgery was successfully performed for the treatment of two new cases of Primary Acquired Grynfeltt Hernias and, second time in literature, partially absorbable plug and mesh were placed in order to repair the causative abdominal wall defect.

CONCLUSION: Based on our experience and literature review, we consider open hernia repair with partially absorbable plug and mesh as an appropriate and advisable surgical approach for not complicated cases of Primary Acquired Grynfeltt Hernia. Surgery is performed rapidly, effortlessly and securely if the patient is under general anesthesia, in lateral decubitus position with the operating table flexed at the level of the iliac crest.

KEY WORDS: Primary Acquired Grynfeltt Hernia, Lumbar Hernia.

Introduction

Among all the abdominal hernias, the Grynfeltt hernia is one of the rarest (2%). Only about 20% of cases are congenital while the majority is represented by acquired cases. Almost 55% of the acquired ones are either spontaneous or primary and the remaining are secondary. More than three thousand years passed since the peritoneal her-

nia was first mentioned in the Ebers Papyrus in 1552 B.C. and only in 1672 Barbett suggested the existence of a lumbar hernia. Later in 1866, Grynfeltt described the anatomical space and the hernia named after him.

Nowadays, by looking up "primary Grynfeltt hernia" on PubMed, 5 works can be found; 222 works on "Grynfeltt hernia"; 1111 works on "primary inguinal hernia" and 14306 on "inguinal hernia".

The manifestation of only two cases of PAGH during our experience (2 out of 1605, the equivalent of 0,12% of primary abdominal hernias operated in our department in 5 years) gave rise to the need for reflection on its diagnosis and therapy, also in light of recent international literature on this issue.

Pervenuto in Redazione Giugno 2017. Accettato per la pubblicazione Ottobre 2017

Correspondence to: Dr. Lorenzo Capasso, 11 tr F.A. Giordano 11, 80027 Frattamaggiore (Na) (e-mail: lorenzo.capasso@inwind.it)

Material and Methods

At “S. Anna and S. Sebastiano” – Hospital of Caserta, laparoscopy is widely employed for cholecystectomies, treatment of incisional hernias, for colic and gastric resections, nephrectomies and adrenalectomies; on the other hand, it is not generally preferred for the treatment of primitive abdominal hernias. Over a 5 years’ period, specifically from 2008 to 2013, 1605 patients underwent surgery, in our institution, for primitive abdominal hernias (inguinal, femoral, umbilical, epigastric, Spigelian, of Grynfeltt), all treated by open surgery, because this approach is considered to be burdened with fewer complications, better patient outcomes and lower costs. Approximately 90% of patients (1444 patients) were operated under local anesthesia, sometimes with sedation and eventually discharged 6 hours after surgery. 9% of them (145 patients who took dual antiplatelet therapy or who had various important systematic pathologies) were discharged as planned 24 hours after the operation, whereas for 1% of them (16 patients with severe associated pathologies) from 2 to 9 hospitalization days were required.

Clinical Cases

CASE REPORT N. 1

Female patient, 60 years old; past medical history: constipation, allergies, exertional dyspnea, hypertension, dyslipidemia, breast fibroadenectomy; recent medical history: orange-sized swelling, intermittently painful, located at left lumbar region, which increases in size during Valsalva maneuver; because of the unusual localization of the tumefaction, and in order to differentiate Grynfeltt hernia from subcutaneous lipoma, the patient underwent an abdominal ultrasound and CT scan. Both confirmed the presence of a hernial sac in the left superior lumbar triangle. In particular, the computed tomography (Figs. 1, 2, 3) showed at the left lumbar region, a subfascial hypodense oval formation (63 x 26 mm) directly connected to the abdominal cavity, referable to an omental hernia of the abdominal wall with a sac neck of about 20 mm.

Before being hospitalized, the patient underwent allergy consultancy and was advised to take the following pharmacological prophylaxis 3 days before surgery: betamethasone 4 mg/ml injections (13 hours, 7 hours and 1 hour before surgery); ranitidine capsules 150 mg, one capsule every 12 hours for 3 days; ebastin capsules 10 mg, 1 capsule every 12 hours for 3 days. Also, the patient required a methacholine test which highlighted slight hyperreactivity whereas the spirometry tests were normal. Classified as ASA II/III, the patient was hospitalized on the day of surgery. The surgical procedure was performed under general anesthesia, with the patient put

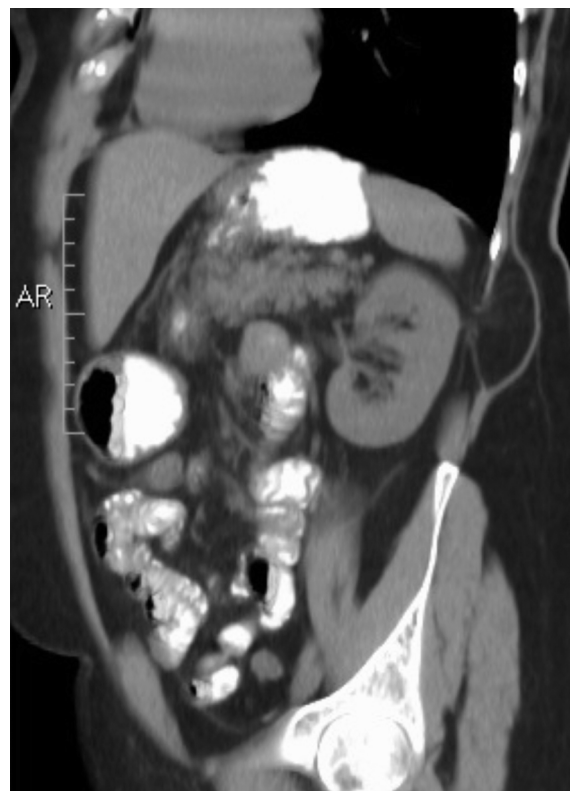

Fig. 1: CT scan: sagittal view showing a subfascial oval hypodense formation, directly connected to the abdominal cavity.

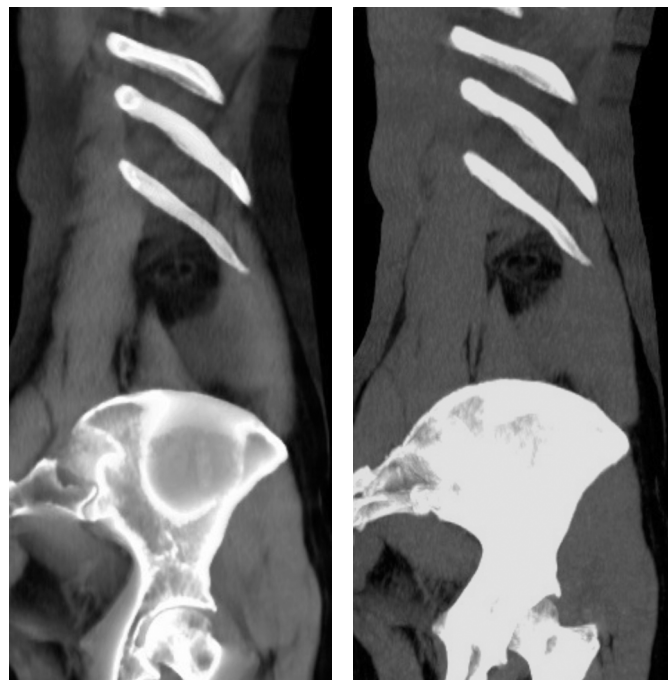


Fig. 2: CT scan: sagittal views showing the presence of the hernia below the twelfth left rib.

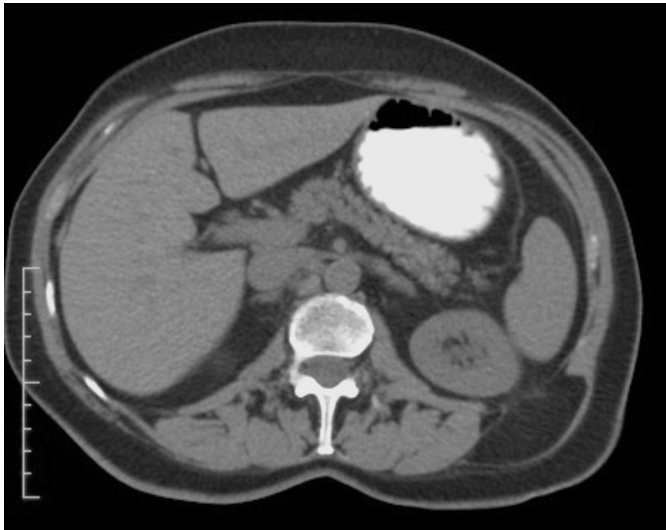


Fig. 3: Computed axial tomography showing the protrusion of the Grynfeldt hernia at the left superior lumbar triangle.

in lateral decubitus position on the operating table. The table was flexed at level of the iliac crest in order to increase the space between the iliac crest and the last rib. The surgical intervention, lasting 35 minutes, was conducted via the anterior approach, with a 5 cm incision parallel to the inferior edge of the twelfth rib, along the major axis of the swelling; once the fibres of the latissimus dorsi muscle retracted, the hernial sac was isolated in the upper lumbar triangle (also known as Grynfeldt – Lesshaft triangle), delimited superiorly by the lower edge of the twelfth rib, laterally by the internal oblique muscle and medially by the quadratus lumborum muscle. After smooth hernia reduction, a partially absorbable (Ultrapro®) plug was positioned in the wall defect of 2 cm diameter in the transversalis fascia. Subsequently, the plug was anchored to the inner layer of the transversalis fascia with two stitches at the opposite edges. Then, the transversalis fascia was sutured over the plug. On top of the transversalis fascia, a partially absorbable (Ultrapro®) mesh was positioned and afterwards fixed with a synthetic glue. Eventually, the latissimus dorsi muscle was sutured above the mesh. Surgical wound was closed in layers. Postoperative course was uneventful. Patient was discharged on the third postoperative day. Follow-up at thirty days, six months, two and three years showed no signs of recurrence.

CASE REPORT N. 2

Male patient, 76 years old; past medical history: cerebrovascular disease, chronic subdural hematoma, HCV-related chronic hepatitis, left carotid endarterectomy,

bilateral total hip arthroplasty, left inguinal and epigastric hernioplasty; pharmacological anamnesis: antiplatelet therapy and phenobarbital; recent medical history: clinical evidence of a tumefaction at the right lumbar region, reducible with appropriate manouvers. The swelling was studied with ultrasound and CT scan. Classified as ASA III, the patient was operated with the same approach, technique and materials as for the former case (duration of the procedure: 50 minutes). The patient was discharged on the second postoperative day. Follow-up at thirty days, six months, two and three years showed no signs of recurrence.

Discussion

ANATOMY

The Grynfeldt space, either triangular or quadrangular, is delimited superiorly and laterally by the twelfth rib, superiorly and medially by the serratus posterior inferior muscle; medially by the spinal muscles on surface and by the quadratus lumborum muscle at the bottom; laterally and inferiorly by the edge of the internal oblique muscle. The floor of the Grynfeldt space is represented by the transversalis fascia which is strengthened on the surface by the latissimus dorsi muscle. The Grynfeldt space was first described in 1866¹ and successively by Lesshaft in 1870. Before 1866, Petit described the inferior lumbar triangle, medially delimited by the latissimus dorsi muscle, laterally by the external oblique muscle and inferiorly by the iliac crest, with its floor represented by the internal oblique muscle. An in-depth study by Loukas et al.² on 50 corpses of adult men enabled the distinction of 4 types of Grynfeldt triangle. Type I (50% of cases) with an area less than 5 cm², Type II (22% of cases) with an area ranging from 5 to 15 cm², and type III (10% of cases) with an area larger than 15 cm² and type 0 (18% of cases) in which no triangle is present.

ETIOLOGY

Grynfeldt hernias, caused by a breach in the transversalis fascia at the Grynfeldt triangle, can be congenital (20% of cases) (for example, due to embryogenetic defects such as vertebral and rib abnormalities) or acquired (80% of cases). Among the latter, 55% can be primitive and 25% secondary. The cause of primitive hernias seems to be a parietal predisposition (influenced by age, obesity, muscular atrophy, excessive weight loss and chronic debilitating illnesses) which comes to light after violent strains or bouts of cough. Direct or indirect trauma has been described as the causative factor in many adult patients³. The causes of secondary lumbar hernias are lumbotomic operations, deep wounds and infections.

CLINICAL FINDINGS

Accurate and scrupulous clinical examination is still a fundamental step in the diagnostic process for the Grynfeltt hernia⁵. In absence of complications, the clinical presentation of the Grynfeltt hernia is a swelling which increases with cough, sometimes associated with non-specific abdominal symptoms, low back pain, and urinary symptoms. The differential diagnosis frequently includes lipomas, abscesses, kidney tumours and rarely sarcomas. The hernial sac can contain omentum, small intestine, colon and kidney and in one case a haematoma, caused by chronic fissuration of a thoracoabdominal aortic aneurysm⁴, was described. Intestinal obstruction manifests in 25% of cases, and in 10% strangulation can occur.

DIAGNOSTICS

An ultrasound scan is the first exam to confirm clinical suspects. Successively, CT or MRI are helpfully employed to better assess the muscular wall, the anatomical relationships, the size of the hernia and its contents⁶. In some cases, it can be difficult to differentiate muscular atrophy from the defect of the transversalis fascia which causes the hernia⁷. At times, evidence of a case of Grynfeltt hernia is only clear during surgery⁸, since the Grynfeltt hernia is often confused with subcutaneous lipoma.

TREATMENT

Hernia repair techniques include direct suture for minor defects, musculoaponeurotic rotation flaps using the gluteus maximus and gluteus medius muscles, tensor fascia lata rotational flaps and free fascial grafts.

Nowadays, the use of prosthetic materials and the advent of laparoscopic technique have made the previous techniques obsolete, albeit still no specific method can be recommended as the preferable.

There are no comparative studies on open surgery versus laparoscopy for primitive lumbar hernias. Instead, for secondary lumbar hernias a non-random prospective study on 16 patients demonstrated an advantage for the laparoscopic treatment because of shorter operating times, minor postoperative complications, faster hospitalization, lower assumption of analgesics and an earlier resumption of daily life activities⁹.

Cavallaro et al.¹⁰, in his series of nine primitive lumbar hernias, all operated laparotomically, positioning a synthetic mesh in the extraperitoneal space, underneath the muscular layers, reports that there were no complications for patients (except for a subcutaneous haematoma), mean hospital stay of 2.3 days, resumption of normal activities within 15 days after surgery and

absence of recurrence after 25 months, concluding that the anterior approach is easy, safe and efficient. The same author in a later work¹¹ confirms the preference for this approach (under local anesthesia) for small hernias, and suggests that laparoscopy should be preferred for larger hernias or in case of suspected of visceral strangulation. As for the more common inguinal hernia, other indication for the laparoscopic approach is the recurrent hernia¹².

Trans-abdominal laparoscopic approach requires general anesthesia, which should be preferred as well in case of anterior approach when the hernia is of remarkable proportions; on the other hand, in case of a small hernia the procedure can be performed under local anesthesia. The choice of the type of anesthesia should be made based on several factors. Above all, the position of the patient on the operating table: there is unanimous consensus for lateral decubitus position with the table flexed at the level of the iliac crest, so as to increase the space between the twelfth rib and the iliac crest. Such a position might be very uncomfortable for the patient to bear under local anesthesia, and it could make harder to manage any anesthesiologic complications. It is worth pointing out that the appropriate positioning of the patient simplifies the surgical intervention and that the operating position is a compromise between the imperatives of the surgical approach, patient's physical tolerability and the necessities of the anesthesia. We have preferred general anesthesia in order to manage patients' comorbidities and their limited compliance.

For what concerns the anterior approach, there are some doubts left unanswered in literature: there is no wide consensus on hernial sac dissection and on the repair of the wall defects with plugs. Salameh¹³ claims that a direct suture or a plug are not advisable as the site of the hernia has rigid margins. It is preferable to use a mesh located in the extraperitoneal space instead, under the muscular layers. Solaini et al.¹⁴ reports the first case treated with a polypropylene dart mesh and Yamaguchi et al.¹⁵ in 2013 reports the first case of PAGH repaired with a partially absorbable (Ultrapro®) plug.

For our patients we have followed the same procedure generally adopted for the more common, external oblique inguinal hernias:

- open approach;
- hernial sac left intact;
- positioning of a partially absorbable (Ultrapro®) plug in the abdominal wall defect of 2-3 cm in diameter in the transversalis fascia, placing the absorbable component of poliglecaprone in contact with the properitoneal fat and the non-absorbable component of polypropylene in contact with the transversalis fascia, fixing it to the inner side with two diametrically opposed stitches in order to avoid its migration;
- wall defect in the transversalis fascia was sutured with interrupted sutures, covering the plug;
- for further reinforcement of the transversalis fascia,

TABLE I - Laparotomic versus laparoscopic treatment of Primary Acquired Grynfeltt Hernia: review of the literature.

Author	Year	Patient n°	Laparotomy	Laparoscopy
Cavallaro ¹⁰	2007	7	7	-
Armstrong ¹⁶	2008	1	1	-
Lim ¹⁷	2011	1	-	1
Nam ¹⁸	2011	1	-	1
Martin ¹⁹	2012	1	1	-
Cesar ²⁰	2012	1	1	-
Alves	2012	1	-	1
Yamaguchi ¹⁵	2013	1	1	-
Mismar ²²	2013	1	1	-
Belekar ²³	2014	1	1	-
Sundaramurthy ²⁴	2016	1	1	-

which represents the floor of the Grynfeltt triangle, a shaped (Ultrapro®) mesh was placed on top of it and subsequently fixed with a synthetic glue with haemostatic, adhesive, sealant and bacteriostatic properties (Glubran®), which applied in a wet environment, polymerises rapidly, creating a thin elastic layer that naturally adapts to the anatomy of the tissues on which it is affixed, and once polymerized behaves as an inert biomaterial;

– the mesh was then completely covered by the serratus muscle which was sutured above.

Conclusion

Based on our experience and review of the literature (Table I), we believe that for the Primitive Acquired Grynfeltt Hernia, the laparotomic approach is the most appropriate one, using partially absorbable prosthetic materials. In order to perform a fast, easy and safe procedure, lateral decubitus position (with the surgical table flexed at the level of iliac crest) is suggested. We believe that, similarly to the incisional and recurring hernia, laparoscopy is properly indicated for the secondary acquired Grynfeltt Hernia and for recurrences.

Riassunto

Dopo più di 3000 anni dalla prima menzione dell'ernia inguinale nel Papyrus Ebers del 1552 a.C., Barbette nel 1672 suggerisce l'esistenza dell'ernia lombare e nel 1866 Grynfeltt descrive lo spazio anatomico e l'ernia che prenderanno il suo nome.

Nell'Azienda Ospedaliera di Caserta di Rilievo Nazionale ed Alta Specializzazione sono stati operati, in elezione, in 5 anni dal 2008 al 2013, 1605 pazienti per ernie addominali primitive (inguinale, crurale, ombelicale, epigastrica, di Spigelio, di Grynfeltt). Tutti trattati con tecnica open, in quanto ritenuta tecnica gravata da mino-

ri complicanze, migliore compliance dei pazienti e minor costo. In due casi (pari allo 0.12%) si è trattato di Ernia di Grynfeltt acquisita spontanea (Primary Acquired Grynfeltt Hernia - PAGH).

1° paziente di sesso femminile di anni 60, PAGH a sinistra. Classificata come ASA II/III, sottoposta ad intervento chirurgico open della durata di 35 minuti.

2° paziente maschio di sesso maschile di anni 76, con PAGH a destra. Classificato come ASA III, sottoposto ad intervento della durata di 50 minuti.

In entrambi i casi il decorso postoperatorio è stato regolare con dimissione rispettivamente in terza e seconda giornata. Il follow-up rispettivamente a uno, due e tre anni non ha evidenziato recidiva.

A nostro avviso, per l'Ernia di Grynfeltt acquisita primitiva non complicata l'intervento di scelta è laparotomico con l'utilizzo di un plug e mesh parzialmente assorbibili ed è reso più rapido, facile e sicuro dal decubito laterale con il tavolo spezzato all'altezza della cresta iliaca in anestesia generale.

References

- Grynfeltt J: *La Hernie Lombaire*. Montp Med, 1866; 16:329.
- Loukas M, et al.: *The clinical anatomy of the triangle of Grynfeltt Hernia*, 2008; 12(3): 227-31.
- Cavallaro A, De Toma G, Cavallaro G: *Lumbar hernia: A short historical survey*. Ann Ital Chir, 2012; 83(5):451-54.
- Dobbeleir J, et al.: *Chronic contained rupture of an abdominal aortic aneurysm presenting as a Grynfeltt lumbar hernia. A case report*. Acta Chir Belg, 2007; 107(3): 325-27.
- De Marco G, et al.: *Petit's lumbar hernia: About a case*. Ann Ital Chir, 2004; 75(4): 495-98.
- Skrekas, G, Stafyla V, Papalois VE: *A Grynfeltt hernia: Report of a case*. Hernia, 2005; 9(2):188-91.
- Salameh, JR, EJ Salloum: *Lumbar incisional hernias: Diagnostic and management dilemma*. JSLS, 2004; 8(4): 391-94.
- Mingolla GP, Amelio G: *Lumbar hernia misdiagnosed as a subcutaneous lipoma: A case report*. J Med Case Rep, 2009; 3:9322.
- Moreno-Egea A, et al.: *Open vs laparoscopic repair of secondary lumbar hernias: A prospective nonrandomized study*. Surg Endosc, 2005; 19(2):184-87.
- Cavallaro G, et al.: *Primary lumbar hernia repair: The open approach*. Eur Surg Res, 2007; 39(2):88-92.
- Cavallaro G, et al.: *Anatomical and surgical considerations on lumbar hernias*. Am Surg, 2009; 75(12):1238-241.
- Suarez S, JHernandez ID: *Laparoscopic repair of a lumbar hernia: report of a case and extensive review of the literature*. Surg Endosc, 2013; 27(9): 3421-429.
- Salameh JR: *Primary and unusual abdominal wall hernias*. Surg Clin North Am, 2008; 88(1):45-60, viii.
- Solaini L, et al.: *A very simple technique to repair Grynfeltt-Lesshaft hernia*. Hernia, 2010; 14(4):439-41.

15. Yamaguchi S, et al.: *Lumbar hernia treated with lightweight partially absorbable mesh: Report of a case*. Fukuoka Igaku Zasshi, 2013; 104(12):575-79.
16. Armstrong O, et al.: *Lumbar hernia: Anatomical basis and clinical aspects*. Surg Radiol Anat, 2008; 30(7): 533-7; discussion 609-10.
17. Lim MS, et al.: *Laparoscopic total extraperitoneal repair of lumbar hernia*. J Korean Surg Soc, 2011; 81(4):287-90.
18. Nam SY, Kee SK, Kim JO: *Laparoscopic transabdominal extraperitoneal mesh repair of lumbar hernia*. J Korean Surg Soc, 2011; 81(Suppl 1):S74-7.
19. Martin G, Oviedo M, Davila D, Gumbau V, Martinez C, Roig JV: *Grynfeltt hernia: A case report and literature review*. Chirurgia, 2012; 25(4):257-59.
20. Cesar D, Valadao M, Murrahe RJ: *Grynfeltt hernia: Case report and literature review*. Hernia, 2012; 16(1):107-11.
21. Rafael Tronco AG, et al.: *Grynfeltt-Lesshaft hernia*. Ann Gastroenterol, 2012; 25(1):64.
22. Mismar A, et al.: *Underlay mesh repair for spontaneous lumbar hernia*. Int J Surg Case Rep, 2013; 4(6): 534-36.
23. Belekara, D.M., et al., *Primary Grynfeltt's Hernia*. Indian J Surg, 2014. 76(2): 145-47.
24. Sundaramurthy S, et al.: *Primary lumbar hernia: A rarely encountered hernia*. Int J Surg Case Rep, 2016; 20:53-6.