

Use of intraoperative endoscopy to localize bleeding in the small intestine



Ann. Ital. Chir., 2012 83: 29-33

Antonio Manzelli**, Piero Rossi*, Athanasios Petrou**, Giuseppe De Sica*, Edoardo Ricciardi*, Paris Pappas**

*Dipartimento di Chirurgia D'Urgenza, Senologica e dei Trapianti, Policlinico Tor Vergata, Roma, Italy

**HPB and Transplant Surgery, Churchill Hospital Old Road, Headington Oxford, UK

Use of intraoperative endoscopy to localize bleeding in the small intestine

INTRODUCTION: *Bleeding within the small intestine is difficult to diagnose and localize because it typically occurs at a slow rate. These patients may undergo multiple transfusions and repeated endoscopy, contrast studies, bleeding scans, and angiography before the bleeding source is identified.*

CASE REPORT: *We report a case of 64-year-old woman, where both endoscopic and angiographic techniques were used to localize protracted bleeding. During endoscopic treatment, the arteriovenous malformations continued bleeding. However, highly selective angiography and intraoperative endoscopy outlined the segments of small intestine for resection. This case reviews the evaluation, localization and treatment of small intestine bleeding.*

DISCUSSION: *Localizing the site of protracted bleeding in the small intestine beyond the duodenum bulb can be problematic. For some patients, the course of examinations and transfusions can take years. The small intestine is an uncommon site for gastrointestinal hemorrhage, and only 3%–5% of gastrointestinal bleeding occurs between the ligament of Treitz and the ileocecal valve. The length and location of the small intestine, along with other anatomical factors, make this area difficult to assess with endoscopy or radiology. In this case of protracted bleeding, highly selective angiography and intraoperative endoscopy were used to locate the source of the bleeding.*

KEY WORDS: Bleeding, Intraoperative endoscopy, Small intestine

Introduction

Bleeding from the small bowel can be notoriously difficult to localize and the underlying diagnosis equally difficult to establish. Patients may undergo multiple transfusions, repeated endoscopy, radiological contrast studies, bleeding scans and angiography, before the bleeding source is identified.

The small intestine is an uncommon site for gastrointestinal (GI) haemorrhage, with only 3-5% of gastrointestinal bleeding occurring between the Treitz ligament and the ileocecal valve.¹ The length and the location of this area make assessment difficult with common endoscopy or conventional radiology.

We report a case of 64-year-old woman, where both endoscopic and radiological techniques were used to localize a protracted low grade intestinal bleed. Highly selective angiography and intraoperative endoscopy demonstrated the segments of small intestine affected and a selected small bowel resection was made. This case reviews the evaluation, localization and treatment of small intestinal bleeding, emphasising the varied tools available in the diagnosis of such challenging cases.

Pervenuto in Redazione Gennaio 2011. Accettato per la pubblicazione Luglio 2011

Correspondence to: Edoardo Ricciardi, Via Acquaro 110, 00178 Roma (E-mail: edoardoricciardi.md@hotmail.com)

Case report

A 64-year-old woman was evaluated for chronic gastrointestinal bleeding. Initial presentation was with severe microcytic anaemia. Multiple endoscopies and abdominal computed tomography (CT) scans demonstrated no abnormalities. A selected angiography of the mesenteric vessels was unable to identify any arteriovenous malformations of the proximal small intestine. She had recurring episodes of gastrointestinal bleeding every 3, 6 or 12 months, requiring a transfusion of one to two units of packed red blood cells (PRBC) on each occasion. This persisted for several years, increasing in frequency in recent months, and requiring a total of 12 transfusions for recurring intestinal bleeding.

Upper and lower endoscopy revealed only mild gastritis of the prepyloric region with no ulceration or erosions in the stomach and normal appearances throughout the remaining intestinal tract. Two weeks following endoscopy, the patient had another episode of bleeding which required 3 units of PRBC. A repeat extended upper endoscopy found no active bleeding. On repeat mesenteric arteriography, the celiac and inferior mesenteric arteriograms were normal, but the superior mesenteric arteriogram showed multiple, small, focally dilated vessels consistent with arteriovenous malformation involving the proximal and middle jejunum. The lesions involved 2 jejunal branches of the superior mesenteric artery with the remainder of the vessel uninvolved.

A surgical consultation recommended operative intervention and the patient was taken to theatre and a mid-line incision was made. A complete abdominal exploration, including macroscopic assessment of the small intestine found no abnormalities. An intraoperative endoscopy was performed in the operative room through an enterotomy. Two segments of proximal and mid jejunum were identified to be affected by localized arteriovenous malformations. Approximately 45 cm of proximal and mid jejunum were removed and a side to side anastomosis was performed. Postoperatively, the patient had an uneventful recovery and has not had any further episodes of bleeding in 18 months.

Discussion

Patients with bleeding of the small intestine often present with protracted blood loss, or recurring, undiagnosed episodes of melena. Vascular lesions represent nearly 80% of the aetiology for bleeding in the small intestine and can present with occult bleeding.^{1,2} Angiodysplasia is the most common vascular abnormality.² Other vascular lesions are hemangiomas, arteriovenous malformations and telangiectasias.³ The differential diagnosis for other sources of bleeding should include small intestinal neoplasm or metastatic deposits, diverticular bleeding as for Meckel's diverticulum, inflamma-

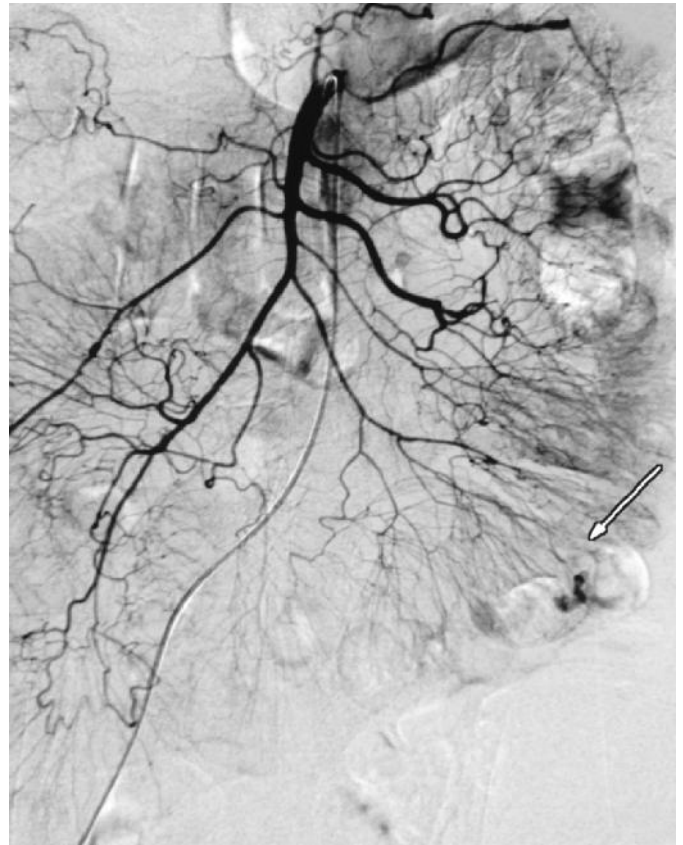


Fig. 1: SMA selective angiography. The arrow shows the bleeding point.

tory bowel disease, infectious enteritis, and aortoenteric fistula.

The portion of the gastrointestinal tract between the duodeno-jejunal (DJ) flexure (Treitz Ligament) and the ileocecal valve is difficult to assess with endoscopy or radiology for many reasons; small intestine length, location, looping, and previous surgery. Besides these mechanical problems, the bleeding rate may be slow or intermittent; making identification and localization by angiography or nuclear bleeding scans extremely challenging. Small-intestinal contrast studies are helpful for identifying neoplasm in the small intestine, but they are usually normal for occult gastrointestinal bleeding with a vascular aetiology. Extended upper endoscopy is an option to investigate bleeding from the small intestine but other diagnostic procedures have had discordant results in localizing small intestinal bleeding. Small bowel endoscopy or push enteroscopy has been reported to diagnosis the cause of occult small bowel bleeding in 50% of cases^{4,5}. One study reports to have achieved an average of scoping of 108 cm over the DJ flexure.⁶ Retrograde endoscopy uses a standard colonoscope to intubate the ileocecal valve and examine the distal ileum. The length of ileum seen is minimal, and it is diagnostic in 2.7% of the cases⁷. Capsule endoscopy is a new technique and Scapa *et al* report successful localization of the source of bleeding in

15 of 20 patients with iron-deficiency anemia⁸. When the bleeding has a vascular aetiology, enteroclysis studies have a diagnostic yield of 10% to 20%. When the underlying cause is a neoplasm, enteroclysis studies can have a sensitivity approaching 90%⁹⁻¹¹. Standard small bowel follow-through studies have an even lower yield about 0% to 5%.

Radioisotope bleeding scans utilize an isotope with a long half-life, which is helpful in repeated scanning. With a positive result, angiography can subsequently help confirm or locate the source of bleeding. Intraoperative sequential segment angiography showed a success in 67% when used to verify a nuclear scan with an immediate blush¹²⁻¹⁴. Methylene blue injection is another well known procedure utilized to identify small bowel bleeding. Methylene blue or fluorescein is administered intraoperatively directly into the vessels supplying the vascular lesion. The aim is to localize any vascular lesions in the small intestinal segments for resection. This technique does not require a second artery catheterization, but it has the disadvantage of requiring a dissection of the appropriate visceral artery¹⁵⁻²⁰.

Intraoperative enteroscopies remain a very important practice in the diagnosis of small bowel haemorrhage. It is able to identify arteriovenous malformations, ulcers, Crohn's disease, carcinoid, Peutz-Jeghers syndrome and bleeding polyps. In a study with forty-one patients with occult gastrointestinal (GI) bleeding Kopacova *et al* report the procedure was diagnostic in 37/41 patients (90.2%). Hartmann *et al* and Kendricke *et al* also demonstrate impressive results with intraoperative enteroscopy diagnosing small bowel bleeding in 34/47 (72%) and 52/70 (74%) patients respectively²¹⁻²³. Duggan used the intraoperative enteroscopy in a 4-month-old infant with occult intestinal bleeding and stricture.²⁴ The major indication for intraoperative enteroscopy in occult GI bleeding at the duodeno-jejunal (DJ) flexure is in patients with a negative CT scan, negative RMN, negative gastroscopy, pushed enteroscopy, and colonoscopy. Intraoperative endoscopy can be performed through an enterotomy during open or laparoscopic-assisted techniques with a success rate for localizing bleeding from 70% to 100%^{25,26}.

Conclusion

In our case, the use of intraoperative enteroscopy although tedious and time consuming showed two arteriovenous malformations which were selectively resected. No further treatments were needed. The patient did not report recurrent episodes of bleeding or anaemia at 24 months follow up. Identifying the source and diagnosis of occult small intestinal bleeding can be extremely challenging. Overall, through an understanding of the range of investigative techniques available, the correct diagnosis can be identified and potential curative treatment initiated.

Riassunto

INTRODUZIONE: Il sanguinamento del piccolo intestino è difficile da diagnosticare e localizzare poiché spesso è di piccola entità. I pazienti spesso necessitano di trasfusioni multiple ed endoscopie ripetute, esami di diagnostica per immagini, analisi del sangue ed angiografie prima che la sede del sanguinamento sia identificata.

CASE REPORT: Riportiamo il caso di una donna di 64 anni, che è stata sottoposta ad sia un'endoscopia che un'angiografia per localizzare un sanguinamento protratto nel tempo. Durante il trattamento endoscopico le malformazioni artero-venose hanno continuato a sanguinare. L'angiografia altamente selettiva e l'endoscopia intraoperatoria hanno permesso di identificare il tratto di piccolo intestino da resecare. Questo caso riporta la valutazione, la localizzazione ed il trattamento del sanguinamento del piccolo intestino.

DISCUSSIONE: Localizzare il sito di un sanguinamento protratto del piccolo intestino, oltre il bulbo duodenale, può essere assai complesso. In alcuni pazienti, esami e trasfusioni sono stati ripetuti per anni. Il piccolo intestino è un sito non comune di emorragia gastrointestinale, e solo il 3%-5% dei sanguinamenti gastrointestinali si localizza tra il legamento del Treitz e la valvola ileo-cecale. La lunghezza e la sede del piccolo intestino, unite ad altri fattori anatomici, rendono quest'area difficile da indagare sia per via endoscopica che radiografica. In questo caso di sanguinamento protratto, l'angiografia altamente selettiva e l'endoscopia intraoperatoria sono state impiegate con successo per localizzare l'origine del sanguinamento.

References

1. Bass BL, Alvarez C: *Acute gastrointestinal hemorrhage*. In: Townsend CM, Sabiston DC, (eds) *Sabiston Textbook of Surgery: The Biological Basis of Modern Surgical Practice*. 16th ed. Philadelphia, PA: Saunders, 2001; 795-866.
2. Lewis BS: *Vascular diseases of the small intestine*. In: DiMarino AJ, (ed). *Gastrointestinal Disease: An Endoscopic Approach*. Malden, Mass: Blackwell Science, 1997; 541-50.
3. Lewis B, Mauer Harper N, et al.: *The correlation of endoscopically identified vascular lesions to the pathologic diagnosis* [abstr]. *Gastrointest Endosc*, 1993; 39:344.
4. Chamberlain SA, Soybel DI: *Occult and obscure sources of gastrointestinal bleeding*. Review. *Curr Probl Surg*, 2000; 37(12):861-65.
5. Kessel ER, Forsmark CE: *Prospective evaluation and follow-up of push enteroscopy in unexplained gastrointestinal bleeding: Does it live up to its promises?* [abstr]. *Gastrointest Endosc*, 1995; 41:366.
6. Barkin JS, Chong J, Reiner DK: *First-generation video enteroscopy: fourth-generation push-type small bowel enteroscopy utilizing an overtube*. *Gastrointest Endosc*, 1994; 40:743-47.
7. Borsch G, Schmidt G: *Endoscopy of the terminal ileum*.

- Diagnostic yield in 400 consecutive examinations.* Dis Colon Rectum, 1985; 28:499-501.
8. Scapa E, Jacob H, Lewkowicz S, et al.: *Initial experience of wireless-capsule endoscopy for evaluating occult gastrointestinal bleeding and suspected small bowel pathology.* Am J Gastroenterol, 2002; 97:2776-779.
 9. Ress AM, Benacci JC, Sarr MG: *Efficacy of intraoperative enteroscopy in diagnosis and prevention of recurrent, occult gastrointestinal bleeding.* Am J Surg, 1992; 163:94-99.
 10. Levine MS, Rubesin SE, Laufer I: *Pattern approach for diseases of mesenteric small bowel on barium studies.* Review Radiology, 2008; 249(2):445-60. Epub 2008 Sep 23.
 11. Ng DA, Opelka FG, Beck DE, et al.: *Predictive value of technetium Tc 99m-labeled red blood cell scintigraphy for positive angiogram in massive lower gastrointestinal hemorrhage.* Dis Colon Rectum, 1997; 40:471-77.
 12. Moch A, Herlinger H, Kochman ML, et al.: *Enteroclysis in the evaluation of obscure gastrointestinal bleeding.* Am J Roentgenol, 1994; 163:1381-384.
 13. Maglinte DD, Kelvin FM, O'Connor K, Lappas JC, Chernish SM: *Current status of small bowel radiography.* Review, Abdom Imaging, 1996; 21(3):247-57.
 14. Lau WY, Yuen WK, Chu KW, et al.: *Obscure bleeding in the gastrointestinal tract originating in the small intestine.* Surg Gynecol Obstet, 1992; 174:119-24.
 15. Schechter S, Deorchis D, Bass J, Marcoux DA: *Angiographic selective methylene blue staining of an occult small-bowel arteriovenous malformation.* Am Surg, 2002; 68(1):15-7.
 16. Yang J, Chen F, Fu W, Xu X: *Selective superior mesentery arteriography and guide wire as an intraoperative locating mark in small intestine resection for arteriovenous malformations.* Chin Med J (Engl), 1998; 111(9):829-31.
 17. Athanasoulis CA, Moncure AC, Greenfield AH, et al.: *Intraoperative localization of small bowel bleeding sites with combined use of angiographic methods and methylene blue injection.* Surgery, 1980; 87:77-84.
 18. Phillips DA, Wertheimer MD, Patwardhan N, et al.: *Preoperative angiography and embolization of the site of intermittent acute small bowel bleeding with a radiopaque microcoil: Facilitated precise surgical excision of the source.* Surgery, 1996; 119:714-17.
 19. DeBarros J, Rosas L, Cohen J, et al.: *The changing paradigm for the treatment of colonic hemorrhage: Superselective angiographic embolization.* Dis Colon Rectum, 2002; 45:802-808.
 20. Yang J, Chen F, Fu W, Xu X: *Selective superior mesentery arteriography and guide wire as an intraoperative locating mark in small intestine resection for arteriovenous malformations.* Chin Med J (Engl), 1998; 111(9):829-31.
 21. Kopacova M, Bures J, Vykouril L, Hladik P, Simkovic D, Jon B, Ferko A, Tacheci I, Rejchrt S: *Intraoperative enteroscopy.* 2006; 21:1111-116.
 22. Hartmann D, Schmidt H, Bolz G, Schilling D, Kinzel F, Eickhoff A, Huschner W, Moller K, Jackobs R, Reitzig P, Weickert U, Gellert K, Schultz H, Guenther K, Hollerbuhl H, Schoenleben K, Schulz HJ, Reiman JF: *A prospective two-center study comparing wireless capsule endoscopy with intraoperative enteroscopy in patients with obscure GI bleeding.* Gastrointestinal Endosc, 2005; 61:826-32.
 23. Kendrick ML, Buttar NS, Anderson MA, Lutzke LS, Peia D, Wang KK, Sarr MG: *Contribution of intraoperative enteroscopy in the management of obscure gastrointestinal bleeding.* J Gastrointest Surg, 2001; 5:162-67.
 24. Duggan C, Shamberger RC, Antonioli D, Leichtner AM: *Intraoperative enteroscopy in the diagnosis of partial intestinal obstruction in infancy.* Dig Dis Sci, 1995; 40:2236-238.
 25. Ohri SK, Jackson J, Desa LA, Spencer J: *The intraoperative localization of the obscure bleeding site using fluorescein.* J Clin Gastroenterol, 1992; 14:331-34.
 26. Morris AJ: *Small-bowel investigation in occult gastrointestinal bleeding.* Review Semin Gastrointest Dis, 1999; 10(2):65-70.

Commento e Commentary

PROF. ROSARIO SACCO
Ordinario di Chirurgia Generale
Università degli Studi "Magna Grecia" di Catanzaro

As shown in the literature only 3/5% of the bleedings of the small intestine are located between the second portion of the duodenum and the ileocecal valve.

Nevertheless, the possibility of finding the source of these losses is complicated by several characteristics of the bowel (length, vigorous contractility, mobile small bowel and the gastric loop above).

All these variables limit the diagnostic ability of studies with barium and endoscopic intubation, requiring the identification of the bleeding sites by special imaging studies (nuclear medicine scans and angiography).

It's also to be considered that, in addition to these technical problems, the rate of bleeding may be slow or intermittent, thereby not allowing the identification with modern invasive scanning techniques. The most used methods are: enteroclysis, transillumination, MRI, CT enteroclysis, labeled red blood celi scintigraphy, CT Angiography, Pushenteroscopy.

In this paper two techniques are combined: the selective angiography, by which, we must remember; you can detect bleeding with a minimum rate of 0.5 ml/min with a success rate ranging from 25-40 % (high-flow), and the intra-operative enteroscopy via enterotomy access, which compared to push-enteroscopy has the advantage of a shorter processing time, with the possibility to use a tool that is shorter than classic enteroscopy and can give 360-degree view of the lumen without blind spots, a fact that is a characteristic disadvantage of push-enteroscopy.

The successful treatment of this case is essentially linked to the lack of bleeding and the preoperative identification of the site, through selective arteriography.

In our opinion, therefore, the reproducibility of the method may be affected by bleeding, especially if massive, which would make it impossible to view angiodysplasia, including large size, an aspect this, that would increase the diagnostic accuracy of methods such as labeled red blood celi scintigraphy and the angio-CT.

The work is still basically sound with some original suggestions that make it acceptable for publication, after a series of smaller adjustments (updating bibliography and adding iconography).

* * *

Come si evince dalla Letteratura solo il 3-5 % dei sanguinamenti del piccolo intestino sono localizzati tra la seconda porzione del duodeno e la valvola ileo-ciecale. Ciò nondimeno, la possibilità di trovare la fonte di queste perdite è resa più difficile da alcune caratteristiche del viscere (lunghezza, contrattilità vigorosa, libertà intra-peritoneale e loop gastrico sovrastante). Tutte queste variabili limitano la capacità diagnostica degli studi col bario e l'intubazione endoscopica, imponendo l'identificazione dei siti di sanguinamento mediante studi di imaging speciale (Scansioni di medicina nucleare ed angiografia). È inoltre da considerare che, oltre a questi problemi tecnici, il tasso di sanguinamento può essere lento o intermittente, non consentendone in tal modo l'identificazione da parte delle invasive e moderne tecniche di scansione. Le metodiche più utilizzate sono: Enteroclisi, Transilluminazione, RM, TC con enteroclisi, Emazie marcate, Angiografia TC, Enteroscopia-Push.

In questo lavoro vengono abbinate due metodiche, l'Angiografia selettiva, che ricordiamo, è in grado di rilevare emorragie con tasso minimo di 0,5 ml/min con una percentuale di successo che varia dal 25-40% (low-flow), fino al 50-72% (high-flow) e l'enteroscopia tramite accesso intra-operatorio enterotomico, che rispetto all'enteroscopia push ha sicuramente il vantaggio di avere tempi di procedure più brevi, con la possibilità di usare uno strumento che rispetto all'enteroscopia classico è più corto e consente di dare visione a 360° del lume intestinale, senza punti ciechi, svantaggio questo caratteristico dell'enteroscopia-push. Il successo del trattamento del presente caso clinico è legato essenzialmente alla mancanza di sanguinamento in atto ed all'identificazione pre-operatoria della sede, attraverso l'arteriografia selettiva.

A Nostro avviso quindi la riproducibilità della metodica può essere inficiata dall'emorragia in atto, soprattutto se massiva, cosa che renderebbe impossibile la visualizzazione delle angiodisplasie, anche di grosse dimensioni, aspetto questo che aumenterebbe invece l'accuratezza diagnostica di metodiche quali l'emazie marcate e l'angio-TC. Il lavoro appare comunque formalmente corretto con alcuni spunti di originalità che lo rendono accettabile per la pubblicazione, dopo una serie di accorgimenti minori (aggiornamento Bibliografia ed aggiunta Iconografia).

References

1. Pasha SF, Hara AK, Leighton JA: *Diagnostic Evaluation and Management of obscure gastrointestinal bleeding: A changing paradigm.* Gastroenterology and Hepatology, 2009; 5(12).
2. B. Lewis B, GoldFarb N: *Review article: The advent of capsule endoscopy a not so futuristic approach to obscure gastrointestinal bleeding.* The Mount Sinai Medical Center, New York, USA. Aliment Pharmacol Ther, 2003; 17:1085-1096.
3. Cerezo ER: *Role of wireless capsule endoscopy in inflammatory bowel disease.* World Journal of Gastrointestinal endoscopy, 2010; 16,2(5):179-85.
4. Jacobs R, Hartmann D, Benz C, Schilling D, Weickert U, Eickhoff A, Schoenleben K, Riemann JF: *Diagnosis of obscure gastrointestinal bleeding by intraoperative enteroscopy in 81 consecutive patients.* World Journal of Gastroenterology, 2006; 12(2):313-16.

