

Incidental rectal carcinoid discovered after stapled hemorrhoidopexy: importance of histopathologic examination



Ann. Ital. Chir., 2011 82: 155-157

Antonio Di Cataldo*, Rosalia Latino*, Aldo Cocuzza*, Giovanni Li Destri*, Raffaele Lanteri*, Mitchell Wachtel**, Eldo Ermenegildo Frezza***

*Chair of General Surgery (Director: Prof. A. Di Cataldo), University of Catania, Catania, Italy

**Department of Pathology, Texas Tech University School of Medicine, Lubbock, TX, USA

***Center for metabolic disease, Henderson, TX, USA

Incidental rectal carcinoid discovered after stapled hemorrhoidopexy: importance of histopathologic examination

AIM: *Haemorrhoids are the most common surgically-treated gastrointestinal disorder. Complications of this surgery are generally non-neoplastic. Because rectal tumours usually present demonstratively during endoscopic examination, it is perhaps tempting to omit histopathologic examination after haemorrhoidectomy, especially in younger patients.*

METHODS: *The AA present a case of an early rectal carcinoid discovered after surgical treatment of haemorrhoids in a 27 years old man as an example of why it is essential to send all such specimens in the pathologist.*

RESULTS: *The detection of early lesions permits the adequate follow-up necessary to preclude more extensive surgery and eventually to prevent recurrence of tumour.*

CONCLUSION: *All tissue resected by haemorrhoidopexy must be sent to the pathology laboratory to protect the life and health of the patient .*

KEY WORDS: Haemorrhoids, Haemorrhoidectomy, Histopathologic examination, Rectal carcinoid

Introduction

Hemorrhoids are the most common surgically-treated gastrointestinal disorder ¹. Complications of this surgery are generally non-neoplastic ²⁻⁷. Because rectal tumors usually present demonstratively during endoscopic examination ⁸⁻¹⁰, it is perhaps tempting to omit histopathologic examination after hemorrhoidectomy, especially in younger patients. We present a case of an early rectal

carcinoid discovered after surgical treatment of haemorrhoids in a 27 year old man as an example of why it is essential to send all such specimens to the pathologist.

Materials and Methods

A 27 year old man complained of three months of hematochezia, pain on defecation, incomplete emptying of the bowels, pruritis ani, and a feeling of rectal fullness. Physical examination and procto-sigmoidoscopy revealed grade III haemorrhoids without evidence of other mass. Stapled hemorrhoidopexy was performed.

Histopathologic examination of excised mucosal/submucosal ring revealed nests and trabeculae of uniform, amiototic cells with salt and pepper chromatin, immunohistochemically positive for synaptophysin and negative for chromogranin A, diagnostic for low grade neuroendocrine carcinoma (carcinoid) (Fig. 1). The 3 mm tumor

Pervenuto in Redazione: Settembre 2010. Accettato per la pubblicazione Dicembre 2010

Correspondence to: Antonio Di Cataldo, MD, FACS, University of Catania, Department of Surgical Sciences, Organ Transplantation and Advanced Technologies, Viale Odorico da Pordenone 5, 95128 Catania, Italy (e-mail: dicataldo@tiscali.it)

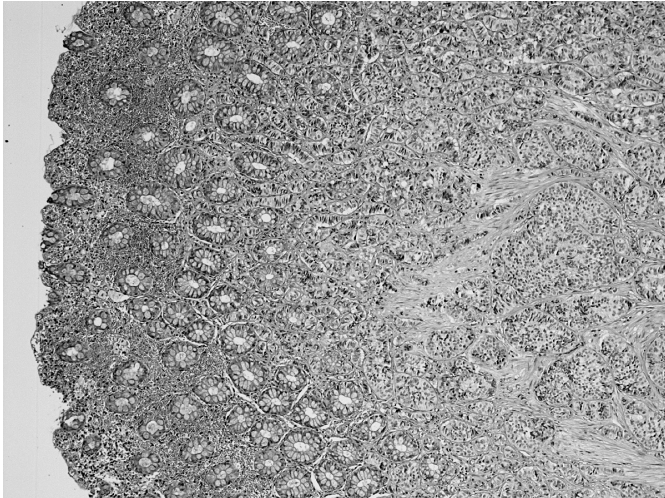


Fig. 1: Rectal carcinoid limited to the lamina propria/muscularis mucosae (histologic diameter 3 mm), with the submucosa free of the neoplasm.

was confined to the lamina propria and muscularis mucosa, without extension into the submucosa. Neoplastic cells resulted negative to the Chromogranin A, positive to the Synaptophine and to the Enolasi neuro-specific.

Follow-up biopsies lacked residual tumor.

Abdominopelvic CT scans revealed no metastatic deposits or residual tumor. A 24 hour urinary 5-HIAA study was negative. Serum levels of chromogranin A, histamine, substance P, and serotonin were normal.

Results and Discussion

Over nine of ten neuroendocrine tumors arise in the gut and pancreas, a set of lesions now referenced as gastroenteropancreatic neuroendocrine tumors, divided embryologically into foregut lesions (stomach, duodenum, upper jejunum, and pancreas), midgut lesions (lower jejunum, ileum, appendix, and cecum), and hind gut lesions (non-cecal colon and rectum) ¹¹⁻¹². Whereas 12.6% of neuroendocrine tumors arise in the rectum, only 1.3% of rectal tumors are neuroendocrine tumors ¹³. Because the carcinoid syndrome is so rare and the symptoms, hematochezia, constipation, rectal pain, and pruritis ani, are those of infinitely more common haemorrhoids, the tumors are rarely suspected until an endoscopic examination is performed, usually as a screening procedure ¹⁴. Rectal lesions are smallest GEP-NET's, with SEER data showing a median 6 mm size ¹⁵.

Surgery is the therapeutic mainstay. Although several staging and grading classification schemes exist ¹⁵⁻¹⁶, the European neuroendocrine tumor Society recently produced a new staging and classification system that appears quite reasonable ¹⁷. Tumor size and depth of invasion can reliably guide management. Localized rectal tumors lacking atypical histologic findings no greater

than 1 cm are effectively treated by minimally invasive transanal surgical excision (MITAS) ¹⁸. Lesions greater than 1 cm and no larger than 2 cm, again lacking atypical histologic features, bear a 4-18% risk of spread to regional lymph nodes; although MITAS can be used, deep examination under anesthesia is essential ¹⁹. Lesions with atypical histology, a size greater than 2 cm, or invasion beyond the muscularis propria require more extensive surgery ¹⁷. For small cell carcinomas (poorly differentiated neuroendocrine carcinomas) and better differentiated tumors with metastases, surgery prevents local complications, but does not improve survival ²⁰. Anal sphincter preservation is a major surgical goal, but abdomino-perineal resection is required when the lesion involves or is extremely close to the anal verge. In MITAS treated cases, radiologic and endoscopic follow-up are recommended to ensure adequate therapy has been provided ¹⁸.

Conclusions

There exist times in which one suspects histopathology to be superfluous. The present case, with an age far below the average 56 years seen in SEER data ¹⁵, proves this assertion false with respect to hemorrhoid surgery; the detection of this early lesion permitted the adequate follow-up needed to preclude more extensive surgery and to prevent recurrence of this tumor. All tissue resected by hemorrhoidectomy must be sent to the pathology laboratory to protect the life and health of the patient.

Riassunto

SCOPO: Le emorroidi rappresentano la patologia del tratto gastrointestinale maggiormente trattata chirurgicamente. Le complicanze di questa chirurgia sono generalmente di non neoplastiche. Poiché di solito i tumori rettali sono evidenziabili in corso di esame endoscopico, è prassi non eseguire esame istopatologico dopo emorroidectomia, specialmente nei soggetti giovani.

METODO: Gli Autori presentano un caso di carcinoid rettale in fase precoce scoperto dopo emorroidopessi sec. Longo in un uomo di 27 anni come esempio di quanto sia importante inviare il resecato all'anatomopatologo.

RISULTATI: La scoperta di questa lesione in fase precoce permette un adeguato follow-up al fine di evitare resezi-
oni maggiori e prevenire la recidiva del tumore.

CONCLUSIONI: Tutti i tessuti resecati in corso di emorroidectomia devono essere inviati al patologo per salvaguardare la salute del paziente.

Bibliografia

- 1) Chong PS, Bartolo DC: *Hemorrhoids and fissure in ano*. Gastroenterol Clin N Am, 2008; 37(3):627-44.

- 2) Alabiso ME, Grassi R, Fioroni C, Merano I: *Iatrogenic rectal diverticulum in patients treated with transanal stapled techniques*. Radiol Med, 2008; 113(6): 887-94.
- 3) Beuke AC, Pedersen ME, Qvist N: *Rectal perforation and faecal peritonitis after stapled operation for grade IV haemorrhoids*. Ugeskr Laeger, 2008; 170(6): 460.
- 4) Cirocco WC: *Life threatening sepsis and mortality following staples haemorrhoidopexy*. Surgery, 2008; 143(6):824-29.
- 5) Giordano P, Bradley S, Peiris L: *Obliteration of the rectal lumen after stapled hemorrhoidopexy: Report of a case*. Dis Colon Rectum, 2008; 51(10):1574-576.
- 6) Ivanov D, Babovic S, Selesi D, et al.: *Harmonic scalpel hemorrhoidectomy: A painless procedure?* Med Pregl, 2007; 60(9-10): 421-26.
- 7) van Wensen RJM, van Leuken MH, Bosscha K: *Pelvic sepsis after haemorrhoidopexy*. World J Gastroenterol, 2008; 14(38): 5924-926.
- 8) Lindsetmp RO, Joh YG, Delaney CP: *Surgical treatment for rectal cancer: An international perspective on what the medical gastroenterologis need to know*. World J Gastroenterol, 2008; 14(21): 3281-289.
- 9) Trombetta LJ, Place RJ: *Giant condyloma acuminatum of the anorectum: Trends in epidemiology amd management.Report of a case and review of the literature*. Dis Colon Rectum, 2001; 44(12): 1878-886.
- 10) Wong S, Gibbs P, Chao M, et al.: *Carcinoma of the anal canal: A local experience and review of the literature*. ANZ J Surg, 2004; 74(6):541-46.
- 11) Modlin IM, Oberg K, Chung DC, et al.: *Gastroenteropancreatic neuroendocrin tumours*. Lancet Oncol, 2008; 9(1):61-72.
- 12) Williams ED, Sandler M: *The classification of carcinoid tumours*. Lancet, 1963; i(727).
- 13) Modlin IM, Kidd M, Latich I, et al.: *Current status of gastrointestinal carcinoids*. Gastroenterology, 2005; 128(6):1717-751.
- 14) Jetmore AB, Rai JE, Gatriight JB jr, et al.: *Rectal carcinoids :the most frequent carcinoid tumour*. Dis Col Rectum, A 1992;35(8):717-25.
- 15) Landry CS, Brock G., Scoggins CR, et al.: *A proposed staging system for rectal carcinoid tumours based on an analysis of 4701 patients*. Surgery, 2008; 144(3):460-66.
- 16) Kloppel G, Rindl G, Arnaulf M., et al.: *Site-specific biology and pathology of gastroenteropancreatic neuroendocrine tumours*. Virchows Arch, 2007; 451(suppl 1): S9-S27.
- 17) Rindl G, Kloppel G, Cpuvelard A, et al.: *TNM staging of midgut and hindgut(neuro)endocrine tumours: A consensus proposal including a grading system*. Vichows Arch, 2007; 451(4):757-62.
- 18) Maeda K, Maruta M, Utsumi T, et al.: *Minimally invasive transanal surgery for localized rectal carcinoid tumours*. Tecg Coloproctol, 2002; 6(1):33-36.
- 19) Shirouzu K, Isomoto H, Kakegawa T, Morimatsu M: *Treatment of rectal carcinoid tumours*. Am J Surg, 1990, 160(3):262-65.
- 20) Brenner B, Tang LH, Shia J, et al.: *Small cell carcinoma of the gastrointestinal tract: Clinicopathological features and treatment approach*. Semin Oncol, 2007; 34(1):43-50.

