

Combined approach for the treatment of anorectal condyloma.

Carbon dioxide laser excision and endoscopic argon plasma coagulation in a case report.



Ann. Ital. Chir., 2011 82: 159-162

Stefano Pontone, Daniele Pironi, Paolo Pontone and Angelo Filippini

Department of Surgical Sciences, "Sapienza" University of Rome, Rome, Italy

Combined approach for the treatment of anorectal condyloma. Carbon dioxide laser excision and endoscopic argon plasma coagulation in a case report.

Condyloma acuminatum (CA) is a sexually transmitted disease caused by human papilloma virus (HPV). Infection with HPV is a major risk factor for development of anal squamous cell carcinoma. In clinical practice, it is frequently limited to the perianal skin or anal canal and it is rarely described a rectal mucosal extension. Several therapeutic options are developed for CA, including chemical or physical destruction, immunological therapy, or a surgical excision. However, these treatments still have some degree of limitations and important side effects compromising patient compliance and reducing treatment efficacy. CO₂-laser emits a continuous beam, absorbed by biologic tissues, that vaporizing intracellular water, destroys target lesions. Argon plasma coagulator (APC) is a non-contact method of endoscopically delivered high-frequency thermal coagulation allowing well-controlled superficial tissue destruction. We present a case of a young female affected by anorectal condiloma extended to rectum, that was successfully treated with combined gynecological (carbon dioxide laser) and endoscopic approach (Argon Plasma Coagulator), with no side effects during the follow up and complete remission after two applications.

KEY WORDS: Argon Plasma, Carbon dioxide laser, Condyloma, HPV.

Introduction

Condyloma acuminatum (CA) is a sexually transmitted disease, caused by human papillomavirus (HPV) infection that has been increasing during the last decade¹. Infection with HPV is a major risk factor for development of anal or cervix squamous cell carcinoma^{2,3}. Despite over 100 genotypes of the virus, HPV 16 and 18 are considered pathogenic as they are seen in the

majority of cervical and anal cancers². Epidemiologic studies identify high risk groups in: adolescents, young adults, persons with multiple sexual partners and human immunodeficiency virus (HIV) affected patients⁴⁻⁸. There is not an agreement on the influence of sex, racial or demographics factors^{4,9}. Most HPV infections are cleared by the immune system and do not result in clinical manifestations. HPV viral subtype, immune status of the patient and environmental co-carcinogenes determine the clinical presentation of infection. Anogenital lesions can be flat, dome-shaped, keratotic, peduncolated and cauliflower-shaped; they may occur singularly, in clusters or as plaques⁸. Symptoms are mostly typical (anal itch/burning and external anal tags) but can be underestimated by patients that often delay treatment. Gold treatment for anogenital warts is still debated and not all methods have been completely tested. Therapeutic options for anogenital warts may be topical (podophyllin

Pervenuto in Redazione: Novembre 2010. Accettato per la pubblicazione Dicembre 2010

Correspondence to: Dr. Stefano Pontone, Department of Surgical Sciences, "Sapienza" University of Rome, V.le Regina Elena 324, 00161 Rome - Italy (e-mail: stefano.pontone@uniroma1.it)

Table I - Clinical application of Argon Plasma Coagulator in Endoscopy.

Endoscopic applications	Indications
Hemostasis	G.A.V.E* Vascular Lesions Radiation Proctopathy Bleeding Peptic Ulcer Esophageal Varices
Ablative	Residual Adenoma Early Gastric Cancer Malignant Obstruction Tumor In-Growth (stents) Barrett's Esophagus
Shortening metallic stents	

(*) Gastric antral vascular ectasia.

resin, imiquimod, trichloroacetic acid and podophylo-toxin) or surgical (carbon dioxide and Nd:YAG-laser vaporisation, surgical excision, loop excision, cryotherapy and electrodesiccation) treatments. However, recurrences are common and there is no single treatment that is superior to others¹⁰. The Argon Plasma Coagulator (APC) is a device intended for thermal coagulation of tissue. Having been introduced in open and laparoscopic surgery, APC was adapted for use in flexible endoscopy in 1991 and has many potential uses. Endoscopic applications of APC continue to expand in the management of various gastrointestinal procedures that requiring: hemostasis, ablation of tissue or resolution of other technical problems (Tab. I). We present the case of a young female affected by an anorectal condiloma extended to rectum that was successfully treated by combined approach: carbon dioxide laser (CO₂ Laser) for perineal lesions and APC for rectal localizations. This minimally invasive treatment did not show side effects during the follow-up and reached a complete remission after two applications.

Case presentation

This the case of a 30 year-old female who was visited by gynecologist for the appearance of anal itching and burning and external anal painless tags, about 6 months before. The gynecologist, based on the anamnesis and clinical presentation diagnosed the presence of perineal condylomatous multiple warts in anogenital area and recommended serological test and surgical removal. Serological tests for syphilis and HIV gave negative results. Therefore, perineal warts were vaporized by CO₂ laser, setting in pulse mode, after local anesthesia (2% lidocaine). Each condyloma was vaporized along with 3 mm border of normal-appearing epithelium without penetrating into the underlying subcutaneous tissue. A

smoke evacuation system was used. Bleeding was coagulated with an electrosurgical system. Lidocaine spray for perineum was used 10 minutes later the procedure. The procedure was performed in the outpatient setting, no significant side effects were recorded. A follow-up visit was scheduled 30 days after the first treatment. Upon examination, the patient showed recurrence of perianal warts. So, the specialist recommended a further CO₂

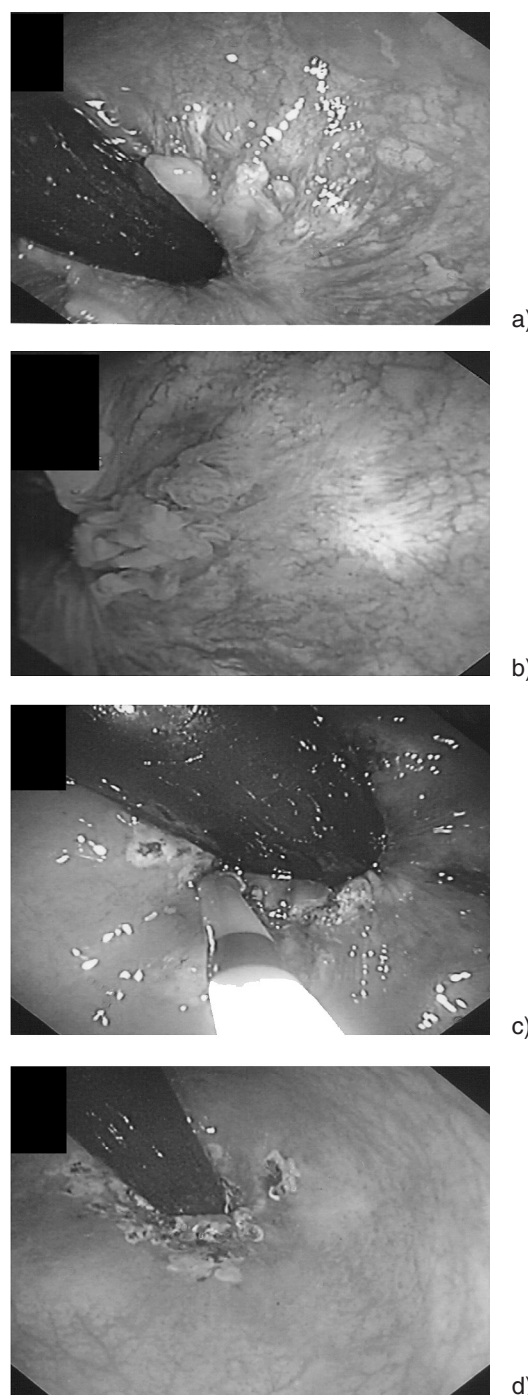


Fig. 1: (A) Rectal mucosa wart and first APC session; anorectal lesions in endoscopic retro-vision; (B) water-immersion vision; (C) elimination of intra-anal warts; (D) post-treatment result.

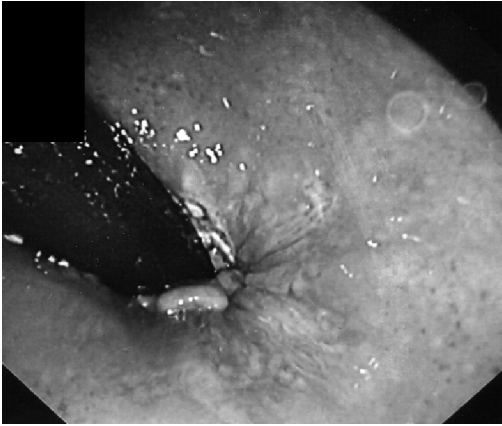

Fig. 2: Second APC session: residual warts elimination.

laser session to eradicate lesions together with a proctoscopy to rule out rectal involvement.

Anoscopy performed after deep sedation in an outpatient operating room, one week after CO₂ session, revealed the presence of circumferentially rectal mucosa warts at about 1 cm above the dentate line (Fig. 1). Rectal biopsies were taken for histological confirmation. After the biopsy sample and polygeline-adrenaline solution infiltration (1:10.000), rectal warts were destroyed by APC in endoscopic retro-vision. Smoke evacuation system was used during the procedure to minimize airborne spread of the papillomavirus. All APC applications were performed by using the Olympus ENDOPLASMA® (Olympus Europe GmbH, Hamburg, Germany) combined with electrosurgical unit PSD-60. Energy transmission on the mucosa surface was guaranteed by a 2,3 mm diameter, 220 cm lengths, APC flexible probe (MAJ-1012, Olympus), with nozzle orientation at the tip of the catheter that was inserted through the working channel of a standard flexible endoscope. None early or late side effects (as pain or bleeding) were reported by the patient. Histological finding was consistent with condyloma acuminatum. An anoscopy follow-up was scheduled 3 months after the APC treatment. At the next endoscopic session, patient showed clearance of external disease and markedly decreasing of rectal lesions that was treated with a new APC session without adverse events (Fig. 2). Rectal biopsies were taken again for histological confirmation. Repeated flexible sigmoidoscopy was also done six months after in order to verify the successful eradication. No clinical or subclinical disease was shown at the anoscopy.

Discussion

There is an important link between the prevalence of squamous-cell cancer of the anal and HPV infection that is present in approximately 1% of the sexually active population. HPV infections may cause squamous intraep-

ithelial neoplasia, which may progress from low grade to high grade and may be found in areas adjacent to squamous cell carcinoma. Previous reports demonstrating that HPV DNA was found in 75-90% of anal squamous cell cancer^{2,11,12} and in more than 95% of cervical carcinoma³. In most cases, the CA diagnosis is based on anamnesis and clinical observation¹³. Differential diagnosis must be made with the flat warts of syphilis (serological testing), molluscum contagiosum lesions, granuloma inguinale and bowenoid papulosis. All patients with external anogenital warts should have proctoscopy and histological examination of all intra-anal lesions¹⁴. There are many treatment options and patients are retreated at regular intervals until successful eradication. Topical treatment includes podophyllotoxin, imiquimod cream and trichloroacetic acid^{15,16}. Surgical therapies include cryotherapy, CO₂ and Nd:YAG-laser vaporisation, APC and surgical excision, that is highly effective but is generally reserved for large or bulky warts that cannot be treated otherwise. Patients with multiple sites of HPV infection could be less likely to respond to topical treatment. Indeed, combination of APC with intra-anal application of imiquimod cream could be effectively used in multiple CA localizations¹⁵. However, Viazis N et al¹³ reported that the effectiveness of treatment with APC alone and APC plus imiquimod is not statistically significant. In our study, APC therapy has been used for the treatment of intra-anal warts proving to be easy, safe, and feasible. APC is a non-contact method of delivering high-frequency monopolar current in a controlled manner. The ionized argon gas contacts the tissue closest to the probe, which allows for either *en face* or tangential application, generally resulting in a 1-3 mm deep coagulation zone. Complication rates of APC are low, especially when compared with other thermal methods of treatment, and is thought to be secondary to the limited depth of coagulation. Moreover, using a submucosal injection of normal saline solution, the incidence of deep tissue injury decreases significantly¹⁸. Considering that, a polygeline-adrenaline solution infiltration was adopted to even more decrease depth of tissue injury and to limit post-biopsy bleeding.

Conclusion

All patients with external anogenital warts should be submitted to proctoscopy and histological examination of intra-anal lesions. Elimination of these lesions is also important to reducing the risk of possible sexual transmission of HPV infection and to form a basis for prevention of anal cancer. Our experience, although limited to a case report, shows that patients affected by CA with perineal and intra-anal localizations, had symptomatic and endoscopic improvement after combined surgical treatment. This combined approach for multiple site condylomata between different surgical techniques, CO₂-

laser and APC, should be considered as a safe and effective treatment. However, larger series of patients need to be studied to further assess the efficacy, complications rating and rate of recurrence.

Riassunto

Il condiloma acuminato è una malattia sessualmente trasmessa provocata dall'infezione da Papilloma Virus Umano e rappresenta un importante fattore di rischio per lo sviluppo del carcinoma anale a cellule squamose. Frequentemente si riscontra a livello della cute perianale e più raramente viene descritto a livello della mucosa rettale. Sono stati adottati diversi trattamenti per l'escissione delle lesioni condilomatose. Tra questi vi sono terapie mediche e chirurgiche che tuttavia presentano alcune limitazioni e spesso effetti collaterali che ne limitano l'efficacia e l'accettabilità da parte del paziente. Il laser a CO₂ emette un fascio continuo che, assorbito dai tessuti biologici, elimina le lesioni trattate vaporizzando l'acqua all'interno delle cellule. L'Argon Plasma Coagulator è un metodica di escissione mediante coagulazione termica controllata, senza contatto, con la quale si ottiene una completa distruzione del tessuto superficiale. In questo studio riportiamo il caso di una giovane donna affetta da condilomatosi anorettale trattata con successo in maniera combinata, con approccio combinato ginecologico (laser ad anidride carbonica) ed endoscopico (argon plasma coagulator), senza comparsa di effetti collaterali nel follow-up e con guarigione completa dopo due trattamenti.

References

- 1) Lorincz AT, Reid R, Jenson AB, Greenberg MD, Lancaster W, Kurman RJ: *Human papillomavirus of the cervix: Relative risk associations of 15 common anogenital types*. Obstet Gynecol, 1992; 79:328-37.
- 2) Ramamoorthy S, Liu YT, Luo L, Miyai K, Lu Q, Carethers JM: *Detection of multiple human papillomavirus genotypes in anal carcinoma*. Infect Agent Cancer, 2010; 5:17.
- 3) Hartmann KE, Hall SA, Nanda K, Boggess JF, Zolnoun D: *Screening for Cervical Cancer* [Internet]. Rockville (MD): Agency for Healthcare Research and Quality (US); 2002.
- 4) Chuang TY, Perry HO, Kurland LT, Ilstrup DM: *Condyloma acuminatum in Rochester. Minn. 1950-1978*. Arch Dermatol, 1984; 120: 469-75.
- 5) Chuang TY: *Condylomata acuminata (genital warts): An epidemiologic view*. J Am Acad Dermatol, 1987; 6:376-84.
- 6) Hippelainen M, Syrjanen S: *Prevalence and risk factors of genital papillomavirus (HPV) infections in healthy males: A study of Finnish conscripts*. Sex Transm Dis, 1993; 20:321-28.
- 7) Baken LA, Koutsky LA, Kuypers J, Kosorok MR, Lee SK, Kiviat NB: *Genital human papillomavirus infection among male and female sex partners: Prevalence and type-specific concordance*. J Infect Dis, 1995; 171:429-32.
- 8) Ghaemmaghami F, Nazari Z, Mehrdad N: *Female genital warts*. Asian Pac J Cancer Prev, 2007; 8(3):339-47.
- 9) *Condylomata acuminata (genital warts): patient demographics and treating physicians*. Fleischer AB Jr, Parrish CA, Glenn R, Feldman SR. Sex Transm Dis. 2001; 28(11):643-47.
- 10) Wiley DJ, Douglas J, Beutner K, et al.: *External genital warts: Diagnosis, treatment, and prevention*. Clin Infect Dis, 2002; 35 (Suppl 2), S210-24.
- 11) Giuliano A, Tortolero-Luna G, Ferrer E, Burchell AN, de Sanjose S, Kruger Kjaer S, Munoz N, Schiffman M, Bosch FX: *Epidemiology of human papillomavirus infection in men, cancers and other than cervical and benign conditions*. Vaccine, 2008; 26:K17-K28.
- 12) Sirera G, Videla S, Piñol M, Cañadas MP, Llatjos M, Ballesteros AL, García-Cuyás F, Castellá E, Guerola R, Tural C, Rey-Joly C, Clotet B: *High prevalence of human papillomavirus infection in the anus, penis and mouth in HIVpositive men*. AIDS, 2006; 20:1201-1204.
- 13) Viazis N, Vlachogiannakos J, Vasiliadis K, Theodoropoulos I, Saveriadis A, Karamanolis DG: *Earlier eradication of intra-anal warts with argon plasma coagulator combined with imiquimod cream compared with argon plasma coagulator alone: A prospective, randomized trial*. Dis Colon Rectum, 2007; 50(12):2173-79.
- 14) Mlakar B: *Proctoscopy should be mandatory in men that have sex with men with external anogenital warts*. Acta Dermatovenerol Alp Panonica Adriat, 2009; 18(1):7-11.
- 15) von Krogh G, Longstaff E: *Podophyllin office therapy against condyloma should be abandoned*. Sex Transm Infect, 2001; 77(6):409-12.
- 16) Fife KH, Ferenczy A, Douglas JM Jr, Brown DR, Smith M, Owens ML: *HPV Study Group. Treatment of external genital warts in men using 5% imiquimod cream applied three times a week, once daily, twice daily, or three times a day*. Sex Transm Dis, 2001; 28(4):226-31.
- 17) Weyandt GH, Benoit S, Becker JC, Bröcker EB, Hamm H: *Controlled layered removal of anogenital warts by argon-plasma coagulation*. J Dtsch Dermatol Ges, 2005; 3(4):271-75.
- 18) Vargo JJ: *Clinical applications of the argon plasma coagulator*. Gastrointest Endosc, 2004; 59(1):81-8.