



Histologic considerations about a rare case of recurrent incisional hernia on McBurney incision



Ann. Ital. Chir.

Published online (EP) 3 December 2014

pii: S2239253X14022828

www.annitalchir.com

Giuseppe Salamone, Leo Licari, Jenny Atzeni, Roberto Tutino, Gaspare Gulotta

Department of Surgical, Oncological and Oral Sciences University of Palermo, General Surgery and Emergency Policlinico Universitario "P. Giaccone", Palermo, Italy

Histologic considerations about a rare case of recurrent incisional hernia on McBurney incision

AIM: Incisional hernias are often related to longitudinal or transverse laparotomy with an incidence that rises from 2 to 23 %. The oblique incision often used to surgically treat acute appendicitis has little probability to develop incisional hernia with an estimated incidence less than 2%. Some series report 0.1 – 0.9% of it. Anatomic, physiologic and histologic factors have been implicated in herniation development, such as intra-abdominal pressure or alteration on tissue components; many different risk factors can be taken into account to justify this rare condition such as female gender, diabetes, peritonitis, abscess or appendiceal phlegmon as the cause of the first operation, wound infection, seroma, use of cutgut to suture aponeurosis, interrupted suture to the aponeurotic layer.

MATERIAL OF STUDY: We present the rare case of young man who underwent surgical operation of acute appendicitis. Mc Burney incision was performed. Successively he underwent re-operation for incisional hernia developed upon McBurney incision and then "recurrence" of the same one.

DISCUSSION AND CONCLUSION: Histological analysis of scar tissue was done. Alteration on histological pattern protein expression was discovered.

KEY WORDS: Histological pattern expression, Incisional hernia, Recurrence; McBurney incision

Introduction

Incisional hernia is a condition that occurs after open or laparoscopic surgery. It is defined "an abdominal wall defect with or without a bulge visible and palpable when the patient is standing during clinical examination, and often requiring support or repair¹⁻³". Incisional hernias

are often related to longitudinal or transverse laparotomy with a probability that rise from 2 to 23%,⁴ but can be considered rare conditions associated to oblique incision used to treat acute appendicitis (McBurney incision). Few data mention incisional hernias on McBurney incision with a reported incidence less than 2%⁵⁻⁷ that occur often in 30 days after surgery^{8,9}, rarely within 2 years after surgery.

The technique used to repair it considers tension-free repair with prosthetic material or suture technique¹⁰⁻¹⁴. This case reports our experience on a young man who underwent surgical operation for acute appendicitis approached through McBurney incision, that developed incisional hernia, repaired with positioning of prosthesis, and relapse of the same one, repaired with positioning of a larger prosthesis than that used before, with major tissue overlap, after removal of the old one.

Pervenuto in Redazione Marzo 2014. Accettato per la pubblicazione Maggio 2014

Correspondence to: Leo Licari Department of Surgical, Oncological and Oral Sciences University of Palermo, General Surgery and Emergency Policlinico Universitario "P. Giaccone", Via Liborio Giuffrè 5, 90127 Palermo, Italy (e-mail: lele.licari@gmail.com)

Many different factors were taken into account to justify this rare condition. Important consideration risen from histological analysis.

Case Report

In 2005 DA (06/11/1990, BMI 27.8, neither comorbidities nor significant anamnestic informations), underwent surgical operation for acute appendicitis at other hospital. Diagnosis was of "phlegmonous appendicitis"; it was performed a McBurney incision and a classic appendectomy operation technique. No postoperative complications occurred. Antibiotic therapy was performed, with Amoxicillin - Clavulanate 875mg/125 mg bid in 5 days; after 1 day hospital stay he was discharged.

Clinical conditions and surgical outcome was considered good also during next medications. Surgical sutures were cut-off in 15th day after operation.

After 5 year after operations, classic signs of incisional hernia occurred, and in 2012 it was made a correct diagnosis at our hospital. Radiological investigations were done, and TC of abdominal wall confirmed it.

It was performed a plastic operation of abdominal wall with polypropylene prosthetic material positioning; excision of previous scar; herniation was encountered in the subcutaneous tissue; the sac had multiple opening, "swiss cheese" like. The sac was mobilized and incised. The abdominal wall defect was of 15 cm. The sac was closed with continue suture. Internal and external oblique muscle - fascial plane was anatomically prepared.

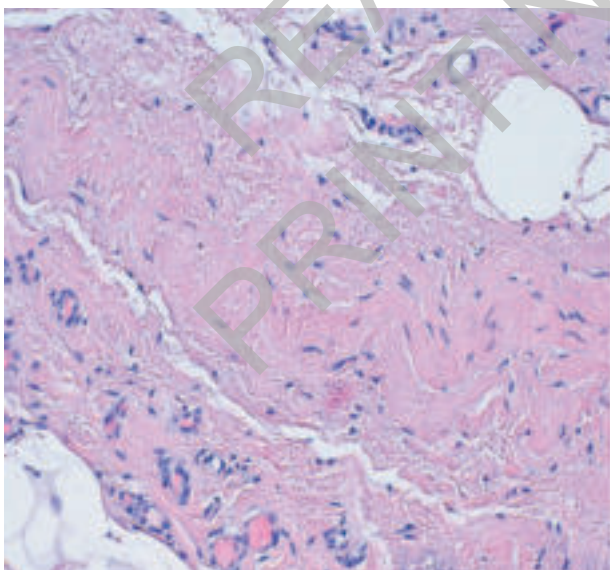
Polypropylene mesh was positioned (DM 25 cm, 2.5 cm overlap), fixed at the inguinal ligament and at the con-

joint tendon. Muscle-fascial plane of internal and external oblique muscle was sutured and then the skin. The patient was discharged with diagnosis of "incisional hernia upon McBurney incision L3W3N3R0P1S0 Chevrel classification".

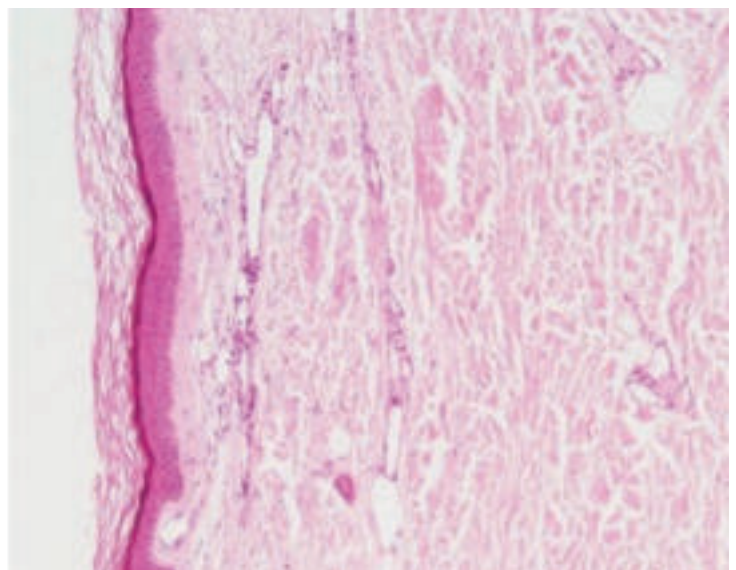
No postoperative complications occurred. Discharge occurred in 2nd post-operative day. Clinical conditions and surgical outcome was considered good. No signs of infection or other complications during the follow-up were noted. Sutures were cut off in 15th day after operation. After 11 months, signs of recurrence were objectivable both clinically and radiologically, and so that he underwent again surgical operation for plastic of abdominal wall with removal of the old prosthesis and positioning of a new one: excision of previous scar; previous prosthesis seemed displaced laterally. The abdominal wall defect was of 10 cm. The sac was mobilized and incised. Internal and external oblique muscle-fascial plane was anatomically prepared. Dual-mesh Parietex prosthesis was positioned (DM 20 x 25 cm, 3 cm overlap), fixed in the circumference. The sac was closed with continue suture. Muscle - fascial plane of internal and external oblique muscle was sutured and then the skin.

Discharge occurred on 2nd day after operation with diagnosis of "relapsed incisional hernia upon McBurney incision L3W3N3R1P1S0 Chevrel classification". No postoperative complications occurred. Clinical conditions and surgical outcome was considered good. No signs of infection or other complication during the follow-up were noted. Suture was cut off in 15th day after operation.

At present we are at 6th month after surgical operation and no signs of surgical complications nor relapse seem to be present.



Case Tissue H-E ob 20x



Control Tissue H-E ob 10x

Fig. 1: Haematoxylin/eosin stain.

Discussion and Conclusion

We presented the rare case of a young man that after surgical operation for acute phlegmonous appendicitis and McBurney incision, developed not only an incisional hernia (after seven years from the operation) treated surgically with positioning of polypropylene prosthesis, like many accepted data suggest¹⁰⁻¹⁴, but also the relapse of the same one. It is a really rare condition according to scientific literature^{4-7, 11}. In order to better understand the conditions that could had determine this rare event we analysed the most common risk factors that could justify the case reviewing the literature⁴; surely the diagnosis of "phlegmonous appendicitis" represents the main factor that could have determine the hernia being negative the comparison with the other common risk factors⁴ listed above. According to the evidence that wound-related risk factors including abnormal collagen metabolism is implicated in the development of incisional hernia^{10, 15-17} we wanted to investigate the histological pattern protein expression through OM observation after specific preparation of tissue samples formalin-fixed. During surgical operation for relapse of the incisional hernia we took samples of fascial tissue and peri-prosthetic tissue and according to Pathological Division we analysed it.

There were performed specific tissue preparations such as haematoxylin/eosin stain (Fig. 1), Gomori's trichrome stain (Fig. 2) and Masson's trichrome stain (Fig. 3) for collagen, reticulin and elastin fibres. We found that the disposition of reticulin fibres was uncommon: instead of a reticular disposition they had a point-source disposition. This could correlate with a lot of consequences

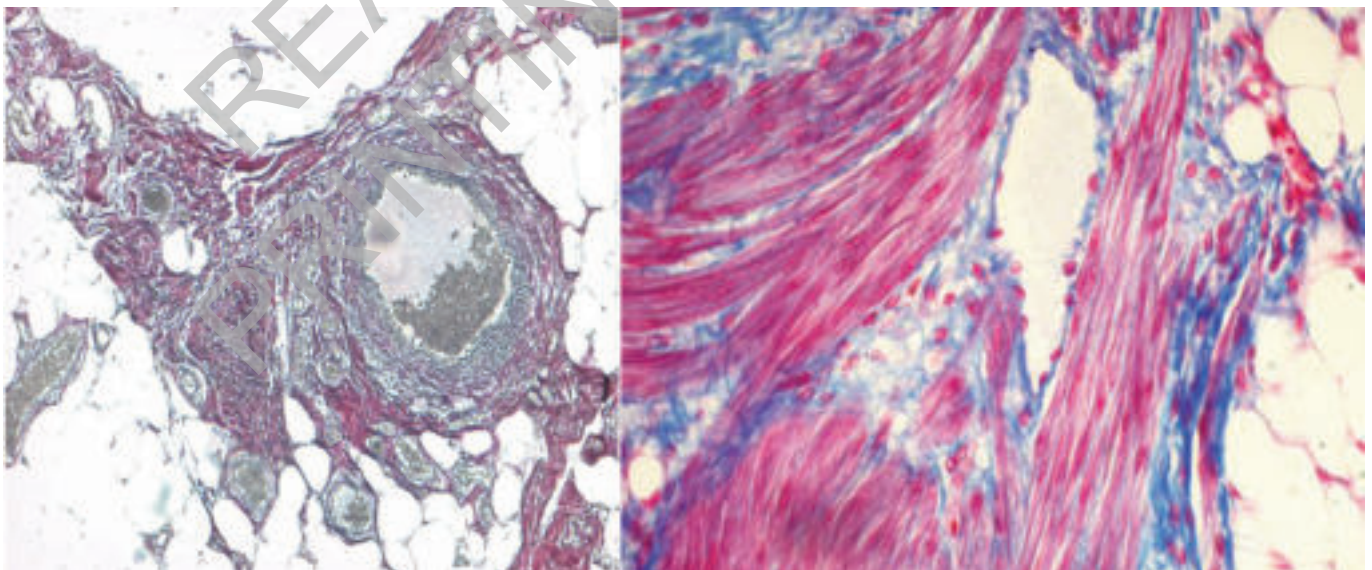
such as a minor resistance of abdominal wall to distribution of tensions throughout the wound creating abnormal forces on the tissues involved; a not organized matrix were to ensure a correct deposition of extracellular components; a not correct implantation of polypropylene prosthesis in abdominal wall and so the unique evolution of surgical operations mentioned, justifying the cause of the develop of incisional hernia in a rare and uncommon condition (male, young, no comorbidities) and the recurrence of the same one.

In order to continue to investigate upon this rare condition, supported from the pathological data, we searched for possible expression of auto-Antibodies, analysing standard pattern of 1st level investigation on serum sample. As shown in the table below (Tab. I) we noted the positivity to anti-Transglutaminase IgA and ASMA test, even though these results seem to be poor of meaning if correlated to the negative results of the other one tests.

A review of the international literature allowed to ascertain the poorness of data moved in the direction proposed by the observations listed, with likewise poor possibility to compare and give them absolute comprehension; further studies need to be set. Important, innovative and inspiring considerations risen from this case report.

Riassunto

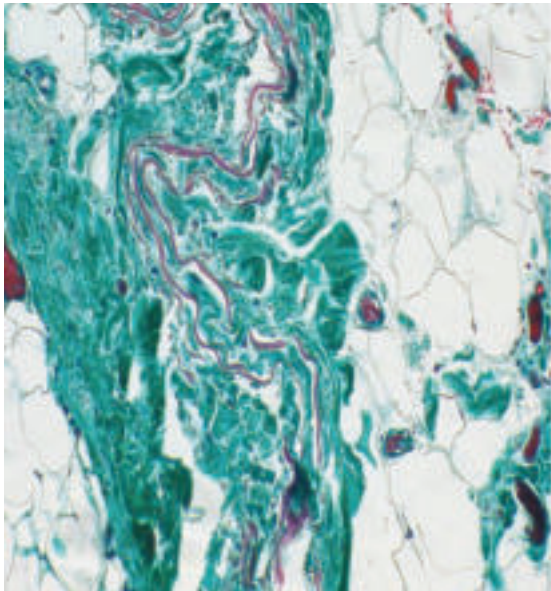
Il verificarsi di un laparocelo su incisione chirurgica sec. McBurney è un evento piuttosto raro che in letteratura trova una incidenza inferiore al 2%, giustificato da diversi fattori, soprattutto anatomici. Tale circostanza risulta



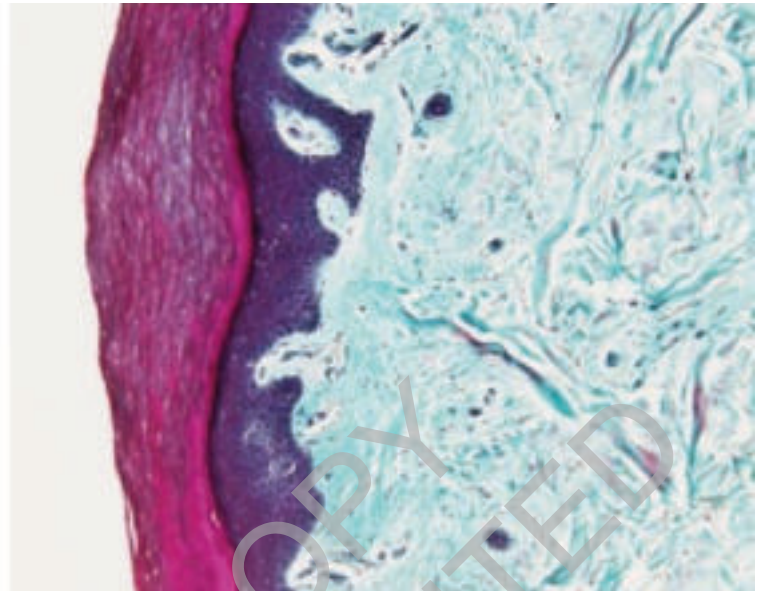
Case Tissue Gomori's stain ob 10x

Control Tissue Gomori's stain ob 20x

Fig. 2: Gomori's trichrome stain.



Case Tissue Masson's stain ob 10x



Control Tissue Masson's stain ob 10x

Fig. 3: Masson's trichrome stain.

TABLE I - Investigation upon auto-Ab expression.

Test	Results	Normal Value
Anti-Endomysium ¹ IgA	Neg	Neg
Anti-Transglutaminase ² IgA	23,15	< 20 UR/ml
Anti-Transglutaminase ³ IgG	< 1	< 1
Anti-Gliadin ⁴ IgA	10,80	< 25 UR/ml
Anti-Gliadin ⁴ IgG	2,11	< 25 UR/ml
ANA ⁵	Neg	Neg
AMA ⁶	Neg	Neg
ASMA ⁶	Pos	Neg
LKM ⁶	Neg	Neg
APCA ⁶	Neg	Neg

¹Indirect immunofluorescence test. Substrate: Oesophagus monkey cells. Dilution 1:10

²Immunoenzymatic test. Chromogenic substrate.

³Immunoenzymatic test. Chromogenic substrate. Semi-quantitative results expressed as Ratio.

⁴Immunoenzymatic test. Chromogenic substrate. Antibodies anti deamidated gliadin.

⁵Indirect immunofluorescence test. Substrate: Hep-2 cells. (Positive if dilution 1:160)

⁶Indirect immunofluorescence test. (Positive if dilution 1:40)

spesso correlata alla co-presenza di svariati "fattori di rischio" quali diabete, sesso femminile, peritonite/ascesso/appendice flemmonosa al momento dell'intervento chirurgico, infezioni della ferita chirurgica, formazione di sieromi, e altri fattori anatomici e/o istologici computati nella letteratura internazionale in quanto fattori comuni al determinarsi di "ernia su incisione". Se

rara può essere considerata la comparsa di laparocoele su McBurney, ancor di più lo è la sua recidiva.

Abbiamo voluto presentare questo raro caso di laparocoele su Mc Burney e sua recidiva, per una serie di motivazioni: la rarità del caso in sé, considerando il background nello specifico (paziente giovane, maschio, non comorbilità); i dettagli istologici rinvenuti all'osservazione al MO di campioni tissutali prelevati al momento del reintervento per recidiva di laparocoele, che hanno rilevato la particolare distribuzione puntiforme delle fibre di reticolina piuttosto che la sua classica distribuzione fibrillare, e le evidenze (seppur poco rilevanti sul piano diagnostico vista la tendente negatività delle indagini eseguite ma certamente intuitive sul piano teorico-investigativo) messe alla luce dalla ricerca auto-anticorpale sul siero del paziente, movente per un eventuale stretto follow-up clinico in merito alle possibili ed immaginabili conseguenze ad esse connesse.

References

1. Kingsnorth A, LeBlanc K: *Hernias: Inguinal and incisional*. Lancet, 2003; 362:1561-571.
2. Cassar K, Munro A: *Surgical treatment of incisional hernia*. Br J Surg, 2002; 89:534-45.
3. Korenkov M, Paul A, Sauerland S, et al.: *Classification and surgical treatment of incisional hernia: Results of an experts meeting*. Langenbeck's Arch Surg, 2001; 386:65-73.
4. Beltran MA, Cruces KS: *Incisional Hernia after McBurney Incision: Retrospective Case-control Study of Risk Factors and Surgical Treatment*. World J Surg, 2008; 32:596-601.

5. Hsiao WC, Young KC, Wang ST, et al.: *Incisional hernia after laparotomy: prospective randomized comparison between early-absorbable and late-absorbable suture materials*. World J Surg, 2000; 24:747-52.
6. Chan G, Chan CK: *A review of incisional hernia repairs: Preoperative weight loss and selective use of the mesh repair*. Hernia, 2005; 9:37-41.
7. Ohana G, Bramnik Z, Miller A, et al.: *Treatment of large incisional abdominal wall hernias, using a modified preperitoneal prosthetic mesh repair*. Hernia, 2006; 10:232-35.
8. Burger JWA, Lange JF, Halm JA, et al.: *Incisional hernia: Early complication of abdominal surgery*. World J Surg, 2005; 29:1608-613.
9. Pollock AV, Evans M: *Early prediction of late incisional hernia*. Br J Surg, 1989; 76:953-54.
10. Luijendijk RW, Hop WCJ, Van Den Tol P, et al.: *A comparison of suture repair with mesh repair for incisional hernia*. N Engl J Med, 2000; 343:392-98.
11. Konstantakos AK, Zollinger RM: *Repair of McBurney incisional hernias after open appendectomy*. Curr Surg, 2000; 57:79-80.
12. Burger JWA, Luijendijk RW, Hop WCJ, et al.: *Long-term follow-up of a randomized controlled trial of suture versus mesh repair of incisional hernia*. Ann Surg, 2004; 240:578-85.
13. Schumpelick V, Klinge U, Junge K, et al.: *Incisional abdominal hernia: The open mesh repair*. Langenbeck's Arch Surg, 2004; 389:1-5.
14. Sauerland S, Schmedt CG, Lein S, et al.: *Primary incisional hernia repair with or without polypropylene mesh: A report on 384 patients with a 5-year follow-up*. Langenbeck's Arch Surg, 2005; 390:408-12.
15. Yahchouchy-Chouillard E, Aura T, Picone O, et al.: *Incisional hernias: Related risk factors*. Dig Surg, 2003; 20:3-9.
16. Langer C, Schaper A, Liersch T, et al.: *Prognosis factors in incisional hernia surgery: 25 years of experience*. Hernia, 2005; 9:16-21.
17. Goldstein SL: *Mechanisms and metabolic characteristics of hernia formation*. Prob Gen Surg, 2002; 19:1-6.

READ-ONLY COPY
PRINTING PROHIBITED