

# Common hepatic artery quadrifurcation associated with right hepatic artery from superior mesenteric artery during laparoscopic total splenopancreasectomy



Ann Ital Chir, 2016 88, 4: 365-367

pii: S0003469X17027245

Epub Ahead of Print - June 12

free reading: www.annitalchir.com

Francesco Caruso\*, Giorgio Alessandri\*\*, Francesca Ciccarese\*, Giovanni Cesana\*, Matteo Uccelli\*, Giorgio Castello\*, Roberta Villa\*, Stefano Olmi\*

\*Department of General and Oncologic Surgery, Centre of Laparoscopic and Bariatric Surgery, Istituti Ospedalieri Bergamaschi, Policlinico San Marco, Zingonia, Osio Sotto (BG), Italy

\*\*Freeman Hospital, Department of Surgery, The Newcastle upon Tyne Hospitals. NHS Foundation Trust, UK

Common hepatic artery quadrifurcation associated with right hepatic artery from superior mesenteric artery during laparoscopic total splenopancreasectomy

*Hepatobiliopancreatic surgery is challenging because of the complexity of resections and reconstructions and variability of vascular anatomy. The arterial vascularization of the liver is sustained by the common hepatic artery (CHA) that originates from the celiac trunk (CT). The CHA bifurcates into the gastroduodenal artery (GDA) and proper hepatic artery (PHA) 0.5-1 cm medial to the common bile duct (CBD), and the PHA bifurcates into a right and a left branch at hepatic hilum. The most frequent variants are the right hepatic artery (RHA) from the superior mesenteric artery (SMA), the left hepatic artery (LHA) from the left gastric artery (LGA) or a combination of these two variants. Herein, we describe the case of a 70 years old woman affected by IPMN of the pancreas with a quadrifurcation of CHA, associated with a RHA off the SMA.*

KEY WORDS: Anatomic variant Hepatic artery variant, Hepatic anatomy, Hepatic vascular anatomy

## Introduction

Hepatobiliopancreatic (HPB) represents a technically challenging sub-speciality of general surgery. Complex resections, laborious anastomosis and a variable vascular anatomy are well known aspects of the HPB procedures. The arterial supply of the liver is characterized by the common hepatic artery (CHA) that originates from the

celiac trunk (CT). The CHA divides into the gastroduodenal artery (GDA) and the proper hepatic artery (PHA) 0.5-1 cm medial to the common bile duct (CBD), the PHA bifurcates into the right and the left branch at hepatic hilum. The commonest variants of this vascular anatomy are: a right hepatic artery (RHA) originates from the superior mesenteric artery (SMA) or a left hepatic artery (LHA) from the left gastric artery (LGA) <sup>3</sup>. Herein, we report the case of a 70 years old woman with an intra-ductal papillary mucinous neoplasm (IPMN) of the pancreas who appeared to have an uncommon vascular anatomy of the liver; a quadrifurcation of CHA associated with a RHA branching off the SMA.

Pervenuto in Redazione Febbraio 2017. Accettato per la pubblicazione Maggio 2017

Correspondence to: Francesco Caruso, M.D., Department of General and Oncologic Surgery, Centre of Laparoscopic and Bariatric Surgery, Istituti Ospedalieri Bergamaschi, Policlinico San Marco, 24040 Zingonia-Osio Sotto (BG), Italy. (e-mail: alessandrofrancescocaruso@yahoo.it)

## Case report

In October 2016 a 70 years old woman was referred to our surgical unit, specialized in minimal invasive proce-

## ABBREVIATIONS

CHA Common hepatic artery; RHA Right hepatic artery; LHA Left hepatic artery; LGA Left gastric artery; CT Celiac trunk; SMA Superior mesenteric artery; PV Portal vein; CBD Common bile duct

ture and based into the tertiary centre, San Marco hospital (Zingonia, Osio Sotto – BG). The patient presented with a main duct (MD) IMPN of the head of the pancreas and brunch duct IPMNs of body and tail. The lesion of the head, communicating with the main pancreatic duct (PD), was 3,7 cm with a thickened wall. In the body and tail of the pancreas there were several sub-centimetric brunch type IPMN. Once referred to our unit, the patient had a full preoperative assessment with blood tests (including tumour markers), CT chest abdomen pelvis, MRI pancreas and an endoscopic ultrasound (EUS) with fine needle aspiration (FNA). This was performed to assess the cytology of the cystic lesion of the head of the pancreas, measuring the level of the CEA and the presence of mucin into the fluid contained by the IPMN of the head. All the investigations performed confirmed the diagnosis of mixed IPMN without any evidence of systemic disease. As per Fukuoka guidelines <sup>6</sup>, a laparoscopic total pancreatectomy and splenectomy were proposed to the patient and then were performed. Interestingly the preoperative CT identified a RHA originating from the SMA. During the lymphadenectomy of the hepatic pedicle an unusual anatomy of the CHA was highlighted. Four branches originated from the CHA (quadrifurcation), 0,5 cm medial-

ly to the CBD. Two of them were pointing upward, running on the left side of the CBD and going towards the liver. Two of them were orientated downward, toward the pancreaticoduodenal groove. The CHA was 1,0 cm in diameter, the 4 branches were between 0.2 and 0.3 cm. During the operation the RHA was identified on the right side of the portal vein, originating from the SMA, as detected by the CT scan. It was 0.6 cm in diameter. A LHA originating from the LGA was sought but not identified. During the surgical procedure no vascular resections neither intraoperative complications were recorded. The patient was discharged on postoperative day 8 after an uneventful recovery.

## Discussion

Variants of the hepatic arteries are one of the most common vascular variations reported in literature. In 1955, Michel <sup>3</sup> described the first classification of uncommon presentation of hepatic arteries, that was renewed in 1962 <sup>4</sup>. This paper was based on data obtained by the dissection of 200 cadavers. A more recent classification was published in 1994 by Hiatt et al <sup>2</sup>. The preoperative study of the vascular anatomy of the liver and pancreas has a primary role in HPB surgery. The CHA originates from the celiac trunk (CT) bifurcating into a right and a left branch, in 51-85.1 % of cases <sup>1</sup>. In a recent review of the literature we presented the incidence of the different vascular variation of the hepatic arteries. A right hepatic artery (RHA) arising from the superior mesenteric artery (SMA) was observed in 6.3-21 % of the patients who undergo to HPB surgery. A left hepatic artery (LHA) branches off from the left gastric artery (LGA) in 3-18 % of the cases. A combination of these two variants appears in up to 7.4 % of the cases <sup>1</sup>. The quadrifurcation of CHA has previously been described by Sureka et al. in 2013, who reported an incidence of

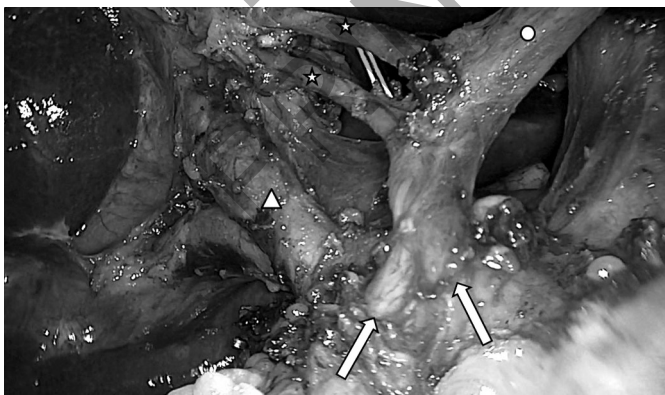

Fig. 1: Laparoscopic lymphadenectomy of the hepatic hilum. White circle: common hepatic artery. White arrows: Duodenopancreatic arteries. White stars: hepatic branches of common hepatic artery. White triangle: common bile duct.

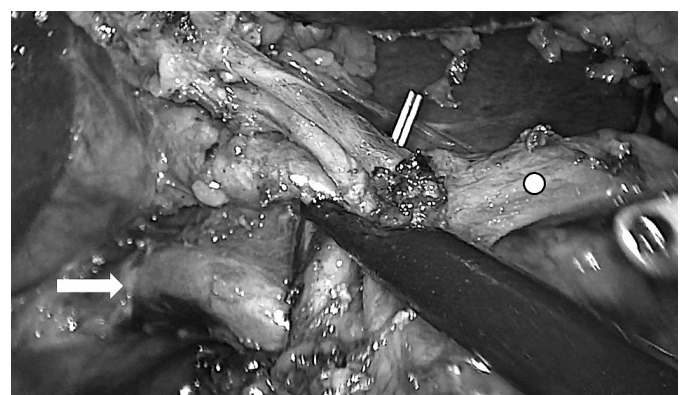


Fig. 2: Laparoscopic lymphadenectomy of the hepatic hilum. White arrow: Right Hepatic Artery. White circle: Common hepatic artery.

2,16%. In this article the path of the 4 hepatic arteries was not further specified and it was not clear if they were associated with other vascular anomalies<sup>5</sup>. In our case CHA quadrifurcation was associated with a RHA originating from SMA. The RHA was 0.6 cm in diameter, while the hepatic branches of CHA were between 0.2 and 0.3 cm. The RHA was initially within the retroportal lamina, at the level of splenomesenteric confluence it moved laterally on the posterior surface of the portal vein. The RHA became then further lateral reaching the right aspect of the portal vein, where it remained until it reached the liver. No branches were identified along its route. During all steps of the pancreatic resection particular attention was paid to preserve the RHA and maintain the integrity of all arterial supply of the liver.

## Conclusion

In HPB a careful preoperative assessment, embracing good quality cross section imaging is vital in the process of planning an appropriate operation. An accurate surgical dissection is the keystone to recognize variations of the common anatomy and to avoid intraoperative vascular complications.

## Acknowledgments

The authors thank Benedetta Furguele for his contribution.

## References

1. Caruso F, Dondossola D, Fornoni G, Caccamo L, Rossi G: *Right hepatic artery from splenic artery: The four-leaf clover of hepatic surgery*. Surg Radiol Anat, 2016; 38(7):867-71.
2. Hiatt JR, Gabbay J, Busuttil RW: *Surgical anatomy of the hepatic arteries in 1000 cases*. Ann Surg, 220:50-52
3. Michels NA: *Blood supply and anatomy of the upper abdominal organs with a descriptive atlas*. Philadelphia, Pa: Lippincott, 1955.
4. Michels NA: *Newer anatomy of the liver and its variant blood supply and collateral circulation*. Am J Surg, 1962; 12:337-34
5. Sureka B, Mittal MK, Mittal A, Sinha M, Bhambri NK, Thukral BB: *Variations of celiac axis, common hepatic artery and its branches in 600 patients*. Indian J Radiol Imaging, 2013; 23(3):223-33.
6. Tanaka M, Fernández-del Castillo C, Adsay V, et al: *International consensus guidelines 2012 for the management of IPMN and MCN of the pancreas*. Pancreatolgy, 2012; 12:183-97.