

Percutaneous treatment with radiofrequency ablation of varicose veins recurring after vein stripping surgery

A preliminary study



Ann. Ital. Chir., 2017 88, 5: 438-442
pii: S0003469X17027725

Giovanni Turtulici*, Ermenegildo Furino**, Giorgia Dedone*, Riccardo Sartoris*, Jeries Zawaideh*, Aldo Fischetti*, Enzo Silvestri*, Gennaro Quarto**

*International Evangelical Hospital, Genoa, Italy.

**Clinical Medicine and Surgery Department, "Federico II" University, Naples, Italy

Percutaneous treatment with radiofrequency ablation of varicose veins recurring after vein stripping surgery. A preliminary study

AIM: The aim of our study was to evaluate the efficacy of a new treatment of recurrent varicose vein after stripping of the great saphenous vein with rigid radiofrequency needles.

MATERIAL OF STUDY: 37 patients enrolled (11 males and 26 females). 10 patients had recurrent varicose veins for the presence of residual reflux in the Saphenous-Femoral Junction (SFJ) stump, whilst 21 patients for the presence of a single or multiple re-chanalized and refluxing perforator veins, and 6 had mixed rechannelization due to perforator veins and refluxing saphenous stump.

All patients have been treated by percutaneous ultrasound-guided obliteration with radiofrequency needles. Treatment efficacy have been assessed by US evaluation, and/or the appearance of recurrent varicose veins and classified as REVAS questionnaire. Follow up has been carried out at 30, 60, 180 days and 1 year after treatment.

RESULTS: A complete obliteration of the perforator(s) stump(s) was observed in 12 procedures immediately after the treatment, and confirmed at 30 and 60 days. In 1 case (7.69 %) obliteration was not complete at 60 days. After 1 year of follow-up 3 perforators (23.07%) showed an incomplete or failed obliteration. A complete obliteration of the treated SFJ was observed in 27 cases at the end of the procedure and confirmed after 60 days of follow-up patients (Fig. 4). In 2 cases (6.89%), obliteration was non complete at 60 days. After 1 year of follow up 5 treated SFJ (17.24%) stumps showed an incomplete or a failed obliteration.

DISCUSSION: Results show a reduction of the number of limbs affected by ulcer, skin pigmentation and stasis eczema, demonstrating correction of haemodynamic overload to be effective.

CONCLUSIONS: This treatment is a new and effective solution to the problem of post-stripping recurrent varicose veins.

KEY WORDS: Perforator veins, Radiofrequency, Recurrent post-stripping varicose veins, Saphenofemoral stump

Introduction

Venous disease, including varicose veins, is one of the most commonly reported chronic medical conditions and a substantial source of morbidity in the United States.

Estimates of the prevalence vary widely from 12% to 40% in men and 25% to 73% in women. In the United Kingdom, almost 90000 operations are performed per year. Recurrences are common, and vary according to different case histories, up to 70% at 10 years. REVAS study reports that the recurrences are 6,6%-37% at two years, >51% at 5 years. The risk of recurrence is lower when the treatment is performed by specialized vascular surgeons¹⁻⁷. Even when performed by expert vascular surgeons, the recurrence after surgery, with open groin access, is usually caused by neovascularization. The endovascular procedures without open groin access can

Pervenuto in Redazione Luglio 2017. Accettato per la pubblicazione Settembre 2017

Correspondence to: Dr. Giovanni Turtulici, Interventional US Unit, International Evangelic Hospital, Genoa, Corso Solferino, 1A, Genova, Italy (gianni.turtulici@gmail.com; er.furino@gmail.com)




Fig. 1: HS radiofrequency rigid needle.

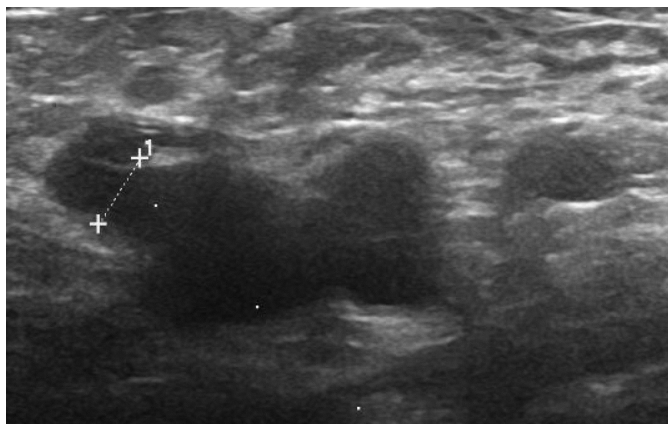


Fig. 2: Residual incompetent cross-stump.

reduce the development of this complication^{8,9}. The risk of recurrence is lower when varicose veins are treated with sclerotherapy and all endoluminal treatments¹⁰. The causes of recurrences are various. The two main causes, about 60% of all¹, are the post-stripping rehabilitation and reflux due to reflux perforator veins¹¹ and residual reflux in the saphenous vein cross-stump. We know that saphenous-femoral junction (SFJ) is like a perforator vein¹⁻³.

Our study focused on this two causes of recurrence which are remarkable from the point of view of therapeutic options. Among the treatment options the most common are surgical revision and sclerotherapy¹². A possible thermal solution is represented, in our opinion, by the radiofrequency rigid needle (Fig. 1).

The hemodynamic rationale of this treatment is to close, using an endovascular radiofrequency needle, the point of supply of the recurrent varicose veins after stripping. The purpose of this study is to verify the feasibility of this solution in patients previously subjected to surgical procedure presenting varicose vein recurrences mainly due to rechanneled perforator veins and to residual incompetent cross-stump (Fig. 2).

Our technique stems from thyroid and liver nodules treatment with rigid needle and consists in percutaneous vein cannulation which is performed in a perpendicular fashion, for a maximum extension of 2 cm. The most effective advantage is just the perpendicular modality which best fits to the typical direction of perforator veins,

granting a better obliteration of the point of supply of a varicose vein recurrence. The effectiveness of this technique is based on a scrupulous and accurate pre-procedural echocolordoppler-assisted mapping of supply points and haemodynamic shunts¹³.

Materials and Methods

From January 2014 to December 2016, 37 outpatients, for a total of 37 limbs treated (when a patient presented bilaterally a recurrence, only the most symptomatic limb has been treated) 25 females (67.56%) and 12 males (32.44%), mean age 47.39 ± 7.38 years have been selected on the basis of a clinical examination coupled to an ultrasound evaluation performed at the International Evangelical Hospital, Genoa, Italy. All patients were symptomatic for varicose vein recurrence. A patient/affected limbs stratification according to CEAP C has been carried out. Recurrence types have been analyzed using REVAS questionnaire. Lower limb disease spreaded from CEAP C3-C6 classes (Table IV). Only patients previously subjected to traditional surgery of Great Saphenous Vein (GSV) (only one time before) have been enrolled.

TABLE I - Topography (due to the contemporary presence of multiple recurrent varices, the total number of limbs is greater than the one of the treated limbs)

	N. of Limbs	%
Groin	18	46.15
Thigh	15	38.46
Lower leg	6	15.39

TABLE II - Source (since more than one territory may be involved, the total number of limbs is greater of the one of the treated limbs).

	N. of Limbs	%
SFJ	24	57.14
Pelvic	5	11.91
Thigh	13	30.95
Popliteal Perf.	0	0
No-one	0	0

TABLE III - Nature of source

	N. of Limbs	%
Technical Failure	4	10.81
Tactic Failure	15	40.54
Neovascularization	6	16.22
Uncertain	3	8.11
Mixed	9	24.32

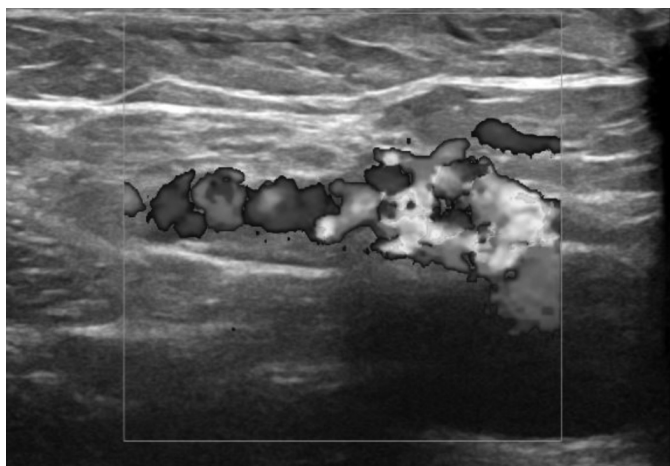


Fig. 3: Color Doppler evaluation residual incompetent cross-stump.

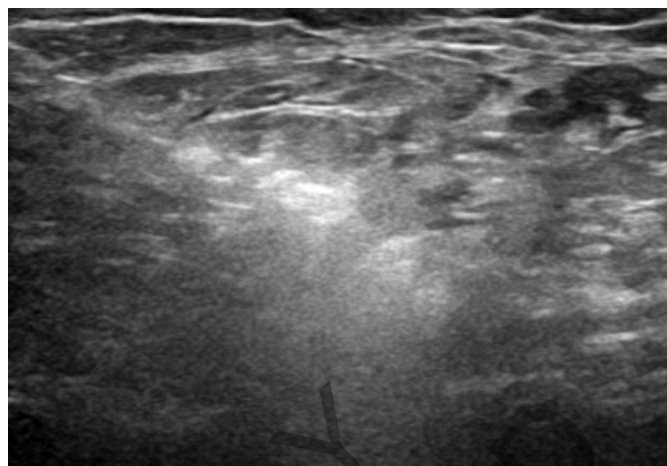


Fig. 4: Percutaneous vein RF ablation in activity - microbubbles.

The recurrences analysis according to REVAS questionnaire are reported in the Tables I, II and III.

Patients were treated by percutaneous ultrasound-guided radiofrequency needle (Fig. 1). All patients signed a written consent to the execution of the treatment, after accurate informations about the purposes of the treatment. The procedure has been authorized by institution ethical committee. After a preoperative ultrasound mapping, the patients were treated. For the study it has been used a radiofrequency monopolar, uncooled, rigid needle coupled to a radiofrequency generator, produced by HS® (Fig. 1). The needles used have a diameter of 16G, a length of 10 cm with the portion of exposed tip of 1 cm.

With the patients placed in supine position, via ultrasound guide, after local anesthesia (2% lidocaine 10 cc + Sodium Bicarbonate 10 mEq/10 ml 2cc), we introduce the needle through the skin without incision, into the vessel lumen, stopping one centimeter before the entrance of the deep circulation. After insertion of the needle inside the lumen of the vessel, we perform the infusion (US guided) of tumescent solution around the SFJ stump or perforator (physiological NaCl 500cc + lidocaine 2% 20 cc + sodium bicarbonate 10mEq/10 ml 10 cc) through a 22G needle, with the aim to protect from heat the tissues surrounding the vessel and to reduce the pain for the patient. After this, is possible to start the delivery of radiofrequency, with the aim of collapsing the vessel (Fig. 4). The delivery of the radiofrequency had an average duration of 20 seconds, in most cases limited by the onset of pain, with an average power of 60W. The delivery was controlled by impedance around the tip of the needle, which increased with the tissues warming. The sudden rise of impedance, due to the carbonization of the tissue, imposed the interruption of the delivery. We perform one delivery with the tip of the needle kept in position, one centimeter before entrance of the deep circulation. After this we check the

TABLE IV - Classification of the limbs according to CEAP C Classification

	N. (pre-procedural)	%	N. (Post-procedural)	%
CEAP C0	0	0	0	0
CEAP C1	0	0	11	29.73
CEAP C2	9	24.32	3	8.11
CEAP C3	7	18.92	4	10.81
CEAP C4a	6	16.22	4	10.81
CEAP C4b	5	13.51	5	13.51
CEAP C5	6	16.22	8	21.62
CEAP C6	4	10.81	2	5.41

collapsing using color doppler technique. If necessary is possible to perform a second erogation. When the collapse is obtained, the needle is extracted and the treatment is complete.

After procedure patients worn a double layer compression system, which consisted of two stockings: an anti-thrombotic post-op 18 mmHg stocking to which is overlapped a 1st class 18-21 mmHg compression stockings. Liquid or foam sclerotherapy treatment of residual varices is performed in a second time, in case of an incomplete elimination of haemodynamic overload.

Results

37 limbs had been treated with the above technique. 25 limbs had previously treated with an GSV High Ligation (HL) and above knee stripping; 8 limbs had been treated with GSV HL and under knee stripping; 4 with HL and Muller phlebectomies. All limbs presented post-procedural symptomatic varices.

Complete results are showed in Table I, II, and III. Nineteen treated limbs showed a refluxing SFJ stump,

while 8 showed one or more refluxing perforator vein(s). A refluxing mixed SFJ-Perforator pattern has been found in 5 limbs. A refluxing mixed SFJ-Pelvic pattern has been showed in 5 limbs

A complete obliteration of the perforator(s) stump(s) was observed in 12 procedures immediately after the treatment, and confirmed at 30 and 60 days. In 1 case (7.69 %) obliteration was not complete at 60 days. After 1 year of follow-up 3 perforators (23.07%) showed an incomplete or failed obliteration.

A complete obliteration of the treated SFJ was observed in 27 cases at the end of the procedure and confirmed after 60 days of follow-up patients (Fig. 4). In 2 cases (6.89%), obliteration was non complete at 60 days. After 1 year of follow up 5 treated SFJ (17.24%) stumps showed an incomplete or a failed obliteration.

After 1 year follow-up there was a CEAP down-staging, (see table IV for complete results). In particular we have assisted in a CEAP C6 down-staging, passing from 10.81% to 5.41%, which testifies an effectiveness in terms of limb haemodynamic overload leading to ulcer healing. Moreover, an improvement due to overload reduction has been seen in the reduction of limbs classified in CEAP classes C3 (oedema) from 18.92% to 10.81% and C4a (eritema and haemosyderinic matting) which decreased of 8.1%. There had not been an improvement in C4b class (lipodermatosclerosis).

Discussion

The technique we are presenting stems from our experience in thyroid and liver nodules RF ablation and requires a maximum of 2 cm percutaneous cannulation of the vein, perpendicularly to the skin. This allows a precise obliteration of supply point, reducing or removing the haemodynamic overload which has caused varicose recurrence and/or new varicose vein born. This implies an accurate pre-procedural haemodynamic mapping, searching for supply points at the basis of venovenous shunts (Fig. 3). Once removed the haemodynamic overload, varicose vein recurrence can be treated with sclerotherapy technique.

Our technique, unlike Muller phlebectomy, presents certain advantages, requiring an outpatient setting, entailing an unique point of infiltration of anaesthetic drug in correspondance of supply point.

Post-op course is very easy and requires few hours of clinical observation. After this, patients can return to their daily occupations. Skin injuries and scars do not occur and it is repeatable.

Rigid needle RF combined with sclerotherapy, differently from the sclerotherapy alone (especially mousse sclerotherapy) is safer and gives the possibility to treat varicose vein and its supply point without any surgical ligation and any risk of deep vein circulation mousse migration.

The working temperature of rigid RF needle is lower than EVLA; moreover, perpendicular cannulation (more suitable, mostly in case of perforator veins treatment) avoids vein wall dissection, differently from Seldinger technique; impedance control is an indicator of perfect vein cannulation. The above advantages lower the learning curve and speed-up the procedure.

This treatment, in our opinion, is a possible solution in the approaching of recurrent varicose veins after surgery, incurred mainly for the residual reflux in the saphenous cross-stump and in perforator veins.

Rigid needle RF turns out to be more simple and less invasive than the traditional surgery. Results (reported in Table IV) show a reduction of the number of limbs affected by ulcer¹⁴, skin pigmentation and stasis eczema, demonstrating correction of haemodynamic overload to be effective. The saphenous stumps and perforator vein obliteration stability immediately after the procedure and after of 60 days follow-up was similar, whilst has been noted a minimal difference in long term results; in fact, after 1 year follow-up, saphenous stumps obliteration was more stable than the perforator veins one. This could be explained with the current higher pressure in perforators, especially the distal ones. The average recanalization after 1 year of follow up turns to be slightly higher than the clinical data reported in the literature rate^{15,16}; nevertheless the technique needs to be furtherly studied, especially as regards the choice of delivered energy and the delivering time.

Conclusions

Perforator veins and saphenous stump rigid RF needle ablation is an effective technique in the treatment of recurrent varicose veins after surgery, and it represents an adjunctive choice available to the surgeon, especially for the easiness and the precision in use, due to the vein cannulation technique which happens in a perpendicular fashion, more effective, anatomically speaking, especially for perforator veins, than traditional RF (saphenous stumps can considered perforator veins as well[17-19]). Anyway, further investigations about this technique and a comparison with RF and mousse sclerotherapy in the treatment of REVAS are necessary

References

1. Perrin MR, Labropoulos N, Leon LR jr.: *Presentation of the patient with recurrent varices after surgery (REVAS study)*. J Vasc Surg, 2006; 43(2):327-34.
2. Campbell WB, et al.: *Randomized and economic analysis of conservative and therapeutic interventions for varicose veins study. The outcome of varicose vein surgery at 10 years: Clinical findings, symptoms and patients satisfaction*. Ann R Coll Surg Engl, 2003; 85:52-57.

3. NICE Guidelines. The diagnosis and management of varicose veins. Issued, July 2013.
4. Versteeg MP, et al.: *The natural history of ultrasound-detected recurrence in the groin following saphenofemoral treatment for varicose veins*. J Vasc Surg Venous Lymphat Disord, 2016; 4(3):293-300.e2. doi: 10.1016/j.jvsv.2016.02.006.
5. van Rij AM, et al.: *Recurrence after varicose vein surgery: A prospective long-term clinical study with duplex ultrasound scanning and air plethysmography*. J Vasc Surg, 2003; 38(5):935-43.
6. Kjeld T, et al.: *Recurrence after surgery of varices in the region of the long saphenous vein*. Ugeskr Laeger, 2003; 165(31):3009-13.
7. Joseph N, et al.: *A multicenter review of epidemiology and management of varicose veins for national guidance*. Ann Med Surg (Lond). 2016.
8. Kaspar S, et al.: *Neovascularisation as a cause of recurrence after varicose veins operation*. Rozhl Chir, 2006; 85(8):399-403.
9. Kianifard B, et al.: *Radiofrequency ablation (VNUS closure) does not cause neo-vascularisation at the groin at one year: results of a case controlled study*. Surgeon, 2006; 4(2):71-4.
10. Murad MH, et al.: *A systematic review and meta-analysis of the treatments of varicose veins*. J Vasc Surg, 2011; 53(5 Suppl):49S-65S. doi: 10.1016/j.jvsv.2011.02.031.
11. Stücker M, et al.: *New concept: different types of insufficiency of the saphenofemoral junction identified by duplex as a chance for a more differentiated therapy of the great saphenous vein*. Phlebology. 2013; 28(5):268-74. doi: 10.1177/0268355513476215. Epub 2013 May 6.
12. Apperti M, Furino E, Sellitti A, Quarto G: *The use of transillumination as a rational approach to sclerotherapy and endovascular laser ablation of varices. Results in the use of an original instrument*. Ann Ital Chir, 2016; 87:396-99.
13. Sellitti A, Furino E, Nasto A, Di Filippo A, Sellitti ME, Apperti M, Quarto G: *Role of the haemodynamic mapping in varicose vein surgery of lower limbs*. Ann Ital Chir, 2016; 87:392-95.
14. Quarto G, Solimeno G, Furino E, Sivero L, Bucci L, Massa S, Benassai G, Apperti M: *"Difficult-to treat" ulcers management: use of pulse dose radiofrequency*. Ann Ital Chir, 2013.
15. Bush RG, Bush P, Flanagan J, Fritz R, Gueldner T, Koziarski J, McMullen K, Zumbro G: *Factors associated with recurrence of varicose veins after thermal ablation: results of the recurrent veins after thermal ablation study*. Scientific World Journal, 2014; 2014:505843. doi: 10.1155/2014/505843.
16. Quarto G, Amato B, Giani U, Benassai G, Gallinoro E, Apperti M, Furino E: *Comparison of traditional surgery and laser treatment of incontinent great saphenous vein. Results of a meta-Analysis*. Ann Ital Chir, 2016; 87:61-7.
17. Quarto G, Amato B, Benassai G, Apperti M, Sellitti A, Sivero L, Furino E: *Prophylactic GSV surgery in elderly candidates for hip or knee arthroplasty*. Open Med (Wars). 2016 Nov 19;11(1):471-76. doi: 10.1515/med-2016-0083. eCollection 2016.
18. Genovese G, Furino E, Quarto G: *Superficial epigastric vein sparing in the saphenous-femoral crosssection or in the closures of the saphena magna*. Ann Ital Chir, 2015; 86:383-85.
19. Cestaro G, Furino E, Solimeno G, Gentile M, Benassai G, Massa S, Quarto G: *The role of superficial epigastric vein sparing in the treatment of chronic venous disease: a retrospective study*. Acta Phlebol 2014 r;15(3):143-47.