



Laparoscopic resection of tailgut cysts: the size is not the issue



Ann. Ital. Chir.
Published online (EP) 3 November 2016
pii: S2239253X16025871
www.annitalchir.com

Giorgio Dalmonte*, Francesco Tartamella**, Maria Teresa Mita*, Giuseppina De Sario*,
Luigi Roncoroni***, Federico Marchesi°

*Formazione Specialistica in Chirurgia Generale, Facoltà di Medicina e Chirurgia, Università degli Studi di Parma

**Dottorando in Scienze Chirurgiche e Microbiologia Applicata, Università degli Studi di Parma

***Direttore Clinica Chirurgica e Terapia Chirurgica, Università degli Studi di Parma

°Ricercatore in Chirurgia Generale, Facoltà di Medicina e Chirurgia, Università degli Studi di Parma

Laparoscopic resection of tailgut cysts: the size is not the issue

INTRODUCTION: Tailgut cysts are rare retrorectal cystic lesions usually treated by surgical resection, even where asymptomatic, due to the risk of malignancy and recurrence. In the last 20 years, the laparoscopic abdominal approach has been gaining consensus for its better visualization of pelvic structures and minimal invasiveness.

CASE REPORT: We present the case of the biggest tailgut cysts managed laparoscopically reported so far.

DISCUSSION: Mostly asymptomatic, diagnosis of tailgut cysts is often fortuitous during routine examination. Their malignant transformation is estimated being 14.1% of cases. MRI is particularly indicated to lead the surgical approach, given its superior resolution in soft tissues and assessment of local invasion. Surgical resection is the therapy of choice, performed with different approaches: the laparoscopic abdominal technique, performed by surgeons with expertise in pelvic laparoscopic surgery, allows the best visualization of pelvic viscera with lesser morbidity. Due to rupture and seeding risks, the laparoscopic approach should not be performed if there is any suspicion of malignancy.

CONCLUSION: Our case substantiates safety and feasibility of laparoscopic tailgut cysts management, even of large-size cysts. Preoperative imaging is crucial to assess the possible malignancy of the lesion and, in that case, to perform a laparoscopic approach.

KEY WORDS: Laparoscopy, Retrorectal space, Tailgut Cyst

Introduction

Tailgut cysts, also known as retrorectal cystic hamartomas or mucus-secreting cysts, are cystic lesions of the retrorectal space originating from an incomplete regression of the embryonic hindgut^{1,2}. Even if asymptomatic, surgical resection is the therapy of choice for retrorectal

tumors due to the risk of malignant transformation and recurrence²⁻⁴. From among surgical approaches, in recent years laparoscopy has stood out for the advantages it gives in handling benign retrorectal tumors^{5,6}. We present the biggest tailgut cysts managed laparoscopically reported so far.

Case Report

A 75 year-old man, with a history of COPD and benign prostatic hypertrophy, presented with abdominal pain and pelvic compressive symptoms, including obstructed defecation, peripheral edema and urinary retention that required catheterization. A hypochoic pelvic mass was

Pervenuto in Redazione: Maggio 2016. Accettato per la pubblicazione Giugno 2016

Correspondence to: Dott. Giorgio Dalmonte, Medico in Formazione Specialistica in Chirurgia Generale, Facoltà di Medicina e Chirurgia, Università degli Studi di Parma (e-mail: g.dalmonte86@gmail.com)

discovered at ultrasound examination; MRI showed an 11x13x15 cm cystic mass with serous density, thin wall and without internal septa, located in the retroperitoneal presacral space (Fig. 1). The mass displaced the rectum, the bladder and the prostate anteriorly; no clear invasion of any surrounding organs was demonstrated. The radiologist attributed radiological aspects to a benign tailgut cyst. A laparoscopic 5-ports approach was performed. The mass was well encapsulated with a smooth surface, extended from the presacral space to the right retrorectal space, compressing the sigmoid colon and the rectum to the right pelvic area. The right presacral plane was accessed and the sigma and the rectum were anteriorly mobilized. The mass dissection was difficult due to strong adhesions to the pelvic muscles and the rectal wall, which were divided using harmonic scalpel (Fig. 2). In order to allow an easier caudal isolation and removal, the cyst was completely drained; cystic capsule was easily extracted through a 10 mm port (Fig. 3). An hydropneumatic test was performed to test rectal wall integrity. A drain was left in place. Post-operative hospital stay was regular and the patient was discharged on PO day VI. The specimen was represented by a cystic lesion with fibrous wall and smooth luminal surface. Histological findings classified the tumor as a retrorectal cystic hamartoma. At one year follow-up the patient was completely asymptomatic.

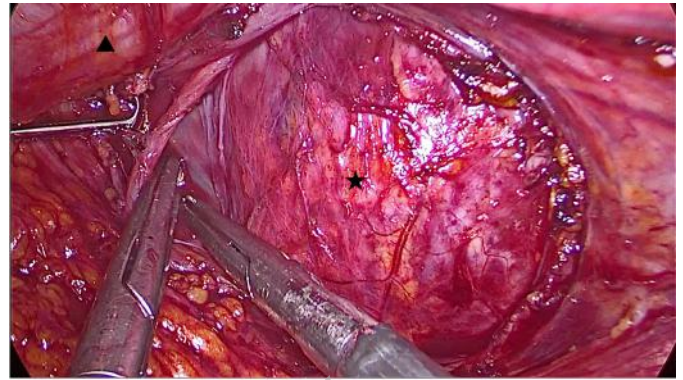


Fig. 2: Right presacral plane: cyst (black star) dissection from the rectum mobilized anteriorly (black triangle).

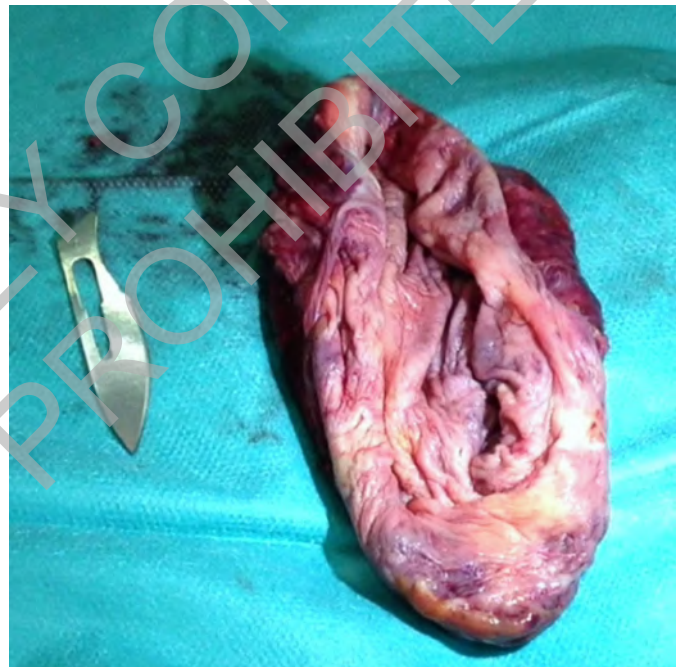

Fig. 3: Empty cyst capsule after extraction.

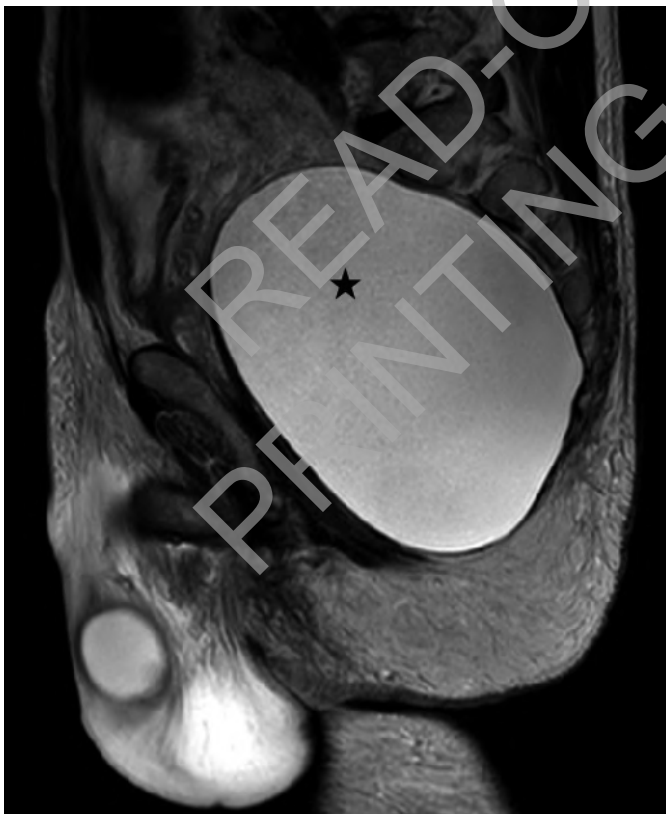

Fig. 1: RMI image of the tailgut cyst (black star).

Discussion

Retrorectal masses are generally classified into five categories: congenital, inflammatory, neurogenic, osseous and miscellaneous. The most common tumor type is represented by congenital ones, accounting for 55-70% of all presacral tumors, of which developmental cysts represent 60%⁴. The actual prevalence of retrorectal tumors is not known, since most remain clinically silent; the incidence rate is estimated as 1/40000 – 1/63000 admissions to large referral centers. Developmental cysts are more frequently diagnosed in middle-aged women (male: female ratio 1:2-1:5)^{2,4,7,8}.

These cysts can arise from any embryonic layer: tailgut cysts, described for the first time by Middeldorpf in 1885, are generally believed to originate from remnants of the embryonic postanal gut, which incompletely regresses during development^{1,4}. Histological findings for a tailgut cyst diagnosis are represented by a luminal surface of the cyst bearing an epithelial lining with transitional and/or columnar epithelium, with or without stratified squamous components and the absence of well-defined muscular layer, myenteric plexus and serosa^{4,7}. In their review of the literature, Akbulut et al. found malignant transformation of tailgut cysts on 47/332 (14.1%) patients⁴.

The diagnosis is mostly fortuitous, during routine examination, because often asymptomatic. Symptoms may be represented by change in bowel habit, rectal and lower abdominal pain, change in stool caliber, rectal fullness and dysuria. Recurrent retrorectal abscesses or pilonidal abscess can also disguise a retro-rectal^{4,9,10}. Digital examination can be helpful for the diagnosis of a retrorectal mass and useful to choose the surgical approach determining the proximal extent of the tumor². Exact pre-operative diagnosis being rare, a CT scan can discern solid from cystic mass and determine the upper limits of the lesion, while, due to its superior resolution in soft tissues, MRI is particularly indicated in staging local invasion and leading surgical technique: cystic structure and a thin wall are typically considered as benign features^{2,3,8,10,11}.

Fine-needle aspiration biopsy (FNAB) is not often performed, and not recommended, due to the risk of needle tract seeding, in case of malignant lesions, and of secondary infection in cystic ones^{2,3}. It is generally recommended only in unresectable and advanced-stage malignant tumors to assess adjuvant therapy^{4,12}. Thus the treatment is usually planned on the basis of radiological aspects set by an experienced radiologist^{12,13}.

Surgical resection is the treatment of choice in retrorectal tumors for the potential malignant degeneration and risk of recurrence^{2-4,12}. The surgical approach is based on tumor size, position and its benign or malignant appearance: posterior, anterior and combined abdominosacral approaches are currently described^{11,12}. The perineal approach is used for benign tumors that do not extend above the fourth sacral vertebra, the level usually reached by the examining finger, thus allowing to palpate the superior border of the tumor^{2,4,7}. The anterior approach, either by laparotomy or laparoscopy, is usually performed for masses not extending below the fourth sacral element. This approach has the advantage of better exposure of pelvic structures^{2,4}. The first reported laparoscopic procedure for a retrorectal tumor was performed in 1995 by Sharpe and co-workers¹⁴. Laparoscopic resection provides the best visualization of anatomy, granting deep access to the pelvis, combined with minimally invasive surgery, allowing lesser morbidity, better cosmetic results and shorter post-operative hos-

pital stay. To safely perform this technique, expertise in pelvic surgery is required to avoid injuries to the pelvic structures (vessels, nerves, ureters and rectum) and longer operating time should be considered. Due to the risk of rupture, in cystic lesions the laparoscopic approach should not be performed if there is any suspicion of malignancy^{5,6}. A combined abdominosacral approach is generally performed in case of large tumors with extension both above and below the fourth sacral vertebra^{2,4}.

Conclusions

Since its position makes retrorectal space difficult to access, laparoscopy, providing better exposure of pelvic structures, is gaining consensus to operate on this region. Like many others before, our case substantiates safety and feasibility of the laparoscopic approach for tailgut cysts management, even if the cyst size was considerable^{13,15}. However, this technique is not recommended in suspected malignant cases, since there is no literature on the oncological outcome in laparoscopic resection. Patients selection to rule out malignancy is therefore crucial and MRI is currently the preferred imaging technique to lead the surgical procedure^{3,11-13}.

Riassunto

Gli amartomi cistici retrorettali (Tailgut cysts) sono rare lesioni dello spazio presacrale che avendo rischio intrinseco di trasformazione maligna e recidiva sono normalmente trattate mediante asportazione chirurgica anche nel caso in cui siano asintomatiche. Negli ultimi vent'anni si sta affermando il trattamento mediante accesso addominale laparoscopico per la sua migliore esposizione delle strutture della pelvi e la sua minore invasività.

In questo caso clinico presentiamo il trattamento del più grande amartoma cistico retrorettale asportato laparoscopicamente fino ad ora riportato in letteratura.

Essendo nella maggior parte dei casi asintomatici, la diagnosi degli amartomi cistici retrorettali è spesso incidentale durante una visita medica di routine. Nel successivo studio è particolarmente indicata la RM per orientare la scelta dell'approccio chirurgico data la sua maggiore risoluzione nei tessuti molli e nella determinazione dell'invasività locale. La trasformazione maligna di queste lesioni si stima possa avvenire nel 14,1% dei casi, per questo l'exeresi chirurgica è la terapia di scelta. Tra i differenti approcci la tecnica transaddominale laparoscopica, se eseguita da chirurghi esperti nella chirurgia pelvica laparoscopica, garantisce la migliore visualizzazione degli organi pelvici e una minore morbilità. A causa del rischio di rottura e insembramento l'approccio laparoscopico non dovrebbe essere utilizzato in caso di sospetta malignità della lesione cistica.

Il nostro caso corrobora la validità del trattamento laparoscopico degli amartomi cistici retrorettali, anche quando possiedono dimensioni considerevoli. Lo studio preoperatorio è quindi cruciale per determinare la possibile malignità della lesione ed eseguire in tal caso un approccio laparotomico.

References

- 1 Au E, Anderson O, Morgan B, Alarcon L, George ML: *Tailgut cysts: Report of two cases*. Int J Colorectal Dis, 2009; 24:345-50.
- 2 Hobson KG, Ghaemmaghami V, Roe JP, Goodnight JE, Vijay PK: *Tumors of the retrorectal space*. Dis Colon Rectum, 2005; 48:1964-974.
- 3 Hopper L, Eglinton TW, Wakeman C, Dobbs BR, Dixon L, Frizelle FA: *Progress in the management of retrorectal tumours*. Colorectal Dis Published Online First: 14 September 2015. doi:10.1111/codi.13117
- 4 Akbulut S: *Unusual cause of defecation disturbance: A presacral tailgut cyst*. Eur Rev Med Pharmacol Sci, 2013; 17:1688-699.
- 5 Marinello FG, Targarona EM, Luppi CR-O, Boguñá I, Molet J, Trias M: *Laparoscopic approach to retrorectal tumors: Review of the literature and report of 4 cases*. Surg Laparosc Endosc Percutan Tech, 2011; 21:10-13.
- 6 Lu N-H, Tseng M-J: *Laparoscopic management of tailgut cyst: Case report and review of literature*. J Minim Invasive Gynecol, 2010; 17:802-04.
- 7 Gunkova P, Martinek L, Dostalík J, Gunka I: *Laparoscopic approach to retrorectal cyst*. World J Gastroenterol, 2008; 12:6581-583.
- 8 Glasgow SC, Birnbaum EH, Lowney JK, Fleshman JW, Kodner IJ, Mutch DG, et al.: *Retrorectal tumors: A diagnostic and therapeutic challenge*. Dis Colon Rectum, 2005; 48:1581-587.
- 9 Duclos J, Maggiori L, Zappa M, Ferron M, Panis Y: *Laparoscopic resection of retrorectal tumors: A feasibility study in 12 consecutive patients*. Surgical Endoscopy, 2014; 28:1223-229.
- 10 Cartanese C, Franco F, Guastadisegno C, Rosellini A, Minardi M: *Retrorectal multilocular cyst in a adult female. Case report and review of literature*. Ann Ital Chir, 2015; 86.
- 11 Reiter MJ, Schwoppe RB, Bui-Mansfield LT, Lisanti CJ, Glasgow SC: *Surgical management of retrorectal lesions: What the radiologist needs to know*. AJR Am J Roentgenol, 2015; 204:386-95.
- 12 Woodfield JC, Chalmers AG, Phillips N, Sagar PM: *Algorithms for the surgical management of retrorectal tumours*. Br J Surg, 2007; 95:214-21.
- 13 Fong SS, Codd R, Sagar PM: *Laparoscopic excision of retrorectal tumours*. Colorectal Dis, 2014; 16:O400-03.
- 14 Sharpe LA, Van Oppen DJ: *Laparoscopic removal of a benign pelvic retroperitoneal dermoid cyst*. J Am Assoc Gynecol Laparosc, 1995; 2:223-26.
- 15 Zhou JL, Wu B, Xiao Y, Lin GL, Wang WZ, Zhang GN, et al.: *A laparoscopic approach to benign retrorectal tumors*. Tech Coloproctol, 2014; 18:825-33.