

Gastroschisis with gastric perforation and jejunal stenosis

A rare association of anomalies



Ann. Ital. Chir., 2016 87: 263-267
pii: S2239253X16024865
www.annitalchir.com

Vesna Milojković Marinović*, Marija Lukač Lukač**, Željko Miković***, Blagoje Grujić*, Aleksandra Stojanović, Dalibor Sabbagh, Gordana Samardžija****

*Department for neonatal surgery, Institute for mother and child healthcare, Belgrade, Serbia

**Department for neonatal surgery, University children hospital, Belgrade, Serbia

***Obstetric/Gynecology Clinic Narodni Front, University of Belgrade, Belgrade, Serbia

****Department of pathology, Institute for mother and child healthcare, Belgrade, Serbia

Gastroschisis and gastric perforation and jejunal stenosis. A rare association of anomalies

AIM: *Gastroschisis with prenatal gastric perforation and intestinal stenosis is a rare and serious anomaly. although there are several case reports, no case series exists to suggest the prognosis for these infants.*

MATERIAL AND METHODS: *In this report a case of gastroschisis with gastric perforation and jejunal stenosis in male newborn is presented with literature review. The stomach, small bowel and the part of the colon were herniated through the abdominal wall defect. A large perforation site at the anterior wall of fundus and a thin fibrous strip that causing stenosis of jejunum was found.*

RESULTS: *Gastrostomy was performed. Stenosis of jejunum was resected and t-t anastomosis was performed, followed by primary fascial closure.*

DISCUSSION: *The prenatal sonographic finding of bowel or gastric perforation are variable. Antenatal bowel dilatation and in particular intraabdominal bowel dilatation is prognostically useful for detection of patients with worse outcome. The absence of bowel dilatation cannot fully exclude complex patients. Early restoration of bowel continuity using primary anastomosis and primary abdominal wall closure are not associated with prolonged time for full enteral feeding and length of hospital stay.*

CONCLUSIONS: *We have presented the first detailed report of surgical intervention and outcomes in case of gastroschisis with prenatal gastric perforation and congenital jejunal stenosis. Early restoration of bowel continuity using primary anastomosis and primary abdominal wall closure is recommended here. More research should be focused to predict complex gastroschisis and to improve prenatal diagnosis and postnatal management, without a significant increase in morbidity and mortality.*

KEY WORDS: Gastroschisis, Gastric perforation, Stenosis of jejunum

Introduction

Gastroschisis is a congenital anomaly with a reported mortality less than 10% in most published series¹. It has become clear that the presence of one or more intestinal complications, such as atresia, volvulus, necro-

sis, perforation, stenosis, places the patient in a high risk category and is associated with worse outcomes. Efforts have been made on identifying prenatal or perinatal predictors of outcome as well as factors that may be amenable to manipulation to improve outcomes.

Case experience

A 22 year old primipara woman was referred to our maternal fetal medicine ultrasound unit at 17 weeks of gestation because of a concern about fetal gastroschisis. She reported no significant past medical or family history. Her initial sonographic examination showed the

Pervenuto in Redazione Ottobre 2015. Accettato per la pubblicazione Dicembre 2015

Correspondence to: Vesna Milojković Marinović, Dimitrije Tucovic 30, Belgrade, Serbia (e-mail: vesnamilojkovic@yahoo.com)

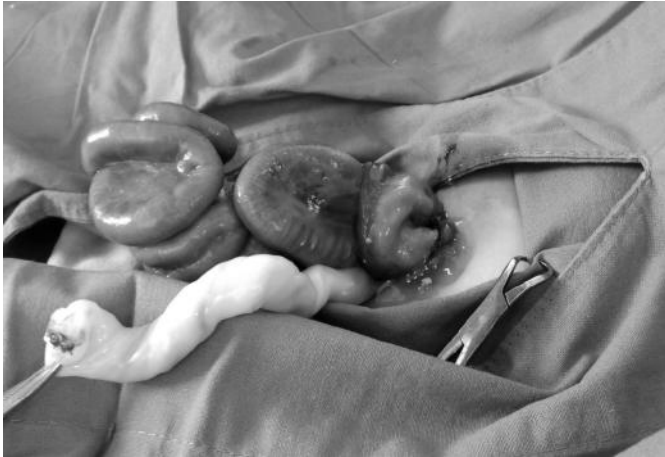

Fig. 1: Eviscerated small intestine and gaster on the right side of the umbilical cord.

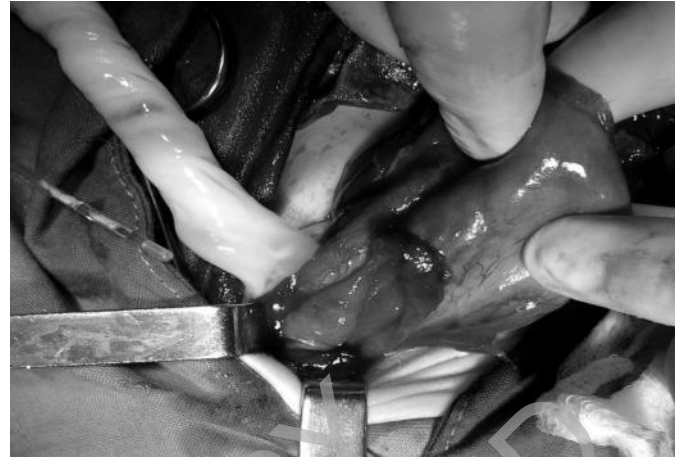

Fig. 2: Large perforation of the gaster at the greater curvature, anterior wall and gastric fundus, 6 cm in length.

fetus with intestines floating in the amniotic fluid. Abdominal wall defect is to the right side of the umbilicus and only the small bowel protruded from the abdomen. No other anomalies were detected. The patient was followed with serial sonographic examinations at 20, 24, 28, 32 and 36 weeks of gestation due to fetal development follow up, as well as bowel thickness and dilatation. Fetal growth was consistent with gestational age and no other fetal abnormality was detected. Amniocentesis revealed a 46 XY karyotype. At 32 weeks of gestation a follow up sonogram disclosed a bowel dilatation but didn't identify an early perforation. Intraabdominal bowel dilatation was 12 mm and extraabdominal bowel dilatation was 13 mm. The amniotic fluid volume was within normal limits. At 36 2/7 weeks of gestation elective cesarean section was performed for unrelated obstetrical indications. A 2550 g male infant was born with Apgar score of 8 and 9 at 1st and 5th minute respectively and arterial and venous cord gases had pH values of 7,30 and 7,35 respectively. Examination in the neonatal intensive care unit revealed that the stomach, small bowel and the part of the colon were herniated through the abdominal wall defect which was to the right of the umbilicus and about 2 cm in diameter (Fig. 1).

Results

The baby received surgical intervention on the same day. A large perforation site was at the greater curvature, followed by the anterior wall of the fundus in the length of 6 cm (Fig. 2). This anomaly was found after shifting the convolutes of small bowels and removing the meconium and thin fibrinous peels. By inspection of the small bowel a thin fibrous strip that extends from the edge of the abdominal defect to the mesenterial radix

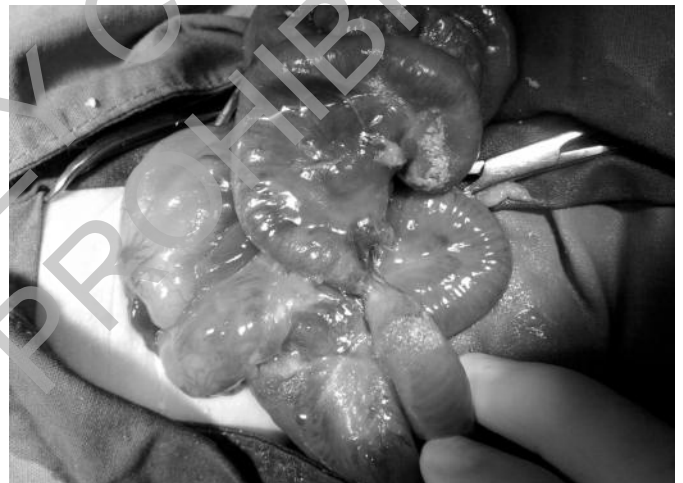

Fig. 3: Intestinal stenosis with meconium and thin fibrinous peels.

was found, approximately 15 cm from the duodenum with a length of 1,5 cm, causing stenosis of jejunum (Fig. 3). There was no evidence of intestinal atresia. Gastrorrhaphy was performed. About 1,5 cm of jejunum with stenosis was resected and t-t anastomosis was performed, followed by primary fascial closure. The resected segment of the bowel was sent for histological examination. The stomach, small bowel and the part of colon were easily reduced and the newborn underwent a primary abdominal wall closure with no signs of elevated intraabdominal pressure. The immediate postoperative course was uncomplicated. Postoperative management comprised balanced fluid and electrolyte administration, antibiotics for gram positive, gram negative and anaerobic bacteria.

Histological examination of resected small bowel specimen has shown stenosis of viable intestine with non-

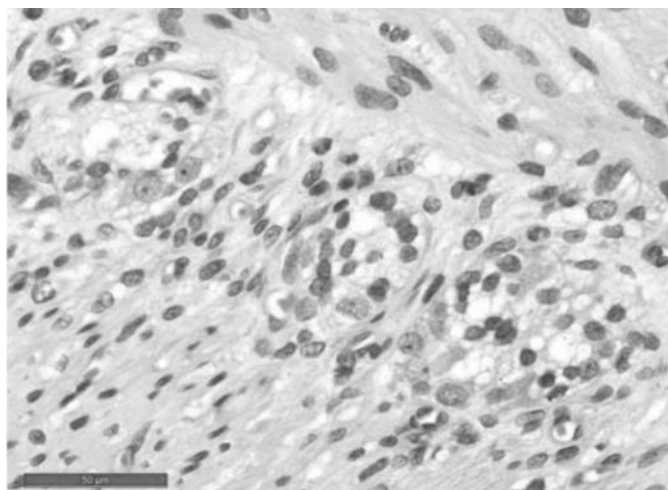


Fig. 4: Stenosis of viable intestine with nonspecific mucosal enteritis and marked submucosal edema. The muscular layer was normal with ganglion cells in the myenteric and submucosal plexus.

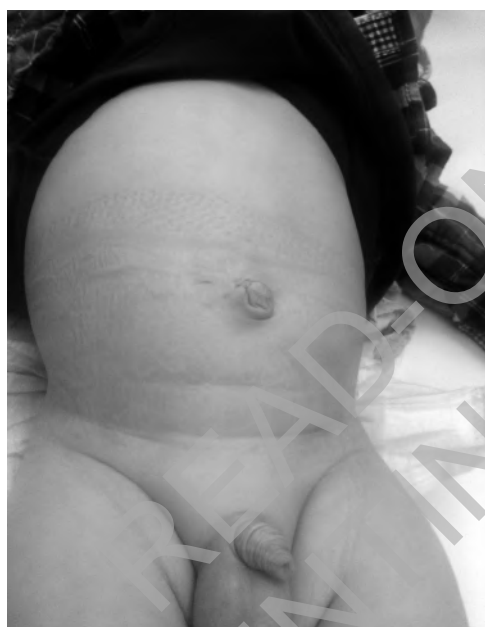

Fig. 5: Follow-up at 24 month of age.

specific mucosal enteritis and marked submucosal edema. The muscular layer was normal with ganglion cells in the myenteric and submucosal plexus (Fig. 4). The serosa was thickened with increased content of fibroblasts and collagen fibers and a layering of fibrin on the peritoneal surface. Spacemen of small bowel was 1.5 cm in length, with external diameter on resection edges – proximally 10 mm, and distally 4 mm. The lumen of the bowel was narrowed and reduced to a cleft of 1 mm in diameter.

The postoperative course was uneventful. There were no signs of sepsis. First enteral feeding was achieved on 7th postoperative day. The duration of TPN (total parenteral nutrition) was 12 days. Time of ventilatory support was 8 days. Length of hospital stay was 45 days. The patient remains well on follow-ups at 24 month of age (Fig. 5).

Discussion

The incidence of gastroschisis is as high as 4.4 per 10000 live births¹. Reviews in large national databases in Great Britain and the United States have shown complex gastroschisis to represent 11.5% and 10.9% of all cases respectively^{2,3}. A PubMed literature search revealed fetal gastroschisis with in utero eviscerated bowel or stomach perforation in 4 reports⁴⁻⁷. In one case gastric perforation was noted in prenatal period⁴ and in the other one gastric perforation was diagnosed during surgical repair for complex gastroschisis⁵. Two cases had bowel perforation with gastroschisis and intestinal atresia^{6,7}. The ultrasound image that shows fetal bowel perforation and fetal gastric perforation is not the same. Grundy et al (1987) reported a neonate who died 3 days after birth. The presence of extraabdominal intramesenteric pseudocyst and calcifications on the surface of the extraabdominal bowel led to a diagnosis of fetal bowel perforation with gastroschisis⁶.

Haberman et al. (2000) presented another case in which the infant survived after operation of complex gastroschisis. The neonatal outcome was favorable. At 34 weeks of gestation in a fetus with gastroschisis the sign that suggested an fetal acute bowel perforation was spillage of echogenic material at the margin of a bowel loop in the area of the abdominal wall defect. The patient described in this report had gastroschisis and intestinal atresia and developed a single perforation of the terminal ileum. Ileal perforation was noted proximal to an atretic area of bowel, near the abdominal wall defect. Fourteen centimetres of bowel was resected and ileostomy and primary fascial closure were performed⁷. Tseng JJ, Chou MM. (2002) presented a case of fetal eviscerated gastric perforation with different sonographic finding. Sonography characteristics included a triple layered gastric segment with mural thickening, a concave deformity of the inner layer and a small nodule on the outer surface. The newborn received primary repair of small perforation over the greater curvature of the stomach, followed by staged operations to reduce the exposed bowel loops⁴.

Yang CY et al. (2015) reported one patient in whom gastric perforation was diagnosed during surgical repair of complex gastroschisis (associated with colon atresia⁵). In our case of gastroschisis with gastric perforation and intestinal stenosis in male newborn, prenatal sonographic findings were inconclusive. Large gastric perforation was diagnosed during surgical repair of gastroschisis. The

prenatal sonographic finding of bowel or gastric perforation are variable, which was the case with our patient. According to literature prenatal sonographic findings depend on the extent of meconium leakage, time when the bowel or gastric perforation occurred, the underlying bowel disorder, the stage of the disease and the site of perforation⁸.

Some causative mechanisms of gastric perforation in gastroschisis are established on possible toxic effect of amniotic fluid on the smooth muscle cells, mesenteric shortening, constriction of the abdominal wall defect^{9,10}. Mesenteric shortening and vascular insults may result in thinning and interruption of the musculature. Inflammatory response to the chemical irritation of dissipated meconium may be responsible for the mural thickening and adhesions and results in stenosis of the intestinal wall.

Neonates with gastroschisis have delayed time for full enteral feeding (FEF), possibly due to bowel exposure to amniotic fluid. Antenatal bowel dilatation (bowel diameter ≥ 18 mm) and in particular intraabdominal bowel dilatation (IABD) is prognostically useful for detection of patients with impending necrosis or atresia and other patients who would have worse outcome¹¹. The absence of bowel dilatation cannot fully exclude complex patients. In the series presented by Helen Carnaghan et al. 19% complex patients never had IABD and 75% never had extraabdominal bowel dilatation (EABD)¹². Therefore, the absence of bowel dilatation cannot fully exclude complex patients with gastroschisis.

One study investigated IABD alone and found an association with prolonged time to full enteral feeding (FEF) and length of hospital stay (LHS)¹¹. These results are not supported by study data of Helen Carnaghan et al. or a systematic review of isolated gastroschisis which shows that neither IABD nor EABD are associated with increased adverse neonatal outcomes^{12,13}.

However, the presence of both IABD/EABD or IABD and collapsed extra-abdominal bowel at <30 weeks of gestation proved to be a more accurate predictor of poor outcome. Although these antenatal findings may indicate that the bowel damage has already occurred, it may be prudent in the presence of such findings to consider early delivery with the aim to salvage necrotic bowel. Early delivery is associated with prolonged FEF/LHS, suggesting that elective delivery at < 37 weeks is not beneficial. Combined IABD/EABD or IABD/collapsed extra-abdominal bowel is suggestive of complex gastroschisis¹².

Conclusion

We have presented, to our knowledge, the first detailed report of surgical intervention and outcomes in case of rare association of anomalies: complex gastroschisis and fetal gastric perforation and jejunal stenosis. Early restoration of bowel continuity using primary anastomosis is

recommended here. More research should be focused to predict complex gastroschisis and to improve prenatal diagnosis and postnatal management, without a significant increase in morbidity and mortality.

Riassunto

Una gastroschisi con perforazione gastrica prenatale associata a stenosi intestinale è un'anomalia rara e grave. Nonostante che vi siano molti casi descritti, in nessuna casistica c'è una valutazione prognostica di questi neonati. In questo articolo si presenta il caso di un neonato affetto da gastroschisi associata a perforazione gastrica e stenosi digiunale, e la revisione della letteratura. Stomaco, tenue e parte del colon erano erniati attraverso il difetto della parete addominale. Nella parete anteriore del fondo gastrico vi era una ampia perforazione, ed una sottile briglia fibrosa causava la stenosi del digiuno.

All'intervento si procedette con gastrorrafia, la stenosi del digiuno venne resecata con anastomosi t-t, ed eseguita la chiusura per primam della parete fasciale.

I reperti sonografici prenatali di perforazione del colon o dello stomaco sono variabili. La dilatazione prenatale dell'intestino, ed in particolare quella intraaddominale sono utili per individuare prognosticamente i pazienti con esito peggiore, ma l'assenza di dilatazione intestinale non può escludere del tutto che si tratti di pazienti complessi. Il precoce restauro della continuità intestinale con anastomosi immediata e chiusura al termine della parete addominale non sono motivo di un ritardo prolungato per iniziare l'alimentazione orale né un allungamento dei tempi di degenza.

Il presente articolo rappresenta la prima relazione dettagliata di un intervento chirurgico e relativo risultato in un caso di gastroschisi con perforazione gastrica prenatale e stenosi congenita del digiuno. Si raccomanda il precoce restauro della continuità intestinale con anastomosi immediata e chiusura contestuale della parete addominale. Ulteriori ricerche dovrebbero essere indirizzate alla previsione di gastroschisi complessa ed al miglioramento della diagnosi prenatale ed al trattamento dopo la nascita, senza un significativo incremento di morbilità e mortalità.

References

1. Owen A, Marven S, Jonson P, et al.: *Gastroschisis: A national cohort study to describe contemporary surgical strategies and outcomes*. J Pediatr Surg, 2010; 45:1808-816.
2. Penman DG, Fisher RN, Noblett HR, Soothill PW: *Increase in incidence of gastroschisis in the south west of England in 1995*. Br J Obstet Gynaecol, 1998; 105:328-31.
3. Arnold MA, Chang DC, Nabaweesi R, et al.: *Risk stratification of 4344 patients with gastroschisis into simple and complex categories*. J Pediatr Surg, 2007; 42:1520-525.

4. Tseng JJ, Chou MM: *In utero diagnosis of fetal gastroschisis with eviscerated gastric perforation.* Prenatal Diagn, 2002; 22:163-64.
5. Yang CY, Lien R, Fu RH, et al.: *Prognostic factors and concomitant anomalies in neonatal gastric perforation.* J Pediatr Surg, 2015; 50(8):1278-282.
6. Grundi H, Anderson RL, Filly RA, et al.: *Gastroschisis: prenatal diagnosis and management.* Fetal Ther, 1987; 2:144-47.
7. Haberman S, Burgess T, Klass L, et al.: *Acute bowel perforation in a fetus with gastroschisis.* Ultrasound Obstet Gynecol, 2000; 15:542-544.
8. Chalubinski K, Deutinget J, Bernaschek G: *Meconium peritonitis: extrusion of meconium and different sonographical appearances in relation to the stage of the disease.* Prenatal Diagn, 1992; 12:631-36.
9. Langer JC, Longaker MT, Crombleholme TM, et al.: *Etiology of intestinal damage in gastroschisis. I: Effects of amniotic fluid exposure and bowel constriction in a fetal lamb model.* J Pediatr Surg, 1989; 24:992-997.
10. Tatekawa Y, Muraji T, Imai Y, et al.: *The mechanism of focal intestinal perforations in neonates with low birthweight.* Pediatr Surg Int, 1999; 15:549-52.
11. Langer JC, Khanna J, Caco C, et al.: *Prenatal diagnosis of gastroschisis: development of objective sonographic criteria for predicting outcome.* Obstet Gynecol, 1993; 81:53-56.
12. Carnaghan H, Pereira S, James PC, et al.: *Is early delivery beneficial in gastroschisis?* J Pediatr Surg, 2014; 49:928-33.
13. Tower C, Ong SSC, Ewer AK, et al.: *Prognosis in isolated gastroschisis with bowel dilatation: A systematic review.* Arch Dis Child Fetal Neonatal Ed, 2009; 94:268-74.

READ-ONLY COPY
PRINTING PROHIBITED