

# Reduction mammoplasty using oxidized regenerated cellulose as a filler in breast conservation surgery



Ann. Ital. Chir., 2016 87: 292-297  
pii: S0003469X16025380

Gianluca Franceschini, Alejandro Martin Sanchez, Giuseppe Visconti, Alba Di Leone, Sabatino D'Archi, Antonino Mulè, Angela Santoro, Marzia Salgarello, Riccardo Masetti

Multidisciplinary Breast Center, Polo della Salute della Donna e del Bambino, Area Salute della Donna, Università Cattolica del Sacro Cuore, Fondazione Policlinico "Agostino Gemelli", Rome, Italy

## Reduction mammoplasty using oxidized regenerated cellulose as a filler in breast conservation surgery

*Oncoplastic surgery of the breast has generated great excitement over the past years and has become an integrated component of the surgical treatment of breast cancer.*

*Oncoplastic procedures (OPP) associate the best surgical oncologic principles to achieve wide tumor-free margins with the best principles of plastic surgery to optimize cosmetic outcomes. So, a number of conventional mammoplasty techniques have been adapted to allow reconstruction of resection defects with parenchymal flaps using a variety of different approaches. Thanks to these oncoplastic techniques, the role of breast conserving surgery (BCS) has been extended to include a group of patients who would otherwise require mastectomy to achieve adequate tumor clearance.*

*However, even with the use of therapeutic mammoplasties, cosmetic outcomes may result unsatisfying when a large volume of parenchyma has to be removed, particularly in medium size breasts and for tumor localized in unfavourable location as central, inner-upper and lower quadrants.*

*Recently, it has been proposed the use of oxidized regenerated cellulose (ORC) as a reconstructive biomaterial to optimize the aesthetic results after OPP.*

*The aim of this article is to describe the standard pattern of an innovative surgical oncoplastic technique with ORC, that we have called "QUORC" (QUadrantectomy with Oxidized Regenerated Cellulose), to improve cosmetic results and minimize the possible postoperative complications after therapeutic mammoplasties.*

KEY WORDS: Breast cancer, Cosmetic results, Oncoplastic surgery, Oxidized regenerated cellulose, QUORC technique

## Introduction

Breast conserving surgery (BCS) combined with postoperative radiotherapy has become the gold standard of locoregional treatment for the majority of patients with early-stage breast cancer, offering equivalent survival and

improved body image and lifestyle scores as compared to mastectomy<sup>1,2</sup>. In the era of early diagnosis and effective neoadjuvant therapies, BCS can be offered to over two-thirds of breast cancer patients.

The goals of BCS are to ensure a complete removal of the tumor with adequate surgical margins while preserving the natural shape and appearance of the breast. In some cases, achieving both goals may be quite challenging and as the need to secure an oncologically safe resection is the first priority, BCS may lead to unsatisfying cosmetic results<sup>3-8</sup>.

In the effort to overcome this difficulty and expand the use and efficacy of BCS, oncoplastic procedures (OPP) have been introduced in recent years gaining widespread attention both among surgeons and patients<sup>9-14</sup>. These procedures associate the best principles of surgical oncol-

Pervenuto in Redazione Febbraio 2016. Accettato per la pubblicazione Aprile 2016

Correspondence to: Gianluca Franceschini, MD, Università Cattolica del Sacro Cuore, Policlinico "Agostino Gemelli", Largo Agostino Gemelli 8, 00168 Roma, Italy (e-mail: gianlucafranceschini70@gmail.com)

ogy with the best principles of reconstructive surgery to optimize oncologic safety and cosmetic outcomes. OPP are characterized by more aesthetic skin incisions, use of enlarged resection patterns, careful reshaping of the gland, eventually by repositioning of the nipple-areola complex to the center of the breast mound, and symmetrization procedures on the contralateral breast to improve cosmesis. Volume displacement techniques with reduction mammoplasty are used for 20-50% breast volume excision and for patients with large-medium sized breasts. These procedures are particularly appropriate for tumor localized in any site but especially for unfavourable location as central, inner-upper and lower quadrants. Reduction mammoplasty techniques are suitable for patients with heavy, ptotic breasts, symptomatic macromastia who will benefit physically from the use of a bilateral breast reduction procedure.

Recently, it has been proposed the use of Oxidized Regenerated Cellulose (ORC) as a reconstructive biomaterial to optimize the aesthetic results after OPP<sup>15-18</sup>.

In this article we describe the standard pattern of an innovative oncoplastic technique with ORC, that we have called "QUORC" (QUadrantectomy with Oxidized Regenerated Cellulose), used to improve cosmetic results and minimize the possible postoperative complications after BCS with very wide resections, and reconstruction by means of reduction mammoplasty.

## Surgical Technique

In our surgical Breast Unit, over the last 7 years in performing OPP we have started to use oxidized regenerated cellulose (ORC) (Tabotamp fibrillar®, Johnson & Johnson; Ethicon, New Brunswick, NJ, USA) as a reconstructive biomaterial to facilitate the healing of the residual cavity and reduce the risk of unfavorable cosmetic outcomes, especially in wider excisions<sup>15</sup>.

Depending in the size and location of the tumor and the volume and shape of the breast as previously reported<sup>9-11</sup>, different OPP have been used including glandular reshaping procedures, "round block" procedures, reduction mammoplasty procedures, central quadrantec-

tomy procedures, inframammary fold procedures and batwing mastopexy procedures.

## SELECTION OF PATIENTS

Volume displacement techniques with reduction mammoplasty and ORC reconstruction is commonly used in our clinical practice for patients who require particularly wide volume excisions (30-50%) in medium and large size pendulous breasts, especially for tumors localized in unfavourable locations as central, inner-upper and lower quadrants.

Basing on tumor size and location, our previously described oncoplastic procedure of quadrantectomy with reduction mastopexy, following a keyhole pattern with nipple-areola complex (NAC) superior or inferior pedicle (10) is planned and discussed pre-operatively during multidisciplinary meetings, after reviewing all relevant breast imaging (Fig. 1).

Our surgical technique of QUadrantectomy with Oxidized Regenerated Cellulose (QUORC) in reduction mammoplasty follows a standard pattern.

## SURGICAL PROCEDURE

After tailored deepithelialization surrounding the NAC (as needed to shift the NAC upward to its new position), a wide quadrantectomy en bloc with the skin overlying the lesion and conducted down to the fascia of the pectoralis major muscle is performed (Fig. 1).

Adequate reshaping of the gland is performed by dissecting the residual breast parenchyma: superficially, from the medial and lateral subcutaneous tissue and deeply, from the pectoralis major fascia. With this dissection, two opponent superficial advancement flaps (i.e. skin, subcutis) and two opponent deep advancement flaps (i.e. breast parenchyma) are obtained (Fig. 2 A,B).

Major vascular perforators between the pectoralis muscle and residual parenchyma are preserved to minimize the risk of ischemic injury to the latter.

After careful control of the haemostasis, five separate lay-

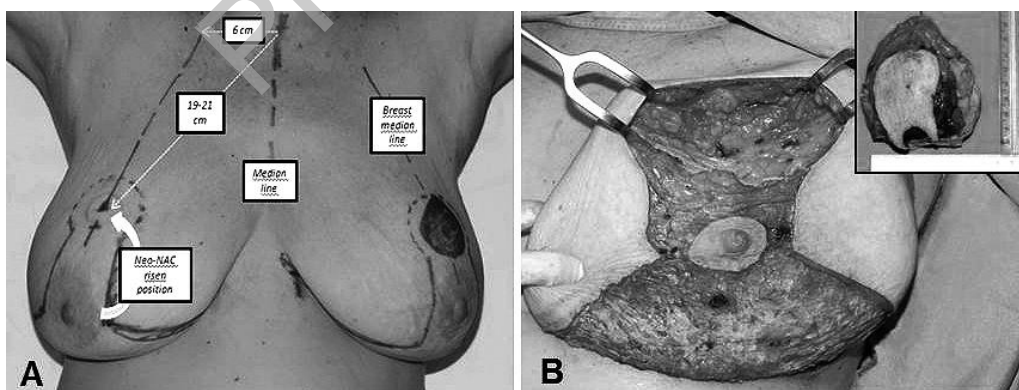


Fig. 1: Oncoplastic procedure of quadrantectomy with reduction mastopexy following a keyhole pattern with inferior pedicle. A) Tailored preoperative planning. B) Upper quadrantectomy with 40% of glandular tissue excision en bloc with the skin overlying the lesion.

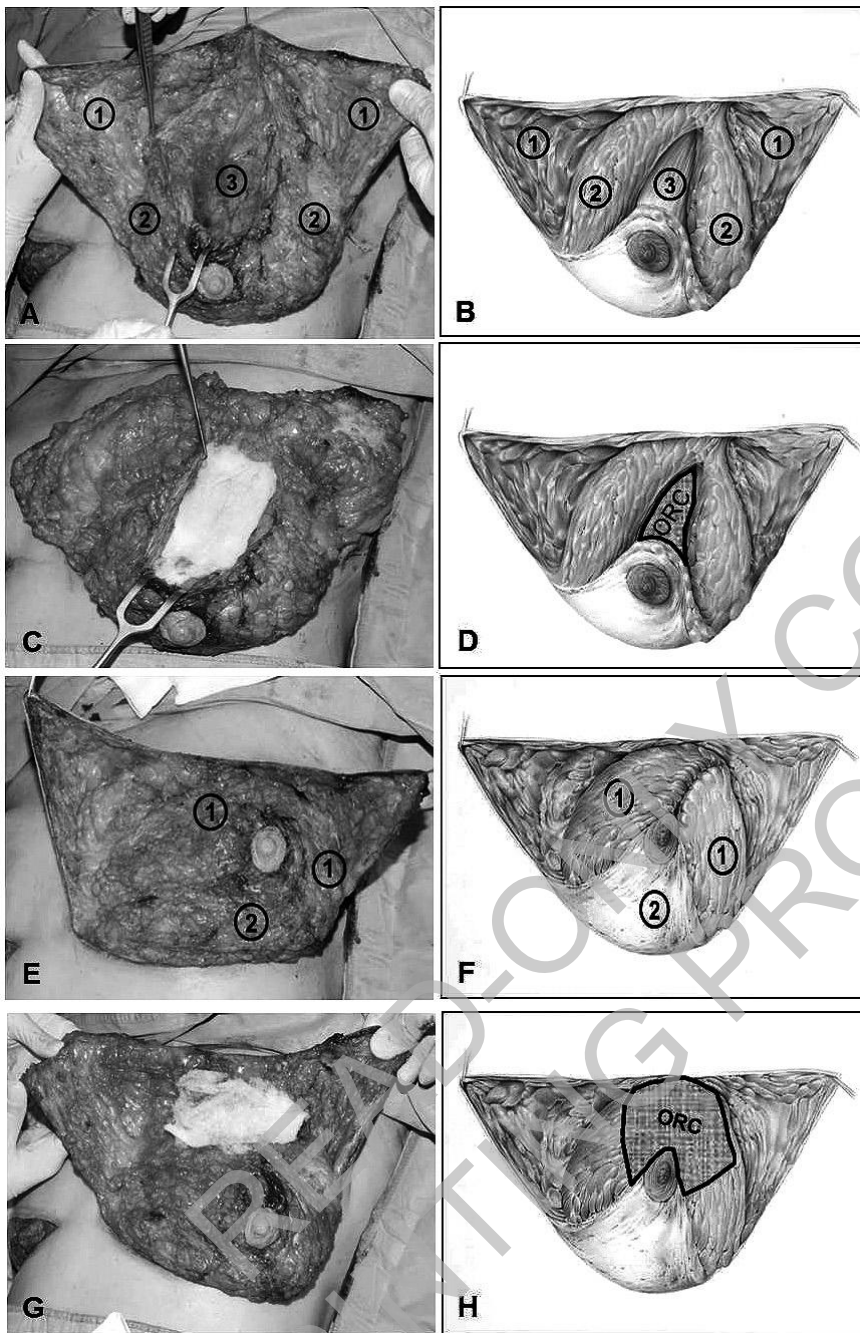


Fig. 2: Description of QUORC Technique. A-B) Dissection of residual breast parenchyma and gland reshaping. 1- Superficial cutaneous advancement flaps, 2- Deep glandular advancement flaps, 3- Pectoralis Major muscle fascia. C-D) Five layers of ORC placed in the residual cavity, topping the pectoralis major fascia. E-F) Deep glandular flaps suture, covering ORC deep layer. 1- Deep glandular flaps, 2- Inferior pedicle with risen NAC. G-H) Two additional layers of ORC, placed superficially, over the sutured glandular flaps.

ers of ORC (Tabotamp fibrillar) are placed in the residual cavity, topping the pectoralis major muscle (Fig. 2 C,D) and subsequently covered by advancement and suture of the two deep glandular flaps with absorbable 2-0 sutures (Fig. 2 E,F).

Two additional separate layers of ORC (Tabotamp fibrillar) are then placed on the surface of the approximated glandular flaps and covered by advancement of the superficial skin-subcutis flaps closed with a continuous absorbable 3-0 suture (Fig. 2 G,H). Finally, skin is closed using non-absorbable 3-0 suture (Fig. 3).

## Discussion

Oncoplastic surgery of the breast has become an integrated component of the surgical treatment of breast cancer. OPP associate the best surgical oncologic principles to achieve wide tumor-free margins with the best principles of plastic surgery to optimize cosmetic outcomes. So, a number of conventional mammoplasty techniques have been adapted to allow reconstruction of resection defects with parenchymal flaps using a variety of different approaches. Thanks to these oncoplastic techniques,

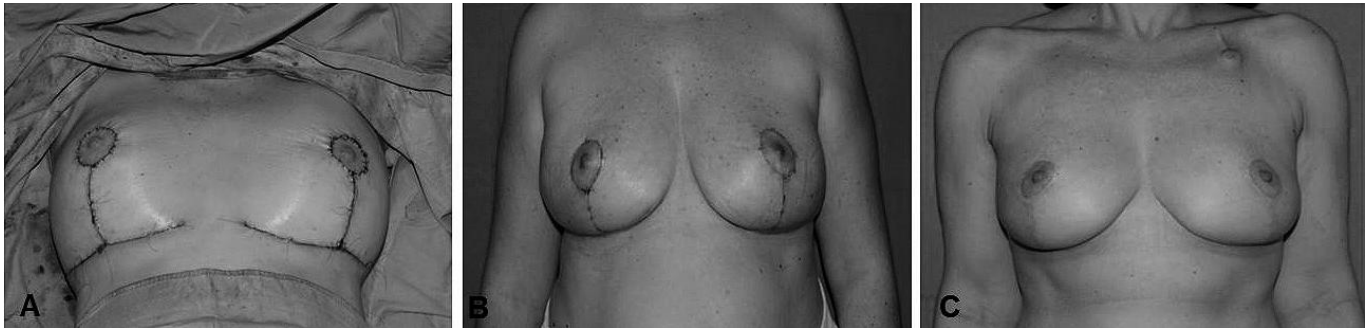

Fig. 3: A) Superficial skin-subcutis flaps closed with a non-absorbable 3-0 suture, topping the superficial ORC layer. B) Cosmetic result 2 months after surgery. C. Cosmetic result 12 months after surgery.

the role of BCS has been extended to include a group of patients who would otherwise require mastectomy to achieve adequate tumor clearance.

However, even with the use of therapeutic mammoplasties, cosmetic outcomes may result unsatisfying when a large volume of parenchyma has to be removed, particularly in medium size breasts and for tumor localized in unfavourable location as central, inner-upper and lower quadrants.

Recently, it has been proposed the use of ORC as a reconstructive biomaterial to optimize the aesthetic results after OPP<sup>15-18</sup>.

ORC is a well-known haemostatic biomaterial with antimicrobial properties. It is a sterile absorbable fibrous material prepared by the controlled oxidation of regenerated cellulose. After ORC has been saturated with blood, it swells into a brownish or black gelatinous mass which aids in the formation of a clot, thereby serving as a haemostatic adjunct in the control of local haemorrhage<sup>19-23</sup>. In addition to its local haemostatic properties, ORC exhibits *in vitro* bactericidal properties against a wide range of Gram positive and Gram negative organisms including aerobes and anaerobes<sup>24-25</sup>. Due to its morphology it can be used at any surgical site as it can easily and rapidly adapt to any surface.

Our preliminary results on the use of ORC with reconstructive aims in breast surgery indicate a positive role for ORC in preventing post-surgical breast deformities<sup>15</sup>.

Tanaka et al. reported improved cosmetic outcomes after breast conserving surgery with the use of ORC in 94 breast cancer patients treated at the Osaka Medical College Hospital (Osaka, Japan). Evaluation of cosmetic outcomes, performed by three staff surgeons at least 2 months after surgery using the scoring system (0-12 points) of the Japanese Breast Cancer Society, documented very positive results, with a mean score of 9.5 (3-12 points) and 71 patients (75.5%) categorized as "Excellent" ( $\geq 11$  points) or "Good" (8-10 points), and only one patient (1.1%) as "Poor" ( $\leq 4$  points)<sup>17</sup>.

Rassu et al presented their early experience on breast cancer patients treated with BCS and reshaping proce-

dures aided by the use of ORC. With a limited follow-up of 6 to 8 months, the Authors reported improved aesthetic outcomes in this new subset of patients<sup>18</sup>.

The positive role for ORC in preventing post-surgical breast deformities could be explained through a triple action:

- A mechanical action: ORC acts as a filler material that limits the volume defect created by the surgical resection and at the same time it interposes itself between the pectoralis major fascia and the skin avoiding skin-to-fascia adhesion.

- A reparative action: ORC seems to stimulate fibrogenesis in the first postoperative weeks and to favour reparative processes by inhibition of metallo-proteasins, absorption of free oxygen radicals and metallic ions as well as stabilize some growth factors<sup>26-32</sup>.

- A fibrogenesis action: ORC idrolytic products seems to have chemocinetic stimuli on human fibroblasts favouring their migration and fibroblastic activity<sup>27,30,33,34</sup>.

These actions culminate in the creation of a three-dimensional structure that acts as a permanent filler, thus allowing a definitive reconstruction of the defect and avoiding unpleasant cosmetic outcomes.

In an experimental study on Wistar rats, a breast-conserving surgery cavity was simulated and a combination of soft tissue displacement and ORC implantation was performed to evaluate the macroscopic volume retainment and the microscopic histologic features involved in ORC soft-tissue implantation<sup>35</sup>; implanted ORC was well integrated within the soft tissue from postoperative week 20, with diffuse fibrosis, angiogenesis and absence of capsule formation. The preliminary results confirmed that this biomaterial can further contribute to optimize cosmetic results in the oncoplastic surgery<sup>36,37</sup>.

## Conclusion

As the use of ORC has been reported to be useful as a reconstructive biomaterial in oncoplastic breast surgery, we propose a standard "QUORC" technique pattern that

can be implemented in association to very wide resections, in order to optimize cosmetic results and reduce the risk of postoperative haematoma and infections after therapeutic mammoplasties.

We believe that this method will further contribute to enrich the oncoplastic surgical spectrum of breast-conservation surgical procedures and further reduce the percentage of women requiring mastectomy.

## Riassunto

La chirurgia oncoplastica della mammella ha suscitato grande interesse negli ultimi anni ed è progressivamente divenuta una componente integrante ed essenziale del trattamento chirurgico conservativo dei tumori del seno. Le tecniche di chirurgia oncoplastica combinano i migliori principi della chirurgia oncologica con in migliori principi della chirurgia plastica con lo scopo di ottenere margini indenni da malattia ed al tempo stesso ottimizzare i risultati estetici.

In particolare le tecniche di mastoplastica riduttiva sono state applicate in pazienti con seni medio-grandi e ptosici per ottimizzare i risultati oncologici ed estetici. Grazie a queste procedure il trattamento conservativo della mammella è stato esteso ad includere un gruppo di pazienti che altrimenti avrebbero richiesto una mastectomia associata a complessi interventi di ricostruzione mammaria.

Tuttavia anche con l'applicazione delle tecniche di mastoplastica riduttiva gli esiti cosmetici possono risultare insoddisfacenti, in particolar modo in pazienti con seni medi che richiedono ampie resezioni parenchimali per tumori di voluminose dimensioni, localizzati nei quadranti supero-interni o inferiori.

Recentemente è stato quindi proposto l'utilizzo della cellulosa ossidata rigenerata come biomateriale ricostruttivo per ottimizzare i risultati estetici nella chirurgia oncoplastica.

Lo scopo di questo articolo è quello di descrivere il modello standard di una innovativa tecnica oncoplastica con cellulosa ossidata rigenerata che abbiamo denominato "QUORC" (QUadrantectomy with Oxidized Regenerated Cellulose) grazie alla quale sembra possibile migliorare i risultati estetici e ridurre al minimo le possibili complicanze post-operatorie, come infezioni ed ematomi, nella chirurgia oncoplastica con tecnica di mastoplastica riduttiva.

## References

1. Fisher B, Anderson S, Bryant J, Margolese RG, Deutsch M, Fisher ER, Jeong JH, Wolmark N: *Twenty-year follow-up of a randomized trial comparing total mastectomy, lumpectomy, and lumpectomy plus irradiation for the treatment of invasive breast cancer*. N Engl J Med, 2002; 347:1233-241.
2. Veronesi U, Cascinelli N, Mariani L, Greco M, Saccozzi R, Luini A, Aguilar M, Marubini E: *Twenty year follow-up of a randomized study comparing breast-conserving surgery with radical mastectomy for early breast cancer*. N Engl J Med, 2002; 347: 1227-232.
3. Olivetto IA, Rose Ma, Osteen RT, Love S, Cady B, Silver B, Recht A, Harris Jr: *Late cosmetic outcome after conservative surgery and radiotherapy: Analysis of causes of cosmetic failure*. Int J Radiat Oncol Biol Phys, 1989; 17:747-53.
4. Mills JM, Schultz DJ, Solin LJ: *Preservation of cosmesis with low complication risk after conservative surgery and radiotherapy for ductal carcinoma in situ of the breast*. Int J Radiat Oncol Biol Phys, 1997; 39:637-641.
5. De La Rochefordière A, Abner AL, Silver B, Vicini F, Recht A, Harris JR: *Are cosmetic results following conservative surgery and radiation therapy for early breast cancer dependent on technique?* Int J Radiat Oncol Biol Phys, 1992; 23: 925-31.
6. Taylor ME, Perez CA, Halverson KJ, Kuske RR, Philpott GW, Garcia DM, Mortimer JE, Myerson RJ, Radford D, Rush C.: *Factors influencing cosmetic results after conservation therapy for breast cancer*. Int J Radiat Oncol Biol Phys, 1995; 31:753-64.
7. Veronesi U, Volterrani F, Luini A, Saccozzi R, Del Vecchio M, Zucali R, Galimberti V, Rasponi A, Di Re E, Squicciarini P: *Quadrantectomy versus lumpectomy for small size breast cancer*. Eur J Cancer, 1990; 26:671-73.
8. Franceschini G, Sanchez AM, Di Leone A, Magno S, Moschella F, Accetta C, Natale M, Di Giorgio D, Scaldaferrì A, D'Archi S, Scardina L, Masetti R: *Update on the surgical management of breast cancer*. Ann Ital Chir, 2015; 86:89-99.
9. Franceschini G, Magno S, Fabbri C, Chiesa F, Di Leone A, Moschella F, Scafetta I, Scaldaferrì A, Fragomeni S, Adesi Barone L, Terribile D, Salgarello M, Masetti R: *Conservative and radical oncoplastic approaches in the surgical treatment of breast cancer*. Eur Rev Med Pharmacol Sci, 2008; 12:387-96.
10. Masetti R, Di Leone A, Franceschini G, Magno S, Terribile D, Fabbri C, Chiesa F: *Oncoplastic techniques in the conservative surgical treatment of breast cancer: An overview*. Breast J, 2006; 12(5 Suppl 2): S174-180.
11. Franceschini G, Terribile D, Magno S, Fabbri C, Accetta C, Di Leone A, Moschella F, Barbarino R, Scaldaferrì A, D'Archi S, Carvelli ME, Bove S, Masetti R: *Update on oncoplastic breast surgery*. Eur Rev Med Pharmacol Sci, 2012.
12. Nahabedian MJ: *Oncoplastic Surgery of the Breast*. Philadelphia: WB Saunders Elsevier, 2009.
13. Anderson BO, Masetti R, Silverstein MJ: *Oncoplastic approaches to partial mastectomy: An overview of volume-displacement techniques*. Lancet Oncol, 2005; 6:145-57.
14. Clough KB, Kaufman GJ, Nos C, Buccimazza I, Sarfati IM: *Improving breast cancer surgery: A classification and quadrant per quadrant atlas for oncoplastic surgery*. Ann Surg Oncol, 2010; 17: 1375-391.
15. Franceschini G, Visconti G, Terribile D, Fabbri C, Magno S, Di Leone A, Salgarello M, Masetti R: *The role of oxidized regenerate cellulose to prevent cosmetic defects in oncoplastic breast surgery*. Eur Rev Med Pharmacol Sci, 2012; 16(7):966-71.

16. Franceschini G, Visconti G, Masetti R: *Oncoplastic breast surgery with oxidized regenerated cellulose: Appraisals based on five-year experience*. Breast J, 2014; 20(4):447-48.
17. Tanaka S, Sato N, Fujioka H, Takahashi Y, Kimura K, Iwamoto M, Uchiyama K: *Breast conserving surgery using volume replacement with oxidized regenerated cellulose: A cosmetic outcome analysis*. Breast J, 2014; 20(2):154-58.
18. Rassu PC, Serventi A, Giaminardi E, Ferrero I, Tava P: *Use of oxidized and regenerated cellulose polymer in oncoplastic breast surgery*. Ann Ital Chir, 2013; 84(ePub).
19. Bassetto F, Vindigni V, Scarpa C, Botti C, Botti G: *Use of oxidized regenerated cellulose to stop bleeding after a facelift procedure*. Aesthetic Plast Surg, 2008; 32:807-09.
20. Belov Iuv, Bazylev Vv, Alekseev IA: *The use of oxidized regenerated cellulose for hemostasis in cardiac surgery*. Khirurgiia, 2009; 10-14.
21. Krízová P, Másová L, Suttar J, Salaj P, Dyr Je, Homola J, Pecka M: *The influence of intrinsic coagulation pathway on blood platelets activation by oxidized cellulose*. J Biomed Mater Res A, 2007; 82: 274-80.
22. Másová L, Rysavá J, Krízová P, Suttar J, Salaj P, Dyr JE, Homola J, Dostálek J, Myska K, Pecka M: *Hemostyptic effect of oxidized cellulose on blood platelets*. Sb Lek, 2003; 104: 231-36.
23. Habal P, Omran N, Mand'ák J, Simek J, Stetina M: *Controlled hemostasis in thoracic surgery using drugs with oxidized cellulose*. Acta Medica, 2011; 54: 153-56.
24. Alfieri S, Di Miceli D, Menghi R, Quero G, Cina C, Pericoli Ridolfini M, Doglietto G: *Role of oxidized regenerated cellulose in preventing infections at the surgical site: prospective, randomized study in 98 patients affected by a dirty wound*. Minerva Chir, 2011; 66: 55-62.
25. Spangler D, Rothenburger S, Nguyen K, Jampani H, Weiss S, Bhende S: *In vitro antimicrobial activity of oxidized regenerated cellulose against antibiotic-resistant microorganisms*. Surg Infect (Larchmt) 2003; 4: 255-62.
26. Jeschke MG, Sandmann G, Schubert T, Klein D: *Effect of oxidized regenerated cellulose/collagen matrix on dermal and epidermal healing and growth factors in an acute wound*. Wound Repair Regen, 2005; 13: 324-31.
27. Liu SA, Cheng CC, Chen JS, Hung YW, Chen FJ, Chiu YT: *Effect of oxidized regenerated cellulose on the healing of pharyngeal wound: An experimental animal study*. J Chin Med Assoc 2012; 75:176-82.
28. Ulrich D, Smeets R, Unglaub F, Wöltje M, Pallua N: *Effect of oxidized regenerated cellulose/collagen matrix on proteases in wound exudate of patients with diabetic foot ulcers*. J Wound Ostomy Continence Nurs, 2011; 38: 522-28.
29. Smeets R, Ulrich D, Unglaub F, Wöltje M, Pallua N: *Effect of oxidized regenerated cellulose/collagen matrix on proteases in wound exudate of patients with chronic venous ulceration*. Int Wound J, 2008; 5: 195-203.
30. Hart J, Silcock D, Gunnigle S, Cullen B, Light ND, Watt PW: *The role of oxidized regenerated cellulose/collagen in wound repair: effects in vitro on fibroblast biology and in vivo in a model of compromised healing*. Int J Biochem Cell Biol, 2002; 34:1557-570.
31. Jeschke MG, Sandmann G, Schubert T, Klein D: *Effect of oxidized regenerated cellulose/collagen matrix on dermal and epidermal healing and growth factors in an acute wound*. Wound Repair Regen, 2005; 13:324-31.
32. Cullen B, Watt PW, Lundqvist C, Silcock D, Schmidt RJ, Bogan D, Light ND: *The role of oxidized regenerated cellulose/collagen in chronic wound repair and its potential mechanism of action*. Int J Biochem Cell Biol, 2002; 34:1544-556.
33. Gago LA, Saed GM, Wang RX, Kruger M, Diamond MP: *Effects of oxidized regenerated cellulose on the expression of extracellular matrix and transforming growth factor-beta1 in human peritoneal fibroblasts and mesothelial cells*. Am J Obstet Gynecol, 2003; 189: 1620-625.
34. Giuliani M, Fubelli R, Patrolecco F, Rella R, Borelli C, Buccheri C, Di Giovanni SE, Belli P, Romani M, Rinaldi P, Bufi E, Franceschini G, Bonomo L: *Mammographic and ultrasonographic findings of oxidized regenerated cellulose in breast cancer surgery: A 5-year experience*. Clin breast cancer. 2015; 15(5):e249-56. doi: 10.1016/j.clbc.2015.03.008. Epub 2015 Mar 24.
35. Franceschini G, Visconti G, Sanchez AM, Di Leone A, Salgarello M, Masetti R: *Oxidized regenerated cellulose in breast surgery: experimental model*. J Surg Res. 2015; 198(1):237-44. doi: 10.1016/j.jss.2015.05.012. Epub 2015 May 15.
36. Franceschini G, Sanchez AM, Visconti G, Di Leone A, Salgarello M, Masetti R: *Quadrantectomy with oxidized regenerated cellulose ("QUORC"): an innovative oncoplastic technique in breast conserving surgery*. Ann Ital Chir, 2015; 86:548-52.
37. Rassu PC: *Observed outcomes on the use of oxidized and regenerated cellulose polymer for breast conserving surgery. A case series*. Ann Med Surg (Lond). 2015; 5:57-66. doi: 10.1016/j.amsu.2015.12.050. eCollection 2016.