

# Huge fibroid (g. 3.000) removed during cesarean section with uterus preservation.

## A case report



Ann. Ital. Chir., 2011 82: 75-77

Vito Leanza\*, Simona Fichera\*\*, Gianluca Leanza\*, Matteo Angelo Cannizzaro\*\*

\*Obstetrics and Gynaecology Department, Catania University, Catania, Italy

\*\*General Surgery Specialization school Catania University, Catania, Italy

### Huge fibroid (g. 3.000) removed during cesarean section with uterus preservation. A case report.

*Removal of a giant fibroid during a caesarean section is very rare. We report a case of multiple myomectomy among which a huge myomas (cm 22, weight 3.000 g) in a 44 years old nullipara at 38 weeks. A 10 cm long suprapubic transversal incision according to Pfannenstiel on spinal anaesthesia was done; a female baby weighing 2.285 g, with Apgar score 9/10 was born. Owing to the uterine hypotonia following foetal extraction, myomectomy with womb preservation was carried out. Postoperative course was regular for mother and newborn too.*

KEYWORD: Huge fibroid, Miomectomy in caesarean section, Uterus preservation.

### Background

The standard teaching is to avoid caesarean myomectomy as much as possible for the fear of the attendant severe haemorrhage<sup>1</sup>. Myomectomy during Caesarean section is conventionally reserved for pedunculated myomas. When fibroids are located in the wall or in the submucous tissue the operation is more complicated<sup>2</sup>. Although the removal of uterine mass during caesarean section (CS) may lead to an increased incidence of haemorrhage, many authors sustain that this procedure is safe<sup>3-6</sup>. Obstetric literature has reported an increase of successful myomectomy also during pregnancy<sup>7-9</sup>. Until today, caesarean myomectomy remains a controversial procedure<sup>10-12</sup>. While its performance for obstetric problems is not an extraordinary procedure, we have to consider that the removal of a huge myoma (over 2 kg) is very rare. The management of uterine

fibroids during pregnancy is usually expectant; surgery is postponed until C.S. or after patient remission. A case of giant fibroid (g 3.000) removal with uterus preservation during CS in a 44-year-old 38 weeks pregnant woman is reported.

### Case presentation

A 44 years old woman reported a two years history of abdominal swelling and epigastric pain. Patient got married at the age of 43 and before being pregnant she underwent gynaecological visit. The abdomen was grossly distended. Ultrasounds examination showed a huge myoma (22 cm) occupying the whole abdominal cavity; other six myomas were spread inside the uterus. After informing the patient about the risk of either myomectomy or expectant treatment, the patient chose the latter one. She was pregnant after one month. During pregnancy, abdominal pains compelled the patient to stay mainly in bed, but she never lost the hope of a successful delivery. On the first trimester she suffered from haemorrhage treated with tranexamic acid and progesterone. Folates, vitamins and iron supplements were administered during the whole gestational period. The

Pervenuto in Redazione Settembre 2010. Accettato per la pubblicazione Novembre 2010.

Correspondence to: Prof Vito Leanza, via Antonello da Messina 83, 95021 Acicastello (Messina) Italy (e-mail:vito.leanza@gmail.com)

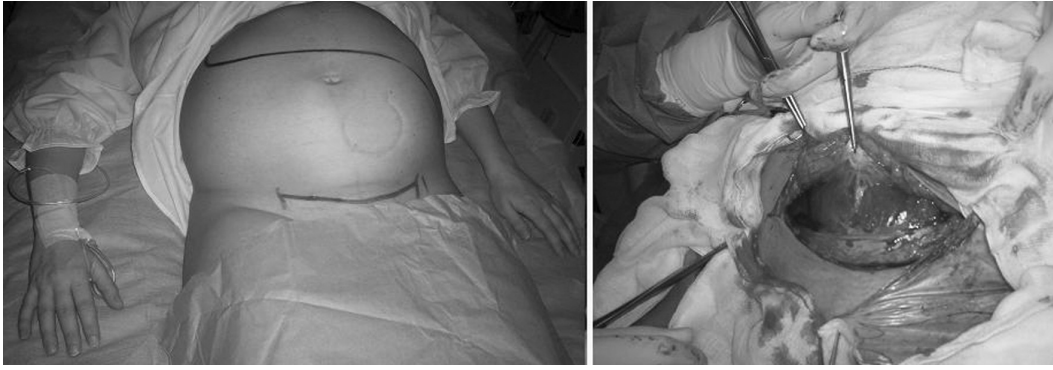


Fig. 1: Picture showing both pregnancy and incision.

pregnancy was carefully monitored to check both the foetal growth and the enlargement of the myoma. The patient was admitted in hospital at the 38th week of gestation for a planned C.S. Ultrasound examination showed foetus in a good health. A large myoma occupied most of the uterine walls, compressing both maternal kidneys and foetal body. The patient was given an informed consent explaining the procedure with the potential risk of haemorrhage and hysterectomy.

A 10 cm suprapubic transversal incision according to Pfannenstiel on spinal anaesthesia was performed; a female baby weighing 2.285 g, Apgar score 9/10 was born. Following the removal of the placenta, the uterus was sewed in two layers suture. Due to uterine hypotonia, we decided to perform myomectomy. A saving skin longitudinal cut of the abdominal fascia was performed, to allow its extraction. Removal of the largest myoma (cm 22, weight 3.000 g) was carried out by lozenge incision of the perimyomatous tissue. Owing to the size of the largest fibroid, the extraction was very difficult. A section of the mass was required to allow its exteriorization. Myometrial bed was quickly closed with an uninterrupted suture followed by a meticulous haemostasis. The remaining 6 myomas were, afterwards, removed easily. Longitudinal incision of the fascia was closed "ab interno" and, after inserting intraperitoneal drainage, the abdominal wall was sowed in layers. Intradermic suture ended surgery. A 300 cc blood transfusion was necessary.

Before the operation haemoglobin was 12.3 g/dL and the values in the five post-operative days were as following 9.1, 7.3, 7.5, 7.9, 8.8 g/dL. Ultrasound exami-

nation showed a progressive reduction of renal dilatation. Seven days after surgery, both the mother and her baby were discharged in good general conditions.

## Discussion

The treatment of uterine myoma during pregnancy is largely expectant and its surgical removal is generally delayed until CS or after delivery. The prevalence of leiomyoma during pregnancy is reported in a rate of 2%<sup>5</sup>.

Uterine myoma could be either asymptomatic or symptomatic. Red degeneration, increased frequency of spontaneous abortion, preterm labour, premature rupture of foetal membranes, ante partum haemorrhage, malpresentations, obstructed labour, CS and postpartum haemorrhage are among the most frequent complications. Due to the increased vascularisation of the gravidic uterus, women are at increased risk of bleeding and postoperative morbidity during myomectomy, and this is why the surgeon skilfulness is a mandatory issue. Though a case of removal of 40 myomas during caesarean was reported<sup>13</sup> and literature shows intracaesarean myomectomy being safe, our opinion is that it still remains an elaborate surgical procedure and is not to be undervalued. This case-report offers to consider mainly the following problems:

1) *Problem related to the mother*: the choice of performing myomectomy before, during or after pregnancy in a 44 years old woman with no previous children is very difficult to establish. The evaluation must be done in

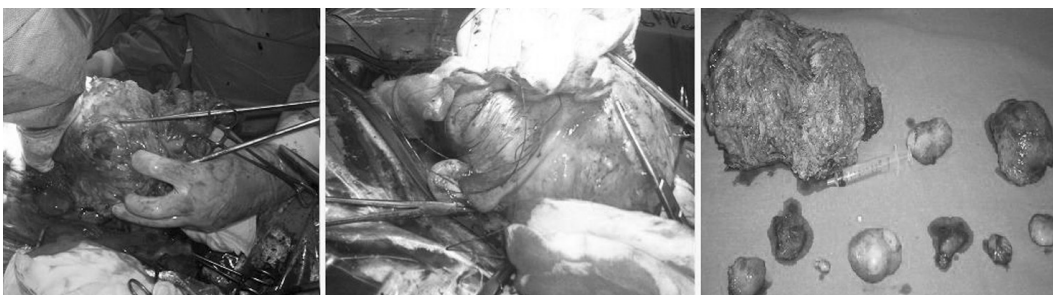

Fig. 2: Steps of surgery

accordance with the site, the size, the number of the myomas and, the last but not the least, the surgical experience. Finally the decision of the mother following an informative consent must be prevailing. When woman with large fibroids becomes pregnant, besides medical therapy, both serenity and rest are mandatory. Furthermore the physicians and the pregnant woman have to be ready to face every sort of events, but it is not established that they arise.

2) *Condition and development of the foetus*: the foetus must be monitored during pregnancy. A large myoma occupying a lot of space may severely affect the foetal growth.

3) *Management of myoma*: when myoma is asymptomatic an attendance choice is advantageous.

4) *Hydronephrosis*: during pregnancy the hydronephrosis of urinary tract is not rare. Only in some cases ureteral stent is necessary. As long as clinic condition allows, a waiting management is desirable, till the removal of extrinsic cause may solve the renal dilatation, without compromising other factors.

5) *Timing and choice of the delivery*: whenever possible, a delivery at term is always to be preferred. In case of praevius fibroid CS becomes a compulsory step.

6) *Surgical risk*: it depends on many factors among which the size, the site and the number of the tumours. Regarding to size, the larger it is the harder the surgery becomes. As for as the site; the subserous and the pedunculated ones are the easier to be removed. Finally, the increasing of the number makes more challenging the procedure.

### Riassunto

L'asportazione di un fibroma gigante nel corso di un taglio cesareo è un'evenienza molto rara. Riferiamo qui il caso di una miomectomia multipla, tra cui l'asportazione di un mioma molto voluminoso (22 cm di diametro e 3.000 g di peso) in una nullipara di 44 anni alla 38° settimana di gravidanza.

L'intervento è stato eseguito in anestesia spinale mediante un'incisione sovrapubica trasversale secondo Pfannenstiel di 10 cm; la neonata, di sesso femminile, pesava 2.285 g, con Apgar score di 9/10.

Considerata l'atonía uterina dopo l'estrazione del feto, si è proceduto alla miomectomia con conservazione dell'utero. Il decorso postoperatorio è stato regolare sia per la madre che per la neonata.

### Acknowledgment

We are very grateful to Prof. Salvatore Sciarretta for his precious help in translating this work.

### References

- 1) Igwegbe AO, Nwosu BO, Ugboaja JO, Monago EN: *Inevitable caesarean myomectomy*. Niger J Med, 2010; 19(2):233-35.
- 2) Abasiattai AM, Bassey EA, Essien EU, Utuk NM: *Inevitable myomectomy during caesarean section: A case report*. Niger J Clin Pract. 2009; 12(1):99-100.
- 3) Brown D, Fletcher HM, Myrie MO, Reid M: *Cesarean myomectomy- a safe procedure. A retrospective case controlled study*. Obstet Gynecol 1999, 19:139-41.
- 4) Ikedife D: *Surgical challenge of myomectomy at cesarean section*. Nigerian Journal of Surgical Sciences, 1993; 3:15-17.
- 5) Kwawukume EY: *Myomectomy during cesarean section*. Int J Gynecol Obstet, 2002; 76:183-84.
- 6) E Higiigbe AE, Ande AB, Ojibo SI: *Myomectomy during caesarean section*. Int J Gynecol, 2001; 75:2-5.
- 7) Lolis DF, Kalantaridou SN, Makrydimas G, Sotiriadis A, Navrozoglu I, Zikopoulos K, Paraskevaides EA: *Successful myomectomy during pregnancy*. Human Reproduction, 2003; 18:1699-702.
- 8) Michalas SP, Oreopoulou FV, Papageorgiou JS: *Myomectomy during pregnancy and caesarean section*. Human Reproduction, 1995; 10:1869-70.
- 9) Umezurike C, Feyi-Waboso P: *Successful myomectomy during pregnancy: A case report*. Reproductive Health, 2005; 2:6 1-3.
- 10) Roman AS, Tabsh KM: *Myomectomy at time of cesarean delivery; A retrospective cohort study*. BMC Pregnancy and childbirth, 2004, 4:14.
- 11) Ashley S, Roman, Khalil MA, Tabish: *Myomectomy at time of caesarean delivery; A retrospective cohort study*. Int J Gynecol Obstet, 2005; 89(2):90-93.
- 12) Kaymak O, Ustunyurt E, Okay RE, Kalyoncu S, Mollamahmutoglu L: *Myomectomy during caesarean section*. Int J Gynecol Obstet, 2005; 89(2):90-93.
- 13) Lanza V, D'Agati A, Accardi M, Russo ER: *Multiple myomectomy performed during caesarean section: A case report*. Minerva Ginecologica, 2009; 61(3):24.

