

# Management of colovesical and colovaginal diverticular fistulas

## Our experience and literature reviewed



*Ann Ital Chir*, 2017 88, 1: 55-61

pii: S0003469X17022394

Epub Ahead of Print 3 Oct. 2014

free reading: [www.annitalchir.com](http://www.annitalchir.com)

Tommaso Marcucci\*, Sandro Giannessi\*, Francesco Giudici\*\*, Sara Riccadonna\*, Agnese Gori\*, Francesco Tonelli\*\*

\*Division of General Surgery, San Jacopo Hospital, Pistoia, Italy

\*\*Department of Surgery and Translational Medicine, University of Florence, Florence, Italy

### Management of colovesical and colovaginal diverticular fistulas. Our experience and literature reviewed

**AIM:** This study aims evaluate the effectiveness of various surgical techniques in treating diverticular fistulas, and the safety and efficacy of the laparoscopic procedure comparing our results with those of the literature.

**MATERIAL OF STUDY:** This was a prospective and uncontrolled study performed at a general surgery units. Between 2005 and 2011, 16 patients (11 men, 5 women) underwent surgery for diverticular fistulas. The mean age was 70.2 (range, 35-87) years. The medical evaluation of these patients was based on symptoms and diagnostic procedures confirming the diagnosis of diverticular fistulas. Our surgical options included one-stage, two-stage, and defunctioning procedures.

**RESULTS:** Out of 16 cases of diverticular fistula 14 were colovesical and 2 colovaginal. One-stage procedure was performed in 12 patients, two-stage procedure in 3 and defunctioning colostomy in 1. The overall complication rate was 31.2%. We recorded 1 colovesical recurrent fistula. The laparoscopic surgery was performed in 4 patients, nobody was converted to open and there were no post-operative complications and recurrence.

**DISCUSSION AND CONCLUSIONS:** The data show that one-stage procedure is effective in the majority of cases of diverticular fistulas. However, the surgery of colovesical and colovaginal fistulas is often associated to high complication rates. This is often due to the shoddy clinical conditions and long-term diverticular illness of this group of patients. At present, the laparoscopy in an elective setting is not considered any more a contraindication in the treatment of diverticular fistulas.

**KEY WORDS:** Diverticular fistulas, Laparoscopic surgery

### Introduction

The incidence rate of enteric fistulas in diverticular disease is about of 2-4% reaching up to 20% in patients

undergo surgery for diverticulitis<sup>1-3</sup>. Sigmoid diverticulitis is the most frequent cause of enteric fistulas. The most common diverticular fistula is colovesical (60%), followed by colovaginal (20%)<sup>1,3-11</sup>. Other possible fistulas are coloenteric, colosalpingeal and colocutaneous. The two possible therapeutic approaches are conservative (standard intravenous fluids, artificial nutrition and antibiotic therapy) and surgical respectively. The conservative therapy is ineffective to treat the fistulas and it is associated with a high recurrence risk<sup>2,12-14</sup>. The conservative approach is suitable in patients with high anaesthesiologic risk or that refuse the surgical treatment. At

*Pervenuto in Redazione Novembre 2013. Accettato per la pubblicazione Febbraio 2014*

*Correspondence to Tommaso Marcucci, MD, San Jacopo Hospital, Via Pertini 708, 51100 Pistoia, Italy (e-mail: [tommaso.marcucci@libero.it](mailto:tommaso.marcucci@libero.it))*

present, most authors recommend the surgery as first choice<sup>2,12-14</sup>. This study aims to report our experience in the treatment of diverticular fistulas and compare our results with those of the literature.

## Patients and Method

Between 2005 and 2011, at our institutions, 16 patients underwent surgery for diverticular fistulas, 11 males and 5 females respectively, due to sigmoid diverticulitis. The overall mean age was 70.2 (range: 35-87) years. The medical evaluation of these patients was based on symptoms and diagnostic procedures confirming the diagnosis of diverticular fistulas. The clinical manifestations of colovesical fistulas were disorders such as pneumaturia, fecaluria, dysuria, urinary tract infections and major abdominal problems such as signs of local peritonitis. On other hand, in the patients affected by colovaginal fistulas the most frequent presenting complaints were abnormal vaginal discharge of faeces, flatus or bloody and lower abdominal pain. The diagnostic tools included colonoscopy, conventional radiographic cystogram, barium enema, computerized tomography with oral and/or rectal contrast (Fig. 1) and colposcopy. These investigations were performed to diagnose the fistula and to demonstrate the diverticular disease in the large bowel. Our surgical options performed in open or in laparoscopy, included one-stage repair with primary anastomosis, two-stage repair with Hartmann's procedure or

primary anastomosis with fashioning of a ileostomy, and defunctioning procedures. In one-stage procedure, the surgical protocol included identification of the left ureter, separation of the fistulized bowel from the bladder or vagina at the site of the fistula and the resection of the diseased bowel segment with fashioning of primary anastomosis using a circular end-to-end stapling. In laparoscopic technique, we positioned 5 trocars by open laparoscopy procedure and the dissection of tissues was performed by ultrasound device (Fig. 2). The treatment of fistulized bladder consisted in suture of the defect with drainage by Foley catheter for 7 days or in partial vesical resection, while the vaginal defect was sutured. All eligible patients accepted participation in the study and signed an informed consent form in which the nature of the pilot procedure was described.

## Results

Out of 16 cases of diverticular fistula 14 were colovesical and 2 colovaginal (Table I). The open surgery was performed in 12 patients while 4 patients with colovesical fistula underwent to laparoscopic surgery (Table II). Elective resection of the diseased colonic segment with primary anastomosis in one-stage was performed in 12 patients (in 8 patients by open approach and in 4 patients by laparoscopic approach) (Table II). In urgency setting three patients underwent to surgery in two-stage (2 primary anastomosis with fashioning of a covering

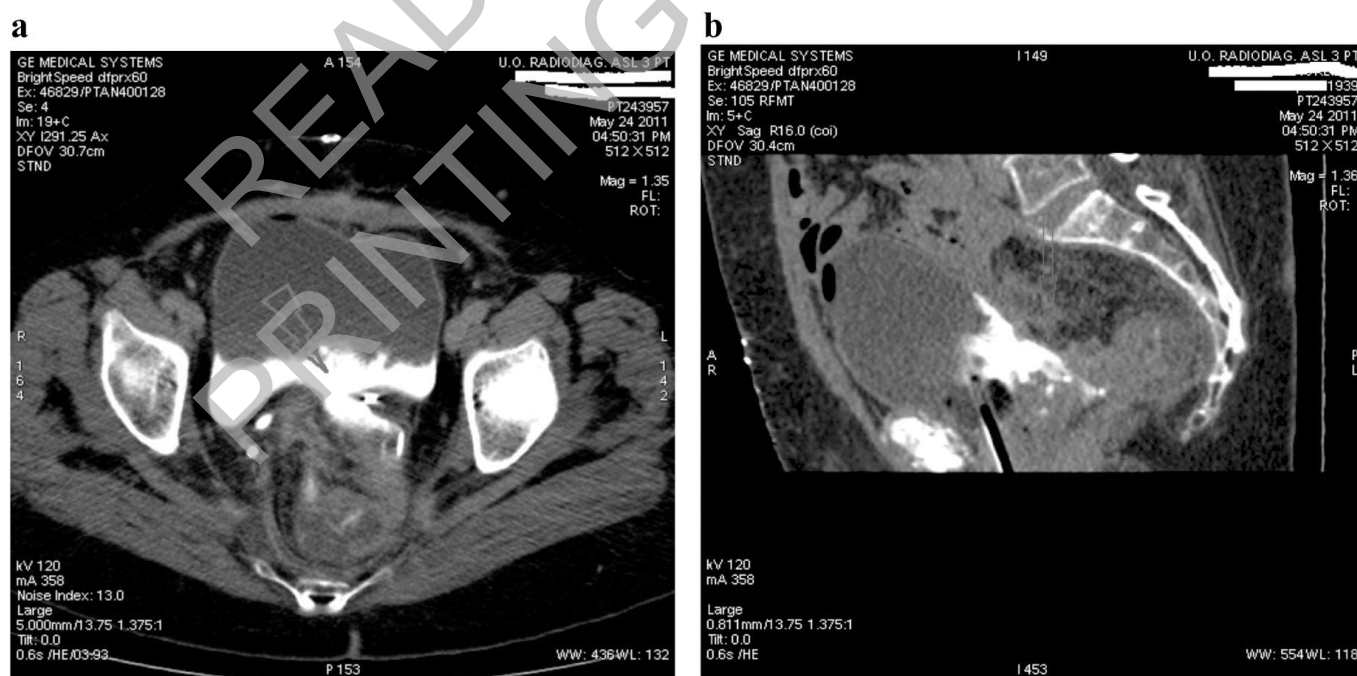


Fig. 1: Abdomen and pelvis computed tomography scan shows the presence of a colovesical fistula with the passage of contrast from sigmoid colon to the bladder (arrow): a) axial view and b) sagittal view.

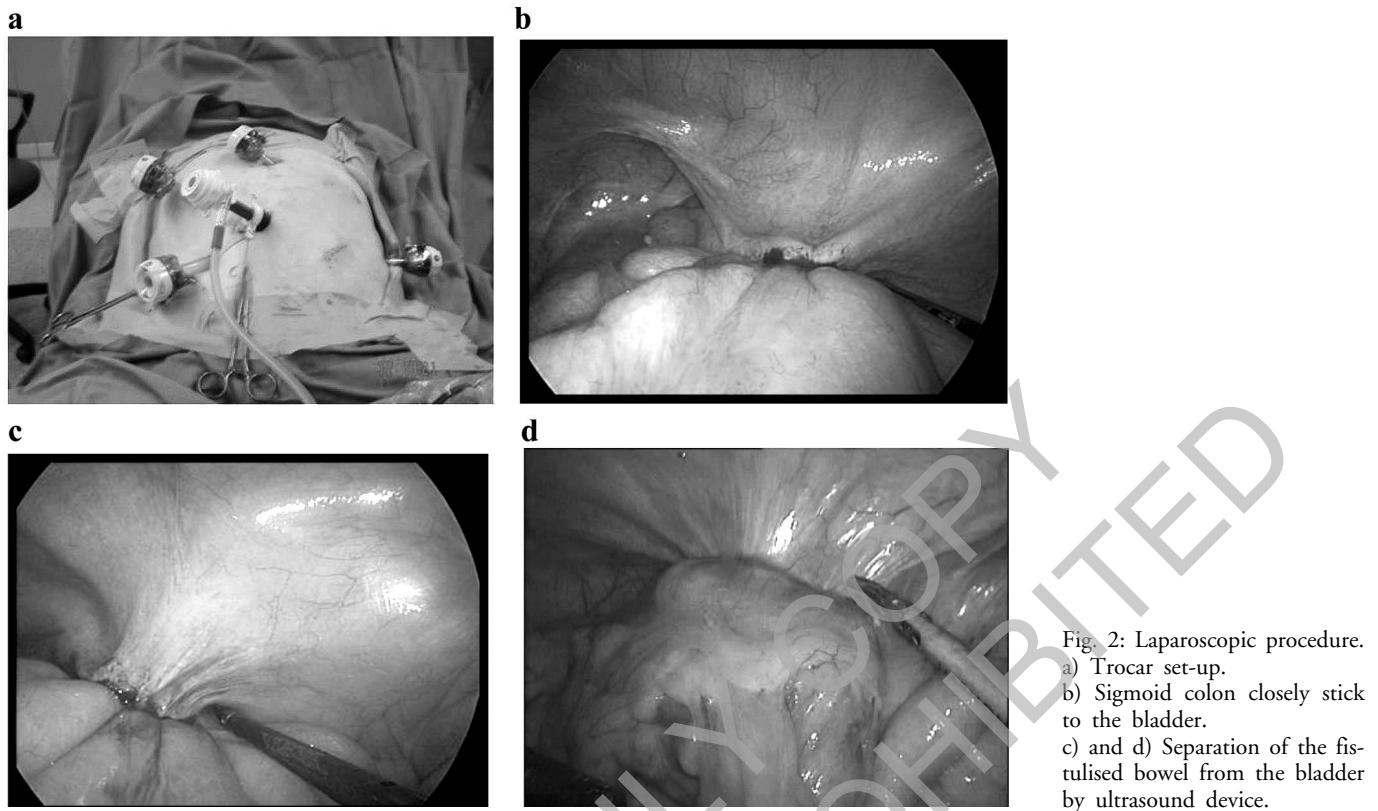


Fig. 2: Laparoscopic procedure.  
a) Trocar set-up.  
b) Sigmoid colon closely stick to the bladder.  
c) and d) Separation of the fistulised bowel from the bladder by ultrasound device.

TABLE I - Patient demographics and types of fistulas

No. of patients	M	F	Age (years)	Colovesical	Colovaginal
1	+		70	+	
2		*	78	*	
3	+		84	+	
4		*	83		*
5	+		83	+	
6		*	65	*	
7	+		67	+	
8	+		68	+	
9	+		87	+	
10		*	71		*
11		*	72	*	
12	+		76	+	
13	+		79	+	
14	+		35	+	
15	+		63	+	
16	+		46	+	
Total	11	5	Mean:70.2	14	2

+male, \*female

ileostomy and colostomy respectively and 1 Hartmann's procedure). In one case only a defunctioning colostomy was performed (Table II). About 14 patients with colovesical fistula, the vesical defect was treated by primary suture in 10 patients (71.4%), by partial resection of bladder in 3 patients (18.75 %), and in the patient

treated by defunctioning surgery, the fistula was left open to heal by secondary intention (Table II). In the two patients with colovaginal fistula the vaginal defect was closed with an absorbable suture (Table II). No patient treated by laparoscopic procedure was converted to open surgery. The complications included intraoperative left ureteral injury in one patient, anastomotic leak in another patient, wound infection in two patients, and one incisional hernia (Table II). One recurrent colovesical fistula and one death attributable to myocardial infarction was observed during the follow-up of  $4.4 \pm 1$  years (mean  $\pm$  SD), range of 2-7.5 years. None of the patients died for treatment related causes (Table II).

## Discussion

The colovesical and colovaginal fistulas are the most common types of fistula which complicate diverticular disease<sup>3,4,10</sup>. In fact, the colovesical fistula constitutes the 40.5% of all internal diverticular fistulas (range: 12.5-65)<sup>1,3,5-10,13</sup>. The sigmoid diverticulitis is the most frequent cause of colovesical and colovaginal fistulas, but they can also be due to malignancy, radiation therapy, pelvic surgery, Crohn's disease and trauma<sup>2,3,6,13-15</sup>. The colovesical fistulas are usually more common in men and the most women with colovesical and colovaginal fistulas had undergone a previous hysterectomy.<sup>5,11,13</sup> These observations support the theory that the body and

TABLE II - Surgical procedures, complications and recurrent fistulas. Follow-up  $4.4 \pm 1$  years (mean  $\pm$  SD); range 2-7.5 years

Operation	No. underwent	Vesical suture	Partial vesical resection	Vaginal suture	Complications	Recurrent fistulas		Deaths
						Colovesical	Colovaginal	
One-stage (open)	8	5	2	1	4*	1	–	–
One-stage (laparoscopy)	4	3	1	–	–	–	–	–
Two-stage (stoma)	2	1	–	1	1°	–	–	–
Hartmann's procedure	1	1	–	–	–	–	–	–
Defunctioning surgery	1	–	–	–	–	–	–	1**
Total	16	10	3	2	5	1	0	1

\*One wound infection, one incisional hernia, one anastomotic leak, and one left ureteral injury.

\*\* At three months.

°Wound infection.

fundus of the uterus may act as a protective barrier in women.<sup>5</sup> In our series the ratio male/female in colovesical fistula group is 11/3 with a clear predominance in male, and the 2 patients with colovaginal fistula had a previous hysterectomy. The colovesical and colovaginal fistulas tend not to close spontaneously or with medical treatment. Previous studies have shown that up to 75% of patients with colovesical fistulas untreated by surgery died from septic complications.<sup>12,14</sup> In the study of Karamchandani et al, 8 of 12 patients managed conservatively, died from septicaemia 1-4 years after diagnosis.<sup>16</sup> Therefore, the surgical management should be adopted whenever possible. The results obtained by initial surgical approaches to the management of colovesical and colovaginal diverticular fistulas suggest the fashioning of a proximal defunctioning colostomy, either as the sole intervention, or prior to any pelvic surgery.<sup>17</sup> However, whilst affording some relief in the symptoms, as reported by the patients, the most data demonstrates that the proximal defunctioning procedure often is not able to close the fistula or this occurs again once the colostomy has been reversed.<sup>12,14</sup> The defunctioning procedures are associated with greater complication rate and should be limited to high surgical risk patients.<sup>14</sup> Other reported surgical approaches about the management of these diverticular fistulas are the simple suture of the vesical/vaginal and colonic defects, and eventually the interposition of the omental flap with purpose to reduce the risk of the fistula recurrence (the omentum is a ideal substratum for the local cicatrization given its rich lymphatic and vascular network)<sup>18,19</sup>. This surgical procedure implies the persistence of the underlying diverticular disease with consequent high incidence of fistula recurrence. Over time, the evolution of surgical practice has suggested that the "gold standard" surgery consists in the removal of the diseased segment of the colon, as well as of the fistula, and this is essential to prevent recurrence and achieve the best results.<sup>14,15,20,21</sup> The options are an one-stage, two-stage or three-stage procedure.<sup>14</sup> In an elective setting and in most of cases of

Hinchey I and II, without the presence of peritonitis or sepsis, there is no evidence that the multiple-stage procedures have better results than single-stage operation. Similarly, no significant statistical difference in the rate of complications has been observed.<sup>14</sup> Many evidences suggest that one-stage segmental resection of the involved colon and primary anastomosis is feasible in the majority of cases of colovesical and colovaginal fistulas.<sup>2,13,14,21-23</sup> The distal resection must always be extended to the upper rectum below the promontory of the sacrum, beyond the sigma-rectum junction (high pressure zone) to avoid the risk of recurrence of the underlying disease. Differently, the proximal resection must be limited to grossly diseased segment of colon.<sup>5,13</sup> Moreover, clinical studies have recognized that large bowel obstructions distal to the fistulas contribute to keep these open.<sup>15</sup> Therefore, it is important the elimination by resection of possible strictures.<sup>15</sup> The use of a defunctioning ileostomy associated to primary anastomosis can be useful to prevent the high morbidity rate due to anastomotic leakage.<sup>24</sup> The Hartmann's procedure or the three-stage procedure are indicated in the cases of wide peri-diverticulitis and complicated diverticulitis in the III and IV Hinchey's stage. The three-stage operation is rarely performed, given the improvement in the years of the surgical technique, of the used devices and of the intensive and antibiotic therapy.<sup>2,8</sup> In our series, in an urgency setting for complicated diverticulitis in Hinchey III, 3 patients underwent to two-stage surgery, primary anastomosis with loop ileostomy, primary anastomosis with loop colostomy and Hartmann's procedure respectively. None of our patients underwent to three-stage procedure in urgency setting. The management of the fistulized organ can vary on the grounds of extent of the organ's defect. In some cases, the defect can have a dimension so small that it is not visible. In most of cases, the vesical defect can be treated effectively by repair with absorbable suture and omental interposition, minimal resection of the organ or conservative treatment by the only vesical catheter.<sup>13,15,25,26</sup> The partial cystecto-

my is necessary in a minority of patients. However, the bladder has to be drained with a Foley catheter for 7-10 post-operative days<sup>6,13,15,25</sup>. The vaginal defect can be close with direct suture and omental flap or left open to granulate and close by secondary intention<sup>2,5,6,27</sup>. The overall rate of complications from the surgery of colovesical fistulas has been reported to be between 6 and 49%<sup>13-15</sup>. This wide range in the rate of post-operative complications depends on the presence of comorbidity, type of surgical procedure performed and diverticular disease stage. It must be noted that the diverticular fistulas occur often in individuals with shoddy clinical conditions and long-term diverticular illness associated to high risk of post-operative complications. Garcea et al report a high complication rate (41.7%) and show that this rate is due to the high number of patients with comorbidity treated and mostly to the diversion surgical techniques, rather than to the resection followed by primary anastomosis.<sup>14</sup> However, in an elective setting, the surgical treatment of colovesical fistula by segmental resection of the diseased colon with primary anastomosis and minimal vesical repair is correlated to low rates of anastomotic leak and recurrent fistula (about 2.8% and 0-1% respectively)<sup>1,6,13-15,25,28</sup>. Our overall complication rate is 31.2% similar to the range reported in literature<sup>10,14,20</sup>. It is to note that between our complications there is an intra-operative ureteral left injury treated by suture and placing of J catheter. Some authors suggest the positioning of a double J catheter prior to surgery, in order to better identify the ureters in cases with severe inflammation, in which the ureteral injury is a concern<sup>29</sup>. We recorded at 6 months follow-up in one case, after one stage open surgery, a colovesical recurrent fistula. It is to underline that this recurrence occurred in a patient with post-operative anastomotic leakage. Therefore, this recurrent fistula is the consequence of surgical treatment and not of the recurrence of diverticulitis. As regards the post-operative mortality, several authors show that the colovesical fistulas occur in a group who are likely to die from other causes<sup>14,15</sup>. In our personal experience, only one patient with shoddy health and undergone to defunctioning colostomy died. This death is due to unrelated cause (myocardical infarction) three months after surgery. Traditionally, the diverticulitis complicated by fistulas is regarded as a contraindication to laparoscopic surgery. However, with the increase of the laparoscopic experiences, several reports about the feasibility of laparoscopic surgery have been published<sup>1,6,30</sup>. The presence of severe adhesions arising secondary to fistulas and/or previous hysterectomy, phlegmonous inflammation and abscess can interfere with safe of the laparoscopic dissection<sup>1,6</sup>. The conversion rate reported in literature in the diverticulitis complicated by fistula is of about 25%, differently, in the uncomplicated disease is of about 5-14%<sup>1,6,21,28,31-33</sup>. The colovaginal fistulas are associated with a higher conversion rate than other fistulas given the low pelvic side. Pokala et al report an overall con-

version rate of 32.6% in their series of 43 patients undergone elective laparoscopic surgery for enteric fistulas (24 diverticular fistulas).<sup>6</sup> In their report the conversion rate, when analyzed by fistulas type, is of 15.4% (2/13) and of 66.7% (4/6) in the colovesical and colovaginal fistulas respectively<sup>6</sup>. Nguyen et al report 5 cases of conversion at the open procedure out of 14 patients treated for diverticular fistulas (36%), but the most senior surgeon in the group had a low conversion rate (13%)<sup>1</sup>. Finally, the laparoscopy complication rate is entirely acceptable (~16%)<sup>1,28,32-34</sup>. In our series, 4 patients undergoing to laparoscopic surgery do not have had post-operative complications and recurrences of fistula.

## Conclusions

The overall analysis of our data and those of the literature demonstrates that: 1) It is now well established that the treatment for diverticular disease complicated by the presence of fistulas is surgical. 2) Many evidences suggest that one-stage procedure with primary anastomosis is effective in the majority of cases of diverticular fistulas. The use of a defunctioning ileostomy associated to primary anastomosis can be useful to prevent the anastomotic leakage. 3) A repair by primary suture or minimal resection of the vesical and vaginal defects can be demanded. 4) The surgery of colovesical and colovaginal fistulas is often related to high morbidity rates. This is due to the poor clinical conditions and long-term diverticular illness that frequently characterize this group of patients. 5) At present, in an elective setting, the laparoscopy is not considered any more a contraindication in the treatment of diverticular disease complicated by fistulas and it results safe and effective in many cases. As regards the conversion rates, these are acceptable but superior to those who there are in the uncomplicated diverticulitis. The conversion rates can decrease increasing the surgical experience and the evolution of instrumentation.

## Riassunto

La diverticolite del sigma è la più frequente causa di fistole enteriche. Il tasso d'incidenza delle fistole enteriche nella malattia diverticolare è di circa il 2-4% e può raggiungere il 20% nei pazienti sottoposti a chirurgia. La più comune fistola enterica è la colovesicale (60%) seguita dalla colovaginale (20%). Le fistole diverticolitiche colovesicali e colovaginali tendono a non chiudersi spontaneamente e un trattamento medico conservativo è spesso inefficace. Precedenti studi hanno evidenziato elevati tassi di mortalità (fino al 75%) in pazienti con fistole colovesicali non trattati chirurgicamente. Quando possibile, la chirurgia deve essere considerata il trattamento di scelta. Numerosi lavori hanno suggerito che la

resezione del tratto di colon patologico è essenziale per ridurre il rischio di fistole recidive e rappresenta il “gold standard” della chirurgia. Le opzioni chirurgiche sono la procedura in one-stage, in two-stage e in three-stage. In elezione e nella maggior parte dei casi Hinchey I e II non c'è evidenza che le procedure in più tempi abbiano risultati migliori di quella in one-stage. La letteratura ha ampiamente dimostrato come la tecnica in one-stage con resezione colica e anastomosi primaria è fattibile ed efficace nella maggioranza dei casi. L'uso di una stomia di protezione associata all'anastomosi primaria si è dimostrato utile nel prevenire l'anastomotico leakage. L'intervento di Hartmann o la procedura in three-stage sono indicati nei casi di diverticolite complicata in stadio III e IV di Hinchey. L'intervento in three-stage è raramente eseguito, grazie al miglioramento negli anni della tecnica chirurgica, dei devices usati e della terapia intensiva e antibiotica perioperatoria. Il trattamento dell'organo fistolizzato può variare in base alle dimensioni della fistola. In alcuni casi, il difetto può essere di dimensioni talmente piccole da non essere visibile. Per quanto riguarda il difetto vescicale, questo può essere, nella maggior parte dei casi, trattato efficacemente mediante sutura con filo riassorbibile, minima resezione vescicale o in maniera conservativa con posizionamento del solo catetere vescicale. È buona regola mantenere il catetere vescicale per almeno 7-10 giorni nel postoperatorio. Il difetto vaginale può essere suturato e protetto con flap omentale o lasciato aperto con chiusura per seconda intenzione. Tra il 2005 e il 2011, nei nostri centri, 16 pazienti sono stati sottoposti a chirurgia per malattia diverticolare complicata da fistole (11 maschi e 5 femmine) con un'età media di 70 anni.

Complessivamente, sono state trattate 14 fistole colovesicali e 2 colovaginali. In 4 pazienti con fistola colovesicale è stata eseguita una chirurgia laparoscopica. In elezione, sono stati trattati 12 pazienti mediante resezione del tratto di colon malato e il confezionamento di un'anastomosi primaria in one-stage (8 interventi open e 4 laparoscopici). In urgenza, 3 pazienti sono stati sottoposti a chirurgia in two-stage (2 anastomosi primarie con confezionamento rispettivamente di ileostomia e di colostomia di protezione e 1 procedura di Hartmann). Solo in un caso è stato eseguito un intervento derivativo con colostomia. Il difetto vescicale è stato trattato mediante sutura in 10 casi (con tecnica laparoscopica in 4 pazienti) e resezione parziale della vescica in 3 casi mentre, nel paziente con intervento derivativo, è stato lasciato aperto con chiusura per seconda intenzione. In entrambe le pazienti con fistola colovaginale, il difetto vaginale è stato chiuso con sutura con filo riassorbibile. In letteratura il tasso di complicanze riportato della chirurgia delle fistole colovesicali è tra il 6 e il 49%. Questo ampio range nell'incidenza di complicanze postoperatorie dipende dalla presenza di comorbidità, dal tipo di procedura chirurgica adottata e dallo stadio di malattia. E' da sottolineare comunque il basso tasso di anasto-

motico leak e recidiva di fistola (rispettivamente di circa il 2,8 e 0-1%) nei pazienti con fistola colovesicale trattati in elezione mediante la procedura one-stage con sutura vescicale. Il nostro tasso di complicanze complessivo è del 31,2% rientrando nel range riportato in letteratura, mentre in un solo paziente con fistola colovesicale, sottoposto a chirurgia one-stage in open, abbiamo avuto una recidiva di fistola [follow-up:  $4,4 \pm 1,6$  anni (media  $\pm$  DS), range di 2-7,5 anni]. Attualmente la tecnica laparoscopica non è più controindicata nei pazienti con malattia diverticolare complicata da fistole. Molti reports hanno infatti dimostrato la fattibilità, sicurezza ed efficacia dell'approccio laparoscopico per il trattamento delle fistole diverticolitiche con un tasso di conversione accettabile anche se superiore a quello riportato nella malattia diverticolare non complicata (25% vs 5-14%) e un'incidenza di complicanze di circa il 16%. Nella nostra casistica, i quattro pazienti trattati con chirurgia laparoscopica non hanno avuto complicanze postoperatorie e fistole recidive.

## References

1. Nguyen SQ, Divino CM, Vine A, Reiner M, Katz LB, Salky B: *Laparoscopic surgery for diverticular disease complicated by fistulae*. JSLS, 2006; 10:166-68.
2. Bahadursingh AM, Longo WE, Rayburn WF: *Colovaginal fistulas. Etiology and management*. J Reprod Med, 2003; 48: 489-95.
3. Najjar SF, Jamal MK, Savas JF, Miller TA: *The spectrum of colovesical fistula and diagnostic paradigm*. Am J Surg, 2004; 188: 617-21.
4. Cross SB, Copas PR: *Colovaginal fistula secondary to diverticular disease. A report of two cases*. J Reprod Med, 1993; 38: 905-06.
5. Finco C, Sarzo G, Parise P, Savastano S, De Lazzari F, Polato F, Merigliano S: *Laparoscopic treatment of post-hysterectomy colovaginal fistula in diverticular disease. Case report*. Minerva Chir, 2004; 59: 301-05.
6. Pokala N, Delaney CP, Brady KM, Senagore AJ: *Elective laparoscopic surgery for benign internal enteric fistulas: a review of 43 cases*. Surg Endosc, 2005; 19: 222-25.
7. Titu LV, Zafar N, Phillips SM, Greenslade GL, Dixon AR: *Emergency laparoscopic surgery for complicated diverticular disease*. Colorectal Dis, 2009; 11: 401-04.
8. Vasilevsky CA, Belliveau P, Trudel JL, Stein BL, Gordon PH: *Fistulas complicating diverticulitis*. Int J Colorectal Dis, 1998; 13: 57-60.
9. Young-Fadok TM, Roberts PL, Spencer MP, Wolff BG: *Colonic diverticular disease*. Curr Probl Surg, 2000; 37: 457-514.
10. Woods RJ, Lavery IC, Fazio VW, Jagelman DG, Weakley FL: *Internal fistulas in diverticular disease*. Dis Colon Rectum, 1988; 31: 591-96.
11. Grissom R, Snyder TE: *Colovaginal fistula secondary to diverticular disease*. Dis Colon Rectum, 1991; 34: 1043-49.

12. Amin M, Nallinger R, Polk HC: *Conservative treatment of selected patients with colovesical fistula due to diverticulitis*. Surg Gynecol Obstet, 1984; 159: 442-44.
13. Melchior S, Cudovic D, Jones J, Thomas C, Gillitzer R, Thüroff J: *Diagnosis and surgical management of colovesical fistulas due to sigmoid diverticulitis*. J Urol, 2009; 182: 978-82.
14. Garcea G, Majid I, Sutton CD, Pattenden CJ, Thomas WM: *Diagnosis and management of colovesical fistulae; six-year experience of 90 consecutive cases*. Colorectal Dis, 2006; 8: 347-52.
15. Walker KG, Anderson JH, Iskander N, McKee RF, Finlay IG: *Colonic resection for colovesical fistula: 5-year follow-up*. Colorectal Dis, 2002; 4: 270-74.
16. Karamchandani MC, West CF: *Vesicoenteric fistulas*. Am J Surg, 1984; 147: 681-83.
17. Mayo CW, Miller JM: *Surgical treatment of sigmoidovesical fistulas*. Arch Surg, 1940; 40: 897-901.
18. O'Leary DP: *Use of the greater omentum in colorectal surgery*. Dis Colon Rectum, 1999; 42: 533-39.
19. Lewis SL, Ambercrombie GF: *Conservative surgery for vesicocolic fistula*. J Royal Soc Med, 1984; 77: 102-04.
20. Shatila AH, Ackerman NB: *Diagnosis and management of colovesical fistulae*. Surg Gynaecol Obstet, 1976; 143: 70-74.
21. Tonelli F, Di Carlo V, Liscia G, Serventi A: *La malattia diverticolare del colon: quando e come trattarla*. Consensus Conference al 5° Congresso Nazionale della Società Italiana dei Chirurghi Universitari (S.I.C.U.). Ann Ital Chir, 2009; 80: 3-8.
22. McBeath RB, Schiff M, Allen V, Bottaccini MR, Miller JJ, Ehreth J: *A 12-year experience with enterovesical fistulas*. Urology, 1994; 44: 661-65.
23. Moreaux J, Vons C: *Elective resection for diverticular disease of the sigmoid colon*. Br J Surg, 1990; 77: 1036-38.
24. Smeenk RM, Plaisier PW, van der Hoeven JA, Hesp WL: *Outcome of surgery for colovesical and colovaginal fistulas of diverticular origin in 40 patients*. J Gastrointest Surg, 2012; 16: 1559-65.
25. Ferguson GG, Lee EW, Hunt SR, Ridley CH, Brandes SB: *Management of the bladder during surgical treatment of enterovesical fistulas from benign bowel disease*. J Am Coll Surg, 2008; 207: 569-72.
26. Fiori R, Izzo L, Forcione A, Bolognese A, Izzo S, Nano G, Di Poce I, Simonetti G: *Colovesical fistula in sigmoid diverticulitis. A case report*. Ann Ital Chir, 2013; 84: 477-81.
27. Livengood CH 3<sup>rd</sup>: *Colovaginal fistula. Report of a case with failure of transvaginal repair*. J Reprod Med, 1996; 41: 291-93.
28. Bartus CM, Lipof T, Sarwar CM, Vignati PV, Johnson KH, Sardella WV, Cohen JL: *Colovesical fistula: not a contraindication to elective laparoscopic colectomy*. Dis Colon Rectum, 2005; 48: 233-36.
29. Yang HY, Sun WY, Lee TG, Lee SJ: *A case of colovesical fistula induced by sigmoid diverticulitis*. J Korean Soc Coloproctol, 2011; 27: 94-98.
30. Puente I, Sosa JL, Desai U, Sleeman D, Hartmann R: *Laparoscopic treatment of colovesical fistulas: technique and report of two cases*. Surg Laparosc Endosc, 1994; 4: 157-60.
31. Köckerling F, Schneider C, Reymond MA, Scheidbach H, Scheuerlein H, Konradt J, Bruch HP, Zornig C, Köhler L, Bärlechner E, Kuthe A, Szinicz G, Richter HA, Hohenberger W: *Laparoscopic resection of sigmoid diverticulitis. Results of a multicenter study*. Laparoscopic colorectal surgery study group. Surg Endosc, 1999; 13: 567-71.
32. Bouillot JL, Berthou JC, Champault G, Meyer C, Arnaud JP, Samama G, Collet D, Bressler P, Gainant A, Delaitre B: *Elective laparoscopic colonic resection for diverticular disease: results of a multicenter study in 179 patients*. Surg Endosc, 2002; 16: 1320-23.
33. Menenakos E, Hahnloser D, Nassiopoulou K, Chanson C, Sinclair V, Petropoulos P: *Laparoscopic surgery for fistulas that complicate diverticular disease*. Langenbecks Arch Surg, 2003; 388: 189-93.
34. Franklin ME, Dorman JP, Jacobs M, Plasencia G: *Is laparoscopic surgery applicable to complicated colonic diverticular disease?* Surg Endosc, 1997; 11: 1021-25.