

The treatment of the ears with advanced pathology using a composite graft of perichondrium and cartilage



Ann. Ital. Chir., 2009; 80: 281-285

Konstantinos Bogris*, Nikolaos Sylligardakis*, Nikolaos Stavropoulos*, Nicolas Condilis**, Irimi Kalogridaki**

*ENT - Head and Neck Surgeons; **Family Medicine Department, Nikaia General Hospital "Saint Panteleimon" Greece.

The treatment of the ears with advanced pathology using a composite graft of perichondrium and cartilage

In ears with advanced pathology the functional and anatomical results of a surgical procedure depend on factors such as total perforation, tympanosclerosis, Atelectasis, Suppuration or possibility a previous operation. A Perichondrium-Cartilage Composite Graft (PCCG) was used to repair the tympanic membrane by a total of 350 cases over a five-year period in total, 157 type I tympanoplasty procedures (15% with previous surgery) and 193 type III procedures (52% with previous surgery) were carried out. The graft was obtained from the tragus and/or the conchal cartilage.

Two slightly different surgical techniques were used.

Closure of the perforation in the tympanic membrane was successful in 94% of the procedures. An ≤ 30 dB in 79% of the type III procedures. In conclusion, the PCCG is a reliable graft in cases of advanced middle ear damage

KEY WORDS: Perichondrium-cartilage composite graft, Tympanoplasty, Tympanic membrane.

Introduction

Since 1952, various methods and materials have been promoted for grafting in tympanoplasty procedures. Fascia of the temporal muscle remains the most commonly used material for correcting an imperfection in the tympanic membrane. This material has proved reliable in a large number of cases, but certain tympanoplasty procedures are complicated by advanced middle ear pathology^{1,2}.

With the passage of time middle ear otosclerosis or fibrosis may develop. Eustachian tube dysfunction may cause the development of retraction pockets or atelectasis of the middle ear. Blunting and lateralization may appear as the result of a previous operation^{3,4}.

Both the perichondrium and the cartilage, like fascia, are formed from mesoderm, though the former is thicker and more rigid. It is that later quality that led us to use a perichondrium-cartilage composite graft (PCCG) to reconstruct the eardrum or the posterior canal wall⁵⁻⁷.

Material and methods

In a series of 2335 tympanoplasties carried out within a five-year period we used a PCCG in 350 cases. All the ears had one or more of the aggravating factors that are listed in Table I. Two main invasive techniques were used: the palisade, using strips of cartilage coated on both sides with perichondrium, as first described by Heermann, and the perichondrium-cartilage islet (PCI) technique, using a similar approach to that described by Eviatar (1978), Glasscock et al. (1982), and Adkins (1990)^{8-10,15}.

In the palisade technique the cartilage from concha or tragus was removed with the perichondrium on both sides. After removal of the perichondrium from one side the PCCG was cut into strips. Provided the remaining anatomy of the middle ear was intact, the PCCG strips were placed using the underlay technique in close contact with each other, with the cartilage towards the tympanic cavity and the perichondrium towards the external auditory canal⁸. If we had to deal with a total perforation or a missing malleus the first cartilaginous "support" was placed in the center, bridging the TORP or the PORP and holding it in place. The next cartilaginous "supports" were trimmed to a suitable size for closing the perforation (Fig. 1). We took special care to ensure that the strips of cartilage were not placed one

Pervenuto in Redazione Settembre 2004. Accettato per la pubblicazione Novembre 2005.

Per la corrispondenza: Dr. Kostantinos Bogris, Zografou 13, 1201 Heraklion, Crete, Greece (e-mail: bogrisk@ath.forthnet.gr).

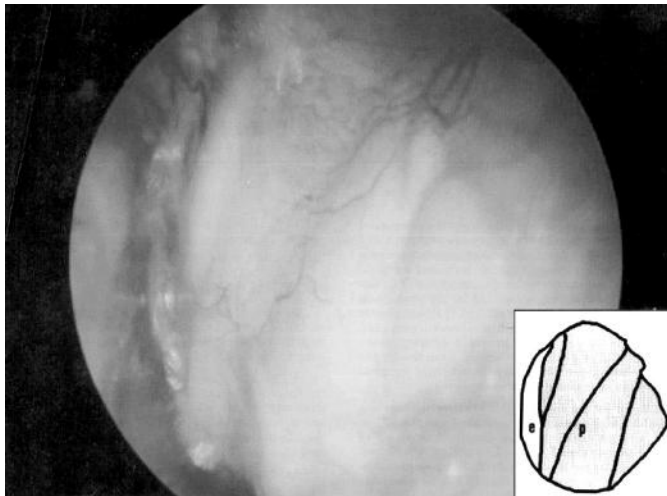


Fig. 1: Left ear: Tympanoplasty type III. Cartilage palisades (C P) technique, 6 months after surgery of total perforation. Eardrum reconstructed by cartilage palisades.

Inset: Sketch of the reconstructed area of the eardrum. p = cartilage palisades lying close together, in one layer, without overlapping, with adherent perichondrium on both sides, e = anterior part of the eardrum.

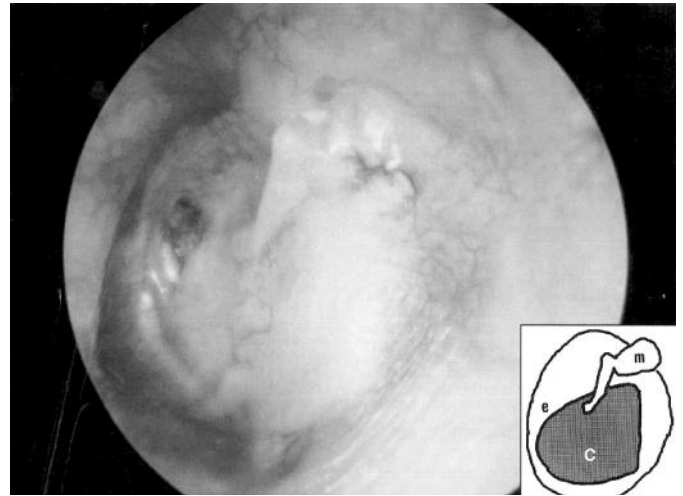


Fig. 2: Left ear: Tympanoplasty type III, perichondrium cartilage islet (PCI) technique, 6 months after surgery of subtotal perforation and tympanosclerosis. Cartilage Island used to reconstruct central and antero-inferior parts of the tympanic membrane.

Inset: Sketch of the reconstructed eardrum. c = cartilage island, m = malleus, e = anterior part of the eardrum.

on top of the other but were in close contact. In cases with complete perforation, where the annulus was also missing, the strips were placed so as to converge with each other, closing the osseous sulcus of the annulus. The part of the perichondrium that was removed initially could be used as an additional graft in order to protect and reinforce the cartilage-bone connection.

In the PCI technique, the cartilage was taken from the tragus with the perichondrium on both sides. For cosmetic reasons, a small strip of cartilage (2 mm) was always left in the dome of the tragus. The perichondrium was raised from the surface and folded back, like opening a book. When necessary the cartilage was counterbalanced by a semisharp instrument. The insular graft was placed using the underlay technique with the islet of cartilage facing the curvature of the eardrum, stabilizing the graft at the point of imperfection of the tympanic membrane^{11,12} (Fig. 2).

In the case of complete perforation or an absent malleus, the PCCG techniques were used to recreate the concavity of the eardrum, providing a stable anchor for TORPs or PORPs. If the middle ear ventilation was poor, the cartilage stabilized the graft, preventing the collapse of the cavity¹⁴.

In cholesteatoma surgery, as much of the posterior canal wall was removed as necessary for exposure and removal of the matrix. The resulting defect of the canal wall was reconstructed by PCCG¹³.

In radical mastoidectomies the PCCG was used to cover imperfections in the tympanic membrane, while small fragments of cartilage were used to eliminate the large cavity that was created¹⁵ (Fig. 3).

If the damage to the ossicular chain or the extension of

the cholesteatoma required bridging of the lesion, homografts or glass-ceramic implants were used.

The graft and the external auditory canal wall were covered with strips of silicon (0.1 mm thick), the ear was covered with a gelatin sponge soaked in tetracyclin (Vibramycin). The dressing was removed after three weeks¹⁷.

The preoperative audiogram was recorded one week prior to surgery. Postoperatively, all the patients returned after three weeks for dressing removal and were followed up at six weeks, three months, six months and once per year for the remaining years with an audiometric examination. In cases with development of granulomatous tissue, delayed epithelization, infection, or other problems, additional visits were programmed. The mean follow up was 1.2 years. A minimum of 6 months was required for inclusion into this study. Two groups of patients were analyzed separately: those who underwent type I procedures and those who underwent type III¹².

The air-bone conduction gap was calculated by subtracting the lowest boundary of bone conduction from the lowest boundary of air conduction at each frequency. Given that acoustic function at higher frequencies is important for social hearing, the mean air-bone conduction was measured at 500, 1000, 2000, 4000 and 8000 Hz on the tonic audiogram¹².

The hearing evaluation before and after operation was computer-assisted. Four categories were chosen:

1. Air-bone conduction gap <10 dB: normal hearing.
2. Air-bone conduction gap 11-30 dB: social hearing without amplification (i.e. can use the telephone).
3. Air-bone conduction gap 31-50 dB: social hearing needing amplification.

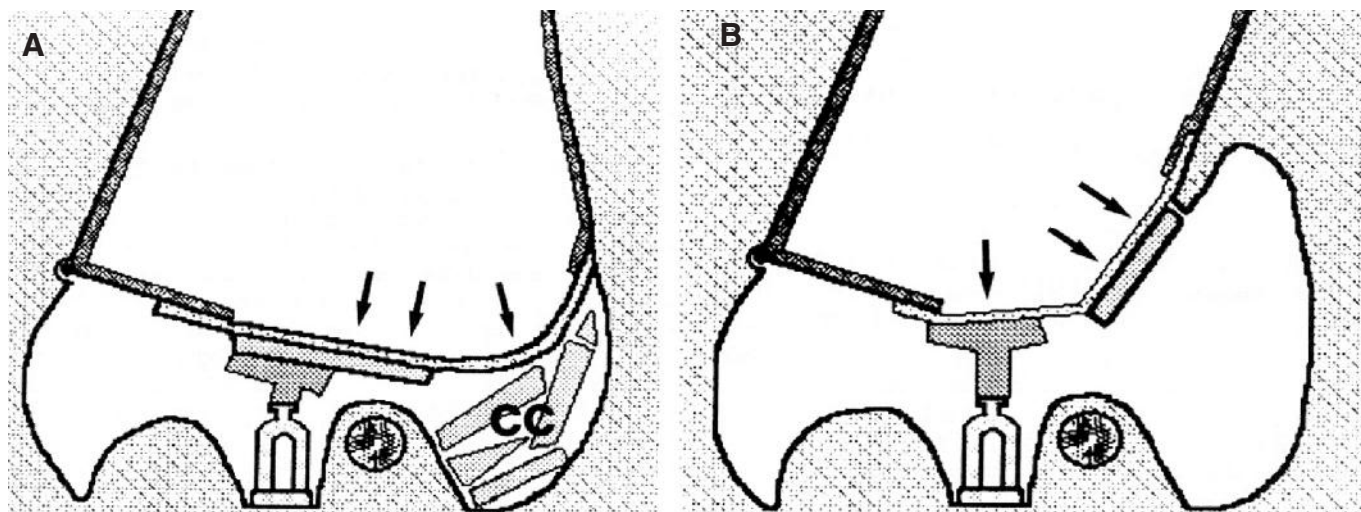


Fig. 3: A: Radical cavity after a radical mastoidectomy. The established cavity was covered with pieces of cartilage (CC). A shallow tympanic cavity is being reconstructed by a PCI (double arrow). The cartilage pieces are covered with the perichondrium of the graft (single arrow). B: Reconstruction of the posterior canal wall after the removal of cholesteatoma. The PCI covers the missing wall (double arrow) and the perichondrium is reconstructing the eardrum (single arrow).

4. Air-bone conduction gap >50 dB: social deafness. A hearing aid may provide some small benefit to the ear.

Results

FUNCTIONAL RESULTS

Of the 350 patients who underwent surgery the postoperative audiological examination found that 329 (94%) were improved or unchanged, while only 21 patients (6%) showed a worsening of their hearing deficit. In no case did sensorineural hearing loss occur in our patients. Type I tympanoplasty was performed in 157 cases with perforation of the tympanic membrane or the creation of retraction "pockets" in the eardrum, with an intact ossicular chain but complicated by at least one of the factors given in Table I. Fifteen percent of the type I procedures were reoperations.

In 47.3% of the type I tympanoplasty cases we had recovery of normal hearing. In less than 46% of cases there remained an air-bone conduction gap of 11-30 dB and in only 6.7% was there a residual air-bone conduction gap between 31 and 50 dB (Table II).

Type III tympanoplasty was performed in 193 cases where there was chronic otitis media with or without cholesteatoma and in combination with a varying degree of destruction of the ossicular chain. Fifty eight (30%) of these 193 cases needed reconstruction of the posterior wall of the external auditory canal. In 46 patients (24%) radical mastoidectomy was carried out, with partial obliteration of the resulting cavity (Fig. 3). Eighty three (43%) of the 193 patients had undergone previous surgery.

TABLE I

Complicating Factors of Tympanoplasty:

Total perforation
Missing malleus
Perforation above the tubal orifice Tympanosclerosis
Blunting
Lateralization
Atelectasis of the middle ear
Second revision

TABLE II

Preoperative - Postoperative Air-Bone Gap Number of Ears
0-10dB 20 (12.5%) - 74 (47.3%), 11-30 dB 104 (66.3%) - 72 (46%), 31-50 dB 33 (21.3%) - 11 (6.7%), >50 dB 1 (0.5%) O

The postoperative audiological results from the cases that needed type III tympanoplasty are given in Table III. That table includes cases with faulty surgical technique, extrusion, re-perforation, blunting, lateralization, or radical cavity. Seventy-nine percent of the cases had a mean air-bone conduction gap \leq 30 dB after the operation, compared with 53.8% before.

ANATOMIC RESULTS

Closure of the perforation was achieved in 96.5% (type III) and 91.5% (type I) of cases. When the surgical procedure was carried out on inflamed ears the number of recurrent perforations increased to 28% (type I) and 11% (type III). Forty one (21.3%) of the cases who needed type III tympanoplasty showed delayed healing with the development

of granulomatous tissue, either in the tympanic cavity or in the external auditory canal. In 25 (13%) of the type III cases one additional examination was needed during the first six weeks after surgery, while in 15 (7.8%) two such examinations were needed.

Discussion

The PCCG stands out as a renaissance in ear surgery. The graft is easily obtained, with little or no cosmetic deficit in the region from which it is removed. It may easily be trimmed to the exact size needed and the inherent rigidity of the cartilage helps in its manipulation and placement. The graft is stable and reliable for the handling of retraction "pockets" and dealing with complete perforations or perforations above the tubal opening. We saw no blunting or lateralization in our cases.

In cholesteatoma surgery PCCG grafting allows the removal of the osseous wall of the canal for a check of the pathology without producing a permanent cavity. Since the perichondrium-cartilage islet does not cover all parts of the tympanic concavity, recurrent cholesteatoma is easy to detect.

The effect of inflammation on the anatomic results continues to be controversial in the international literature. Goodhill considers that one of the main causes of unsuccessful tympanoplasty is necrosis of the graft from infection¹⁶. Glasscock et al. reported that in their experience the majority of premature failures were related to infection, probably exacerbated by the extensive middle ear pathology¹⁰. In contrast, from reports by other authors we found that the incidence of perforation recurrence is more than double that of infection. The graft materials appear to make no difference. In 1988 the same incidence of infection was also reported for temporal fascia grafts used in tympanoplasty^{6,7,19}.

Restoration of the air-bone conduction gap to a level ≤ 30 dB was achieved in 78% of the cases who needed type III tympanoplasty and in 92.4% of those who needed type I. Those numbers include all the cases with one or more prior operations, those with recurrence of the perforation or any other condition that necessitated reoperation. Each case had at least one of the aggravating factors referred to above (Table I).

Under those circumstances the hearing results are quite acceptable. As expected, the group of tympanoplasties with damage to the ossicular chain had a poorer improvement in hearing (Table III). In a one-year follow up of 255 patients, Eviatar achieved a postoperative result with an air-bone conduction gap of the order of 10 dB in 76% of patients⁹. Because of the extensive middle ear pathology the results of this study are not so good. Levinson published a retrospective study of 85 cases with retraction "pockets" treated using cartilage-perichondrium islet grafts. Of those patients 66% had an air-bone conduction gap of the order of 10 dB and 95% had an

TABLE III

Hearubg Gain for Tympanoplasty Type III (n = 193)	
Preoperative – Postoperative Air-Bone Gap Number of Ears	
0-10dB	5 (2.6%) – 38 (19.8%),
11-30 dB	93 (48.2%) – 114 (59.2%),
30-50 dB	79 (41.1%) – 35 (18.2%),
>50 dB	6 (3.2%) – 1 (0.6%)

air-bone conduction gap below 30 dB, a comparable result to our own¹³. Adkins reported a success rate of 96% in 179 cases treated using cartilage-perichondrium islet grafts, but the authors didn't publish any audiological results. Postoperative care is an important factor in the optimization of outcomes from surgical tympanoplasty procedures, in facilitating epithelization of the graft^{15,18}. Curiously, this is one fact that is hardly mentioned in the literature.

In our series, the need for subsequent treatment because of delayed graft epithelization and development of granulation tissue was low, even in radical cavities. Seventy eight point two percent of the ears in this study were uneventfully healed after the dressing removal. In only 20,8% was additional care needed once or twice.

Conclusions

Before surgery the problem to be treated must be examined and classified. This helps us to reach a decision about the type of graft that should be used. The cartilage and perichondrium are most likely to withstand the first few days of bad perfusion and tubal dysfunction. In ears destroyed by advanced disease, we prefer the cartilage-perichondrium islet graft. Both grafting techniques are important tools in cases of complicated tympanoplasty.

Riassunto

In orecchie affette da patologia in fase avanzata, i risultati anatomici e funzionali di un intervento chirurgico, dipendono da fattori quali la perforazione completa della membrana timpanica, la sclerosi, l'attelectasia, l'empiema della membrana timpanica od eventualmente le recidive di un pregresso intervento chirurgico. Il trapianto insulare di cartilagine – pericondrio è stato utilizzato come materiale d'elezione per la ricostruzione di perforazioni della membrana timpanica in 350 pazienti in un intervallo di tempo di ben cinque anni (1998-2002). In totale, abbiamo eseguito 157 timpanoplastiche di tipo I, e 193 di tipo III. Il materiale da trapiantare fu prelevato dal trago od/ed dalla cartilagine della conca. Sono state utilizzate due tecniche operatorie leggermente diverse tra loro.

La ricostruzione e la chiusura della membrana timpanica perforata, venne ottenuta nel 94% degli interventi eseguiti.

ti. Nel postoperatorio, il gap della coduzione via ossea – via aerea del suono era uguale od inferiore di 30 dB e mostrò netto miglioramento o rimaneva uguale nell'93.3% degli interventi di timpanoplastica di tipo I, invece il gap della coduzione via ossea – via aerea del suono era uguale od inferiore di 30 dB nell'79% in quelli di tipo III. In base a quanto riportato, si conclude che il trapianto insulare di cartilagine – pericondrio, risulta un materiale valido ed affidabile nel tentativo di trattamento chirurgico di patologie dell'orecchio medio, in fase evolutiva avanzata.

References

- 1) Wullstein HL: *Functionelle Operationen im Mittelohr mit Hilfe DCA freien Spaltlappentransplantates*, Arch Otorhino-Laryngol, 1952; 161:37-34.
- 2) Zollner F: *The principles of Plastic Surgery of the sound-conducting apparatus*. J Laryngol Otol, 1955; 69:657-59.
- 3) Wullstein HL: *Operationen zur Verbesserung des Gehors*. Stuttgart: Thieme Verlag, 1951.
- 4) Helms J: *Die Wiedreherstellung der Schalleitungskette*. HNO, 1983; 31:37-44.
- 5) Fleeter D: *Myringoplastic methods*. Arch Otolaryngol, 1963; 78:310-14.
- 6) Pala T: *Surgical treatment of chronic middle ear disease*. Mta Otolaryngol, (Stockh), 1987; 104:279-84.
- 7) Tos M: *Revision tympanoplasty*. J Laryngol Otol, 1986; 100: 1097-105.
- 8) Heermann J: *Auricular cartilage palisade. Tympano-Epi-tymoano-Antrum and mastoid plastics*. Clin Otorlaryngol, 1978; 3:433-46.
- 9) Evitar A: *Tragal perichondrium, and cartilage in reconstructive surgery*. Laryngoscope, 1978; 88(Suppl II):1-23.
- 10) Glasscock ME III, Jackson CG, Nisson AJ et al: *Post-auricular undersurface tympanic membrane grafting: A follow-up*. Laryngoscope, 1982; 92:718-27.
- 11) Milewski GH: *Fascia or perichondrium/cartilage in tympanoplasties. A comparative study regarding hearing results and recurrence of perforations in 1529 cases*. In: Tos M, Thomsen J, Petersen R: *Cholesteatoma and Mastoid Surgery*. Amsterdam: Kugler & Ghedini Publ, 1989; 1112-114.
- 12) Levinson RM: *Cartilago-perichondrial composite graft tympanoplasty in the treatment of posterior marginal and attic retraction pockets*. Laryngoscope, 1987; 97:1069-074.
- 13) Luetje CM, Denninghoff JS: *Perichondrial attached double cartilage block; A better alternative to the PORP*. Laryngoscope, 1987; 97:1106-108.
- 14) Adkins WY: *Composite autograft of tympanoplasty and Tympanomastoid surgery*. Laryngoscope, 1990; 100:24-47.
- 15) Goodhill V: *Tragal perichondrium and cartilage in tympanoplasty*. Arch Otolaryngol, 1967; 85:35-47.
- 16) McCleve DE: *Tragal cartilage reconstruction of the auditory canal*. Arch Otolaryngol, 1969; 90:274-74.
- 17) Adkins WY, White P: *Type I tympanoplasty influencing factors*. Laryngoscope, 1984; 94:916-18.
- 18) Ophir D, Porat M, Marshak G: *Myringoplasty in the pediatric population*. Arch Otolaryngol Head Neck Surg, 1987; 113: 1288-290.
- 19) Lesinski SG: *Homograft tympanoplasty in perspective. A long-term clinic. An Histologic Study of formal in-fixed tympanic membranes used for the reconstruction of 125 severely damaged middle ears*. Laryngoscope, 1983; 93(Suppl 321):1-37.
- 20) Claes J, van de Heyning PH, Creten W, et al: *Allograft tympanoplasty: Predictive value of preoperative status*. Laryngoscope, 1983; 100:1313-318.
- 21) Giannacopoulos N, Milewski CH: *Ergebnissenach Tympanoplastik bei entzundeten Ohren*. Arch Otorhinolaryngol, 1991; 248(Suppl 111):243-44.

