

Poland syndrome: an algorithm to select the appropriate chest wall surgical reconstructive treatment



Ann. Ital. Chir., 2014 85: 237-243
pii: S0003469X14021319

Stefano Chiummariello, Alessandra Pica, Giuseppe Guarro, Sergio Arleo, Carmine Alfano

Division of Plastic, Reconstructive and Aesthetic surgery (Chair: Prof. C. Alfano), University of Perugia, Perugia, Italy

Poland syndrome: an algorithm to select the appropriate chest wall surgical reconstructive treatment

AIM: Poland syndrome is a constellation of rare congenital anomalies of the chest wall, with or without alterations to the ipsilateral superior extremity. Actually Foucras' classification is commonly used to choose the most appropriate surgical treatment, but often only a radiological classification proves unsatisfactory in order to achieve the best aesthetic result.

MATERIAL AND METHODS: Since November 2006 in our institute have been treated 6 patients (3 M, 3 F) with Poland Syndrome affected by only chest wall and/or breast deformities.

RESULTS: We treated 6 patients opting for different surgical procedures, depending on the deformity detected. We experienced only one procedural complication, a fat necrosis with superior migration of the prosthesis, successfully managed.

DISCUSSION: Surgical alternative treatments of the Poland's abnormalities of the chest wall are independent from the corrective surgery of the ipsilateral affected forearm and hand. Surgeons should be able to develop an operative plan to address aesthetic goals while preserving muscular functionality. Indeed surgical techniques should be minimally invasive and possible available in every hospital structure.

CONCLUSIONS: This study has been designed to review a series of surgical options of breast reconstruction in patients with Poland Syndrome in order to develop a new flow chart to plan the best surgical choice analyzing only breast/chest wall deformities according to Blondeel's point of view about reconstruction of the new breast and thoracic wall.

KEY WORDS: Breast reconstruction, Poland syndrome

Introduction

Poland syndrome is a constellation of rare congenital anomalies of the chest wall, with or without alterations to the ipsilateral superior extremity. Alfred Poland, in 1841, for the first time published a report about the

syndrome that bears his name. Later Clarkson coined the eponym Poland's syndactyly and Baudinne referred to the complex as Poland syndrome ^{1,2}.

Its frequency is about 1 in 30.000 live births ^{3,4} and often the right side is the one being affected.

Poland syndrome generally consists of aplasia of the sternocostal portion of the pectoralis major muscle, hypoplasia or absence of the breast, limited subcutaneous chest wall fat, abnormalities or absence of one or multiple ribs with chest wall depression, axillary alopecia, potential absence of latissimus dorsi muscle, hypoplasia of muscles of the limb and brachysyndactyly. It may be unilateral or, rarely, bilateral, sporadic or familial ⁵.

The majority of patients with Poland Syndrome are only affected by aesthetic deformities while muscle disfunctions are usually covered by residual non affected mus-

Pervenuto in Redazione Gennaio 2013. Accettato per la pubblicazione Giugno 2013.

Correspondence to: Alessandra Pica, MD, Via Plinio il Vecchio 3, 80053 Castellammare di Stabia (Napoli), Italy (E-mail: pica.alessandra@gmail.com)

cles. That's why surgeons' primary objective is to reach symmetry of the chest wall.

Preoperative consultation is a good opportunity to examine thoracic wall. A good surgeon has to analyze, both in male and female patients, breast footprint, breast conus and its skin envelope and areola-nipple complex bilaterally.

Breast footprint is the outline that the breast makes on the chest wall and forms the basis of the overlying three-dimensional structure of the breast ⁶. It is related to anatomical structures as pectoral muscles and anterior axillary line for example.

The footprint takes a gentle curve starting from the pectoralis tendon extending till the anterior axillary line and there is a transition of its lateral part into the inframammary fold. If there are deformities of the ribs or of the chest wall muscles there is an abnormal breast footprint. In this case the surgeon has to correct its size or location reaching symmetry with the other chest wall side.

Breast conus is the three-dimensional shape, projection and volume of the tissue on the top and anterior to the footprint of the breast ⁷. It differs from patient to patient and it can change in the same person according to age. There isn't an equal distribution of the mammary gland and of soft tissue in human breast and that's why is very important to analyze the same chest wall side for achieving symmetry. The basis of this anatomical structure is usually equal, or smaller in few cases, than the breast footprint.

Conus is generally correlated to the quantity of the skin envelope, sometimes especially in male patients there could be a redundancy of the skin because a loss of subcutaneous tissue.

An aesthetic breast is a good interaction of this anatomical structures, it never depends by only one.

The last step is to make a good nipple-areola complex. It has to be located on the point of maximal antero-posterior projection of the conus and its symmetry gives naturalness and attractiveness to the breast.

Radiological techniques as Chest X-Ray and MRI are best suited to localize chest wall abnormalities defining both muscular and bones deformities.

Surgeon should consider clinical examination, radiological techniques and patient's expectation in order to plan the best suitable option of reconstructive breast surgery. In terms of aesthetic results reconstructed breast should be of a good shape and size, similar and symmetric to unaffected side and should have a natural firmness, both in male and female patients. All these results should be achieved avoiding an anesthetic donor site and too many scars on the chest wall.

Material and Methods

Since November 2006 in our institute have been treated 6 patients (3 M, 3 F, Mean Age=21,3) with Poland Syndrome affected by only chest wall and/or breast deformities (Table I).

TABLE I - Surgical treatments of affected and unaffected breast and N.A.C. reconstruction in patients with Poland Syndrome.

Pz	Age	G	Affected Side	Difference between the affected conus and the contralateral one	Deformity in the footprint	Surgical technique	Later surgery	Surgery of non-affected side	N.A.C. Surgery
1	19	F	R	3rd Type	Infraclavicular depression	Expander and Silicone Implant+ Lipofilling	Replacement of the Silicone Implant	Mastopexia	Reconstruction with local flap
2	24	M	L	3rd Type	Infraclavicular depression	Custom made prosthesis+ Lipofilling	—	—	Double S Shape
3	21	F	R	1st Type	Inferior border too high	Replacement of submammary fold+ Lipofilling	—	Mastopexia	—
4	25	M	L	2nd Type	—	Silicone implant	—	—	—
5	21	F	R	3rd Type	Abnormality of the medial Border	Silicone Implant+ L.D.M.F.	—	—	—
6	18	M	R	3rd Type	Infraclavicular depression	Custom made prosthesis+ L.D.M.F.	Lipofilling	—	—

Right chest wall side was affected in the majority of cases (66.7 %). Every patient has been evaluated for conus deformities and footprint abnormalities through clinical examination supported by radiological imaging (Rx and MRI) of the chest wall.

Conus defects have been divided into 3 degrees: 1st type for loss of conus tissue smaller than 3/8 of the contralateral conus; 2nd type for loss larger than 3/8 and smaller than 6/8 and 3rd type for loss of conus tissue larger than 6/8 of the contralateral conus. Deformities of ribs were present in only one patient and surgical reconstruction was performed together with a thoracic surgery team.

Surgical treatment of all patients has been selected according to our flow chart.

Results

Among our patients, breast hypoplasia was found in every patient and deformities of the footprint in 5 of them. Nipple-areola complex (NAC) has been reconstructed in 2 patients because remaining breast has been considered too hypotrophic (1 patient) or too low (1 patient). An arrow flap technique has been performed in hypotrophic NAC and a double S-shape in lower NAC. In 4 patients NAC reconstruction has been considered unnecessary because symmetry of affected NAC has been obtained after conus reconstruction.

3 conus have been reconstructed with silicone implants, in 2 cases in association with other techniques, as lipofilling or L.D.M.F. (Figs. A, B)

Custom made prosthesis has been used in male patients every time there was a 3rd type conus defect. Lipofilling has been performed everytime we had to fill infraclavicular depression (3 cases) and to reproduce small volumes (1 case).

Any capsular contraction has been observed according to Becker's classification. In each case a large coverage of the prosthesis has been ensured studying latissimus dorsi thickness (between 1.5 to 2 cm) with MRI.

A latissimus dorsi flap has been performed only in few selected cases. In one case the patient has already been treated with surgery of the abdominal wall that didn't allow the survival of a large free flap (patient 5). Thus a prosthesis implant and latissimus dorsi flap reconstruction have been performed. In the second patient a custom made prosthesis has been chosen because of the male gender. The latissimus flap, once harvested, has been inset carefully along the infraclavicular margin to prevent the recurrence of the infraclavicular hollow. Many authors have advocated the use of endoscopy to assist in breast reconstruction with the latissimus dorsi flap but we think a small incision doesn't leave an unacceptable donor site and it's sufficient to perform a good harvest and placement of this flap.

We experienced only one procedural complication, a fat

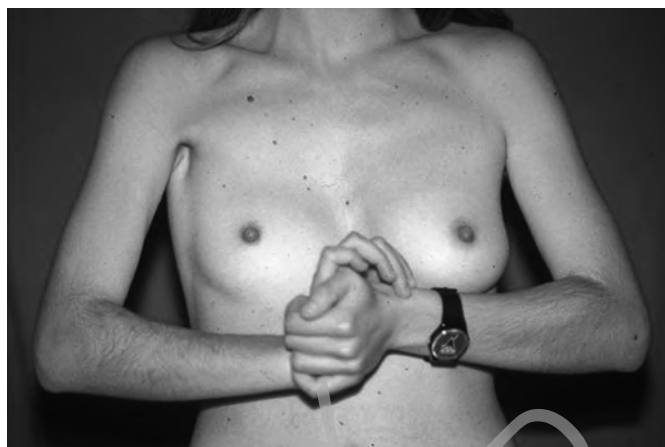


Fig. A: Female patient affected by Poland Syndrome in the right side of the breast.

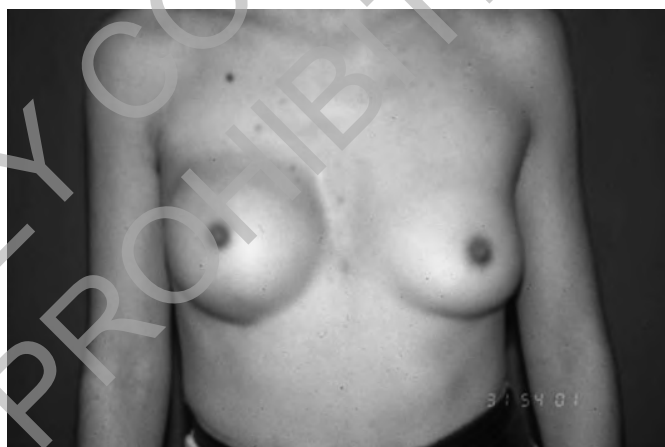

Fig. B: Breast reconstruction by silicone implant in female patient affected by Poland Syndrome.

necrosis with superior migration of the prosthesis (patient 3), successfully managed with replacement of the silicone implant.

The contralateral breast was surgically managed in 2 female patients: mastopexy has been performed in both cases.

Currently, patients are found in different stages of treatment and we are having no complications following our reconstructive surgery.

Discussion

Poland Syndrome patients are usually only affected by aesthetic deformities but don't show any loss of muscle effectiveness. Initially first patients have been treated with silicone implants and latissimus dorsi muscle flap (when unaffected). But nowadays we prefer to restrict the indication for this procedure only to patients not adequate for other reconstructive options. Many authors have expe-

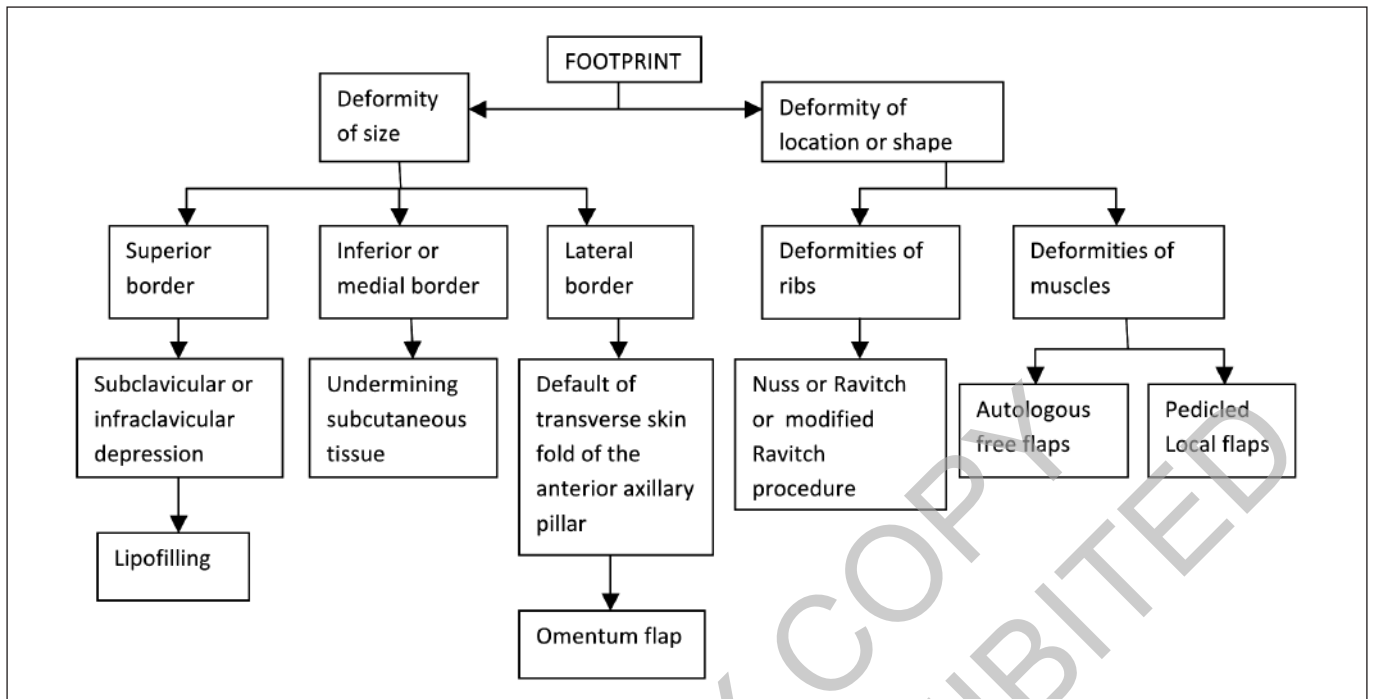


Fig. C: Algorithm for reconstructive surgery of the affected footprint in Poland Syndrome.

rienced a large percentage of sequelae both in the donor site and in the reconstructed one during a 10-years follow-up⁸, such as capsular contracture (qualified according to Baker's classification), loss of shoulder force, limitation in shoulder function and discomfort in more than fifty percent of patients who needed a late reoperation⁹⁻¹⁰. For this reason, if this technique is performed, denervation of the latissimus dorsi is considerate necessary.

We consider unacceptable the loss of latissimus dorsi function in order to correct the aesthetic discomfort. We mainly base our route according to a clinical evaluation and a preoperative radiological study (Rx and MRI of the thoracic wall).

In congenital abnormalities the footprint of the breast can be deformed in shape, size or location. There are many anatomical structures that contribute to change it and usually in Poland Syndrome the footprint is too small and it might be necessary to redefine all its borders. If it's simple to restore the medial or the inferior border (undermining the pocket if the intermammary distance is too large or the submammary fold is too near to the NAC), it's more difficult to restore the lateral and the superior one (Fig. C).

Lipofilling is the best surgical treatment in order to fill infraclavicular depression. This approach requires small donor sites and only one surgical time.

But if fat grafting is a good reconstructive choice to fill infraclavicular depression it isn't enough to reconstruct the transverse skin fold of the anterior axillary pillar.

Omentum flap is a good choice for restoring the anterior axillary pillar¹¹. This flap has been performed 100

years ago for the first time but only in the 1998 has been applied to reconstruct the breast in a patient affected by Poland Syndrome¹².

Omentum flap is malleable, adapts easily to irregular surfaces, provides a better coverage system (a thickness of 1.5 to 2 cm is required), it's able to correct particular details of the breast contour, a result impossible to reach with any other technique.

But this flap can't be used in patients who have been submitted to surgical treatment of the abdomen and it can be very difficult to quantify the right amount of omentum to take in order to achieve symmetry. Because of the reabsorption of the flap it also might be necessary re-treatment after 4 or at least 6 months¹³.

Another important advantage of the omentum flap is its large absorption capacity which reduces hospitalization. In our opinion this flap is the best, and maybe the only one successful, choice for reconstructing this anatomical structure. In severe form of this syndrome we can have also deformities of the ribs, for this reason we consider necessary a preoperative radiological examination in order to plan the right surgical treatment.

There are many different surgical procedures to correct ribs deformities. It could be useful to plan it together with a thoracic surgery team in order to select the best suitable treatment in each case.

In our opinion, every time there are large defects of chest wall muscles the best surgical choice of treatment is to perform an autologous free flap in order to correct them. Instead it could be sufficient to perform a pedicled regional flap in mild chest wall defects.

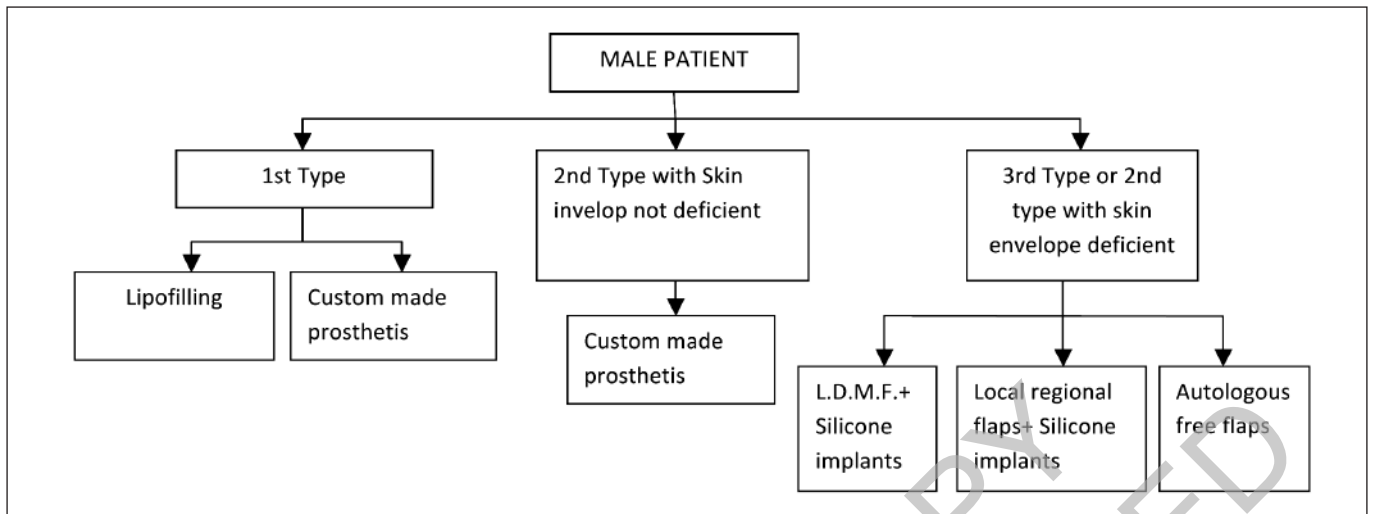


Fig. D: Algorithm for reconstructive surgery of the affected conus in female patients with Poland Syndrome.

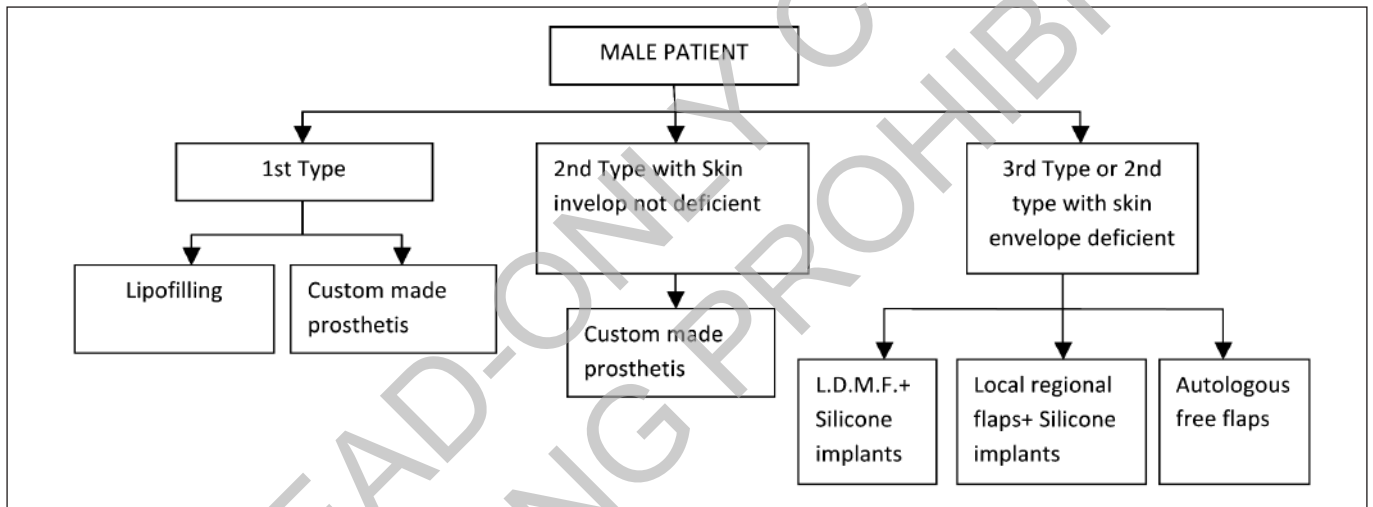


Fig. E: Algorithm for reconstructive surgery of the affected conus in male patients with Poland Syndrome.

In the Poland Syndrome the volume of the glandular tissue (conus) is small but, usually, equally presented over the four quadrants¹⁵. That's why for this correction are used all the aesthetic techniques of augmentation of the breast or, in women with large breasts, respecting patient's wish, we can also decrease non-affected side (Fig. D).

We divided defects of the glandular tissue into 3 types. Our main aim is to achieve symmetry in the less number of surgical steps.

In small defects we can achieve a good result only with lipofilling. This technique is chosen as the first treatment option because the probability of damaging the underlying structures as nerves, ducts and blood vessels is significantly reduced and we only need minimum incisions. We can achieve a good size of the new reformed conus but even with plentiful donor sites the maximum change that can be obtained in one session of fat graft-

ing is only one cup size (not comparable with implant effect)¹⁶⁻¹⁷. In large breasts this technique is not a good choice of treatment because it's a longer procedure and patients need to have adequate donor sites. Especially in women, we should be aware that implanted fat might die and cause lumps or calcifications that could interfere with breast cancer detection. In addition, actually there is no evidence about how reconstructed breasts after lipomodelling behave during pregnancies or weight variations, a question of main importance specially considering the little age of patients affected by Poland syndrome.

Glandular flaps are largely described in literature¹⁸ and can be performed when we need to achieve a good projection of the new breast and we want to reduce the contralateral side also (Fig. E).

In male patients when we can't have access to an adequate donor site for fat grafting we can use a custom

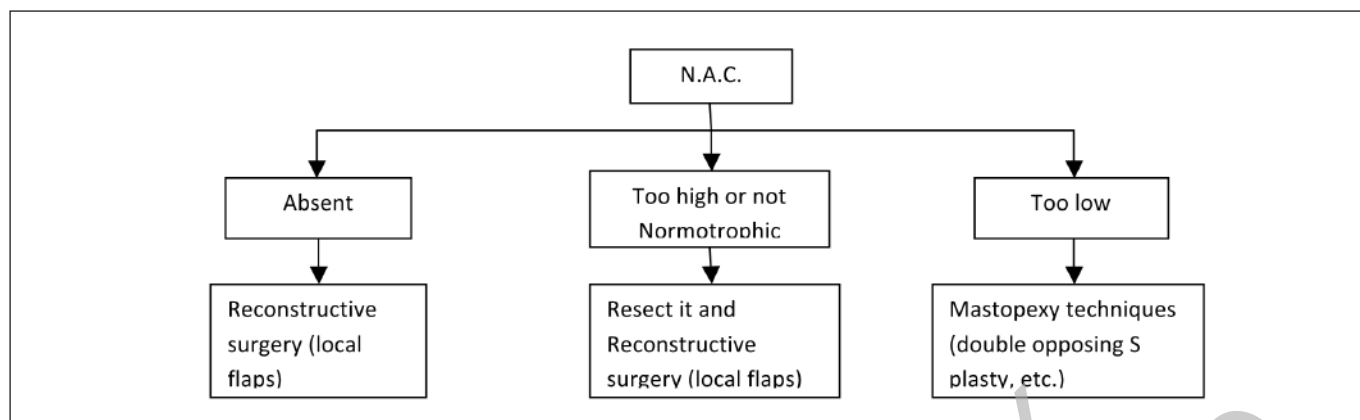


Fig. F: Algorithm for reconstructive surgery of the nipple-Areola complex in Poland Syndrome.

made implant. This kind of silicone implant can fit better than a preformed one and it can be useful especially in patients with defects of the axillary fold.

Complication rates do not significantly differ between customized implant and prefabricated ones¹⁹. We should underline the prominent importance of the relief of the implant, which should exactly match the defect, and the softness of the material that should offers smooth angles and rims. Possible complications could be infection, haematoma and seromas formation, implant extrusion and capsule formation. Especially in Poland syndrome there is an higher rate of implant exposure maybe caused by loss of subcutaneous tissue or hypotrophy of the pectoralis major muscle²⁰. For this reason is useful a preoperative MRI study in order to analyze subcutaneous tissue and thoracic wall muscles. If there is an important loss of infraclavicular tissue it could be accentuated by the presence of a silicon implant and it could be treated by lipofilling or a regional pedicled flap²¹. In our experience there is a smaller rate of complications (we refer to implant exposure) if an expander has been previously placed before the implant, as suggested by literature²².

If we require a good amount of subcutaneous tissue we can perform a pedicled regional flap. The first choice is the latissimus dorsi flap (if the muscle is not affected) but we must be conscious that patients could suffer from a loss of functionality of the arm and is very frequent to re-operate the patient for prosthesis migration or residual deformity.

In case of large defect of glandular and subcutaneous tissue best treatment options consist of complete reconstruction of a new breast using a free flap. We can choose between many alternative free flaps (TRAM, DIEP, SGAP...) but decision must be made considering many indications. First we should be aware that we can't prepare a free flap if there isn't a good vascularization (diabetes, vasculopathies, previous surgery on the donor site,...) or if patient is affected by pathologies of the connective tissue. Moreover hospitalization time and post-operative

recovery are longer and surgeon need appropriate instrumentation and specialistic surgical formation.

Often the nipple areola complex is also abnormal (Fig. F). There are many surgical techniques described in literature to restore a nipple complex areola and we have to choose the right one trying to reproduce size and nipple projection of the non affected NAC. Even when it's too high or it isn't normotrophic is better to resect and reconstruct it.

In few cases we need to bring it down and so we can apply a double opposing S plasty or surgery on the affected and on the contralateral side.

Conclusions

In the majority of cases of Poland syndrome our main objective should be to achieve an aesthetic repair of the affected chest wall and we have to choose between many available surgical techniques. According to our experience lipofilling is the best choice in order to repair mild defects of the conus or of the footprint. If we ensure a large prosthesis coverage and select the right implant type, silicone prosthesis reconstruction is a good and safe technique.

In our opinion omentum flap is the only effective reconstructive choice to restore the anterior axillary pillar.

We believe our algorithms could be useful for an aesthetic surgeon in order to plan a reconstructive approach to a patient with Poland Syndrome, ensuring a good aesthetic result with the less invasive and more reliable solution for each deformity of the affected chest wall he could encounter.

Riassunto

La Sindrome di Poland è una costellazione di rare anomalie congenite della parete toracica, con o senza alte-

razioni dell'estremità superiore omolaterale. Attualmente la classificazione radiologica di Foucras è comunemente usata per scegliere il trattamento chirurgico più appropriato, ma spesso questa classificazione non permette, al giovane chirurgo, di individuare la tecnica chirurgica migliore per raggiungere un buon risultato estetico cercando di preservare la funzionalità muscolare.

Dal novembre 2006 nel nostro istituto sono stati trattati 6 pazienti (3 M, 3 F) con Sindrome di Poland colpiti da deformità della parete toracica e / o della mammella, utilizzando procedure chirurgiche diverse a seconda della deformazione rilevata. Nel corso del follow up è emersa una sola complicanza, una liponecrosi con dislocazione della protesi verso il polo superiore, gestita con successo.

Questo studio è stato progettato per esaminare una serie di opzioni chirurgiche ricostruttive del torace in pazienti affetti da Sindrome di Poland, al fine di sviluppare nuovi grafici di flusso per pianificare la migliore scelta chirurgica in base all'analisi clinica della deformità della parete toracica.

Per raggiungere questo obiettivo abbiamo analizzato la parete toracica come sede della mammella e riportato le alterazioni più comunemente riscontrabili in questa sindrome rifacendoci al punto di vista di Blondeel. Abbiamo dunque esposto le diverse tecniche ricostruttive scelte in seguito ad una valutazione clinica analizzando il "cono" della mammella (indicando la sua proiezione) differenziando le scelte ricostruttive in base al sesso dei pazienti; la sua "impronta", spia di possibili alterazioni della parete toracica sottostanti la quasi sempre distrofica (se presente) ghiandola mammaria che può risultare dislocata; e le diverse possibili alterazioni del complesso areola capezzolo.

Ovviamente l'analisi clinica del paziente non è sostitutiva dell'indagine radiologica che risulta essere fondamentale per la completa valutazione preoperatoria del paziente.

References

- Clarkson JH, Harley OJ, Kirkpatrick JJ: *Alfred Poland's syndrome: A tidy little controversy*. J Plast Reconstr Aesthet Surg, 2006; 59(9):1006-8. Epub 2006 May 26.
- Ram AN, Chung KC: *Poland's syndrome: Current thoughts in the setting of a controversy*. Plast Reconstr Surg, 2009; 123(3):949-53.
- Chichery A, Jalbert F, Foucras L: *Syndrom de Poland. Technique chirurgicales-Chirurgie plastique reconstructrice est esthétique*. Paris: ECM (Elsevier SAS); 2006; 45-667-E.
- Foucras L, Grolleau JL, Chavoïn JP: *Poland's syndrome and hand's malformations: About a clinic series of 37 patients*. Ann Chir Plast Esthet, 2005; 50(2):138-45 French.
- Freire-Maia N, Chautard EA, Opitz JM, Freire-Maia A, Quelce-Salgado A: *The Poland syndrome-clinical and genealogical data, dermatoglyphic analysis, and incidence*. Hum Hered, 1973; 23(2):97-104.
- Blondeel PN, Hijjawi J, Depypere H, Roche N, Van Landuyt K: *Shaping the breast in aesthetic and reconstructive breast surgery: An easy three-step principle*. Plast Reconstr Surg, 2009; 123(2):455-62.
- Tarantino I, Banic A, Fischer T: *Evaluation of late results in breast reconstruction by latissimus dorsi flap and prosthesis implantation*. Plast Reconstr Surg, 2006; 117(5):1387-394.
- Tschopp H: *Evaluation of long-term results in breast reconstruction using the latissimus dorsi flap*. 1991; 26(4):328-40.
- Roy MK, Shrotria S, Holcombe C, Webster DJ, Hughes LE, Mansel RE: *Complications of latissimus dorsi myocutaneous flap breast reconstruction*. Eur J Surg Oncol, 1998; 24(3):162-65.
- Dos Santos Costa S, Blotta RM, Mariano MB, Meurer L, Edelweiss MI: *Aesthetic improvements in Poland's syndrome treatment with omentum flap*. Aesthetic Plast Surg, 2010; 34(5):634-39.
- Costa SS: *Tratamento cirurgico da Síndrome de Poland com omento transposto por videolaparoscopia*. In: Mastologia, Foz do Iguaçu, AdXCBd, Brasil, 1998; p 186.
- Góes JC: *Aesthetic improvements in Poland's syndrome treatment with omentum flap*. Aesthetic Plast Surg, 2010; 34(5):640-41.
- Blondeel PN, Hijjawi J, Depypere H, Roche N, Van Landuyt K: *Shaping the breast in aesthetic and reconstructive breast surgery: An easy three-step principle*. Part IV, Aesthetic breast surgery. Plast Reconstr Surg, 2009; 124(2):372-82.
- Pinsolle V, Chichery A, Grolleau J-L, Chavoïn JP: *Autologous fat injection in Poland's syndrome*. Journal of Plastic. Reconstructive & Aesthetic Surgery, 2008; 61, 784-91.
- Delay E, Sinna R, Chekaroua K, Delaporte T, Garson S, Toussoun G: *Lipomodeling of Poland's Syndrome: A New Treatment of the Thoracic Deformity*. Aesth Plast Surg, 2010; 34:218-25.
- Caldeira AM, Lucas A, Grigalek G: *Mastoplasty: The triple-flap interposition technique*. Aesthetic Plast Surg, 1999; 23(1):51-60.
- Pereira LH, Sabatovich O, Santana KP, et al.: *Surgical correction of Poland's syndrome in males: A purposely designed implant*. J Plast Reconstr Aesthet Surg, 2008; 4:393-99.
- Seyfer AE, Fox JP, Hamilton CG: *Poland syndrome: Evaluation and treatment of the chest wall in 63 patients*. Plast Reconstr Surg, 2010; 126(3):902-11.
- Baratte A, Bodin F, Del Pin D, Wilk A, Bruant C: *Syndrom de Poland chez la femme: Indications thérapeutiques en fonction du stade. À propos de 11 cas et revue de la littérature*. Annales de chirurgie plastique esthétique, 2011; 56, 33-42.
- Fabre G, Gangloff D, Fabie-Boulard A, Grolleau JL, Chavoïn JP: *Breast reconstruction after prolonged tissue expansion. About 247 cases*. Ann Chir Plast Esthet, 2006; 51(1):29-37.