



Spontaneous rupture of a non-functioning pancreatic neuroendocrine tumor

A case report of a rare cause of acute abdomen



Ann Ital Chir, Digital Edition 2020, 9
pii: S2239253X20030650 - Epub, Jan. 10
free reading: www.annitalchir.com

Pietro Achilli, Marco Chiarelli**, Ugo Giustizieri**, Morena Burati**, Fulvio Tagliabue**, Matteo Maternini***, Sabina Terragn***, Angelo Guttadauro***

*University of Milan, Fondazione IRCCS Ca' Granda Ospedale Maggiore Policlinico, Milano (MI), Italy

** Department of General Surgery, Ospedale Manzoni, Lecco, ASST Lecco, Italy

***Department of Surgery, University of Milan-Bicocca, Istituti Clinici Zucchi, Monza, Italy

Spontaneous rupture of non –functioning pancreatic neuroendocrine tumor. A case report and review of the literature

BACKGROUND: Pancreatic neuroendocrine tumors (PNETs) are a group of rare tumors that account for 2% of all pancreatic malignancies, even though their incidence has been increasing over the past 20 years. Most PNETs are sporadic and tend to affect older individuals. Differently from functional tumors, which present with symptoms resulting from the specific hormone being elaborated, non-functioning pancreatic neuroendocrine tumors (NF-PNETs) typically present with symptoms related to local mass effect or metastatic disease. Today, due to the increasing use of abdominal imaging, NF-PNETs are frequently discovered incidentally.

CASE REPORT: A 32-year-old woman was admitted to our emergency department for worsening upper abdominal pain radiating to the back. Shortly after the admission, shock and peritoneal signs developed. An abdominal computerized tomography scan showed a solid mass (9 x 12 cm) of the pancreatic tail with severe hemoperitoneum. Exploratory laparotomy and subsequent distal splenopancreatectomy were performed for a bleeding tumor. Histopathological report showed a neuroendocrine, well differentiated tumor (G1). The postoperative course was uneventful and the patient was successfully discharged on 10th postoperative day.

CONCLUSION: Spontaneous rupture of solid neuroendocrine neoplasms of the pancreas can cause acute abdomen with potentially devastating effects.

KEY WORDS: Abdominal pain, acute abdomen, Hemorrhagic shock, Pancreatic neuroendocrine tumor

Background

Pancreatic neuroendocrine tumors (PNETs) comprise a heterogeneous group of neoplasms that arise from pluripotent cells in the pancreatic ductal/acinar system with variable clinical expression and progression¹. The PNET incidence is approximately 0.43/100,000 per year,

accounting for 7% of all NETs, and has been increased in the last two decades². This growing incidence of PNET can be explained by the increased frequency of abdominal imaging, specifically computed tomography (CT), which leads to a high rate of asymptomatic tumors incidentally diagnosed³. Clinically, PNETs are often classified as functional or nonfunctional based on the presence or absence of a particular clinical syndrome associated with hormone hypersecretion. Differently from functioning neoplasms, non-functioning pancreatic neuroendocrine tumors (NF-PNETs) do not cause paraneoplastic symptoms and usually present with symptoms of mass effects, distant metastases, or both⁴. Consequently, NF-PNETs are often lately diagnosed due to their vague symptoms and rarity⁵. Although surgical resection is considered the mainstay of curative treat-

Pervenuto in Redazione Marzo 2019. Accettato per la pubblicazione Giugno 2019

Correspondence to: Pietro Achilli, University of Milan, Fondazione IRCCS Ca' Granda Ospedale Maggiore Policlinico, Via Sforza 35, 20122 Milano (MI), Italy (e-mail: pietro.achilli89@gmail.com)

LIST OF ABBREVIATIONS

PNET: Pancreatic neuroendocrine tumor;
 NF-PNET: non functioning pancreatic
 neuroendocrine tumors;
 SPN: solid pseudopapillary neoplasm;
 MCN: Mucinous cystic neoplasm

ment for NF-PNETs, for small tumors less than 2 cm with a low proliferative index (Ki-67) observation may be an appropriate option ⁶. The overall 5-year survival rate is approximately 30%, with grading and systemic metastases at presentation as most significant prognostic factors ^{5,6}. Few cases of spontaneous ruptures of pancreatic tumor have been reported in the literature and none of them concerns a NF-PNET ⁷. Herein, we present the first case of spontaneous rupture of NF-PNET leading to acute abdominal pain and hemorrhagic shock.

Case Presentation

A 32-year old woman was admitted to our Emergency Department with severe abdominal pain in the left hypocondrium radiating to the back that had begun two hours earlier. She had a history of iron deficiency anemia successfully treated and reported multiple episodes of diarrhea in the last two months. Physical examination revealed abdominal distention with tenderness in

the left upper quadrant. Vital signs were the followings: pulse rate 100 beats/minute, blood pressure 115/70 mm/Hg and body temperature 36.5 °C. Blood tests showed decreased hemoglobin concentration (9.5 g/ dl) with elevated levels of white blood cells (13,000 per ml), normal level of C-reactive protein, normal platelet count and creatinine level. Liver enzyme, alkaline phosphatase and serum amylase were within the normal limits. One hour after admission the patient's general condition rapidly deteriorated with increasing abdominal pain in the upper quadrants and pre-syncope symptoms. Blood pressure decreased to 90/60 mm/Hg, heart rate increased to 130 beats/minute and arterial blood gas analysis showed a further decrease of hemoglobin level (8.1 g/dl). Urgent abdominal CT scan showed a solid mass (9x12x8 cm) with some cystic components in the pancreatic tail, associated with a massive hemoperitoneum and splenic vein compression. Also ecstasic collateral venous vessels along the course of the gastroepiploic vein and the mesenteric vein were reported (Fig. 1). Considering the rapid development of anemia and the deterioration of clinical conditions, the patient underwent emergency surgery. An exploratory laparotomy was performed, showing the presence of blood clots in the abdominal cavity and active bleeding from a ruptured mass in the pancreatic tail. A distal splenopancreatectomy was necessary, since the spleen was displaced cranially and the hilar region was infiltrated by the tumor (Fig. 2). In the following days only one blood transfusion was needed and the concentration of the amylase in the fluid from the peritoneal drainage rapidly normalized. Total length of hospital stay was ten days. Definitive histopathologi-

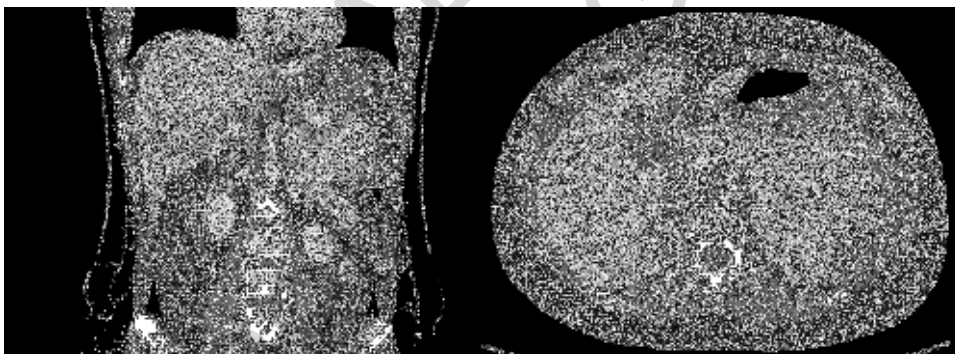


Fig. 1: CT scan showing a solid mass partially contrasted on the pancreatic tail associated with marked fluid collection in the peritoneal cavity.

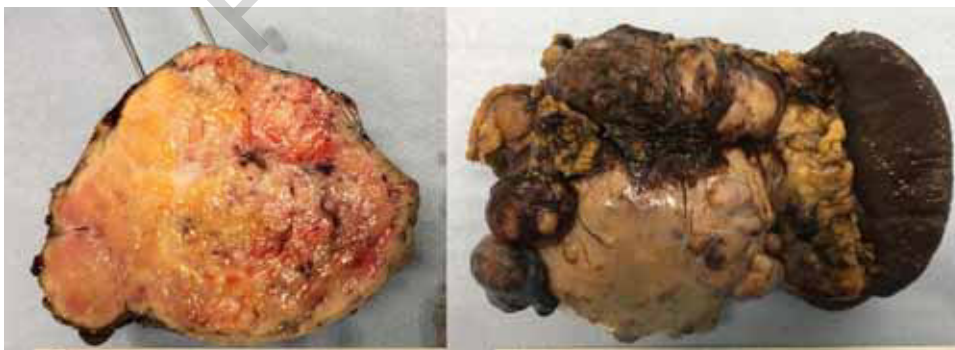

Fig. 2: Fixed macroscopic specimen of pancreatic neuroendocrine tumor.

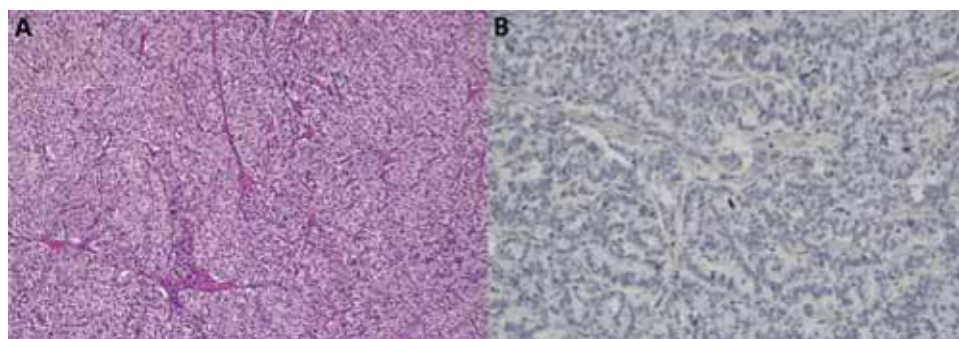


Fig. 3: A) Hematoxylin and eosin stain demonstrated the small to medium-sized cells with scanty cytoplasm and hyperchromatic nucleoli; B) KI-67 immunostain showing <3% nuclear staining.

cal examination revealed a neuroendocrine, well differentiated tumor (G1) with a mitotic count <2 per 10 high power fields (HPF), a Ki67 index lower than 3% and free surgical margins (Fig. 3). During surgical follow-up the patient underwent a scintigraphy with a somatostatin analogue (OctreoScan®) which did not show evident pathological uptake of the tracer in the supra and sub-diaphragmatic sites. Fourteen months postoperatively, there was no evidence of recurrence.

Discussion and Conclusions

NF-PNETs account for more than 75% of all pancreatic neuroendocrine tumors and represent a heterogeneous group of neoplasms with uncertain behavior. Nowadays, due to the widespread use of abdominal imaging, most of NF-PNETs are accidentally discovered, with more than 60% presenting with synchronous liver metastases². Less often patients present with nonspecific symptoms related to tumor invasion or displacement of contiguous structures, including jaundice, abdominal pain, weight loss, abdominal mass, nausea and vomiting. Acute abdomen is not considered as a possible clinical

manifestation of this type of tumor, indeed no case of spontaneous bleeding or rupture is reported in the literature⁶. Spontaneous abdominal hemorrhage is defined as non-traumatic and non-iatrogenic intra-abdominal bleeding and can be caused by the rupture of visceral organs. The sources of bleeding are often hypervascular neoplasms, such as hepatic adenoma or hepatocellular carcinoma, renal cell carcinoma or angiomyolipoma and adrenal pheochromocytoma⁸. Since the spontaneous rupture of a pancreatic neoplasm is an extremely rare event, we researched the English literature for previous reported cases. We considered only cases of spontaneous ruptured of primary pancreatic neoplasm confirmed histologically. Ruptures occurred after traumatic events or cases of pancreatic metastases from other primary malignancies were excluded. A total of 13 cases of spontaneous ruptures of primary pancreatic tumors were identified^{7, 9-20}. Patients and tumor characteristics are summarized in Table I. Tumor location in the pancreas was variable with most tumors found in the body or tail of the pancreas and only two cases found in the head. Mean tumor size was 11 cm, with all but one tumor being smaller than 8 cm in diameter¹⁷. Regarding the tumor type, there was a predominance of two differ-

TABLE I - Reported cases of spontaneous rupture of primary pancreatic neoplasm.

Canali EPase Number	Authors	Year of publication	Gender	Age	Tumour size (cm)	Type of the tumor	Location of the tumor
1	Bombí JA <i>et al.</i>	1984	F	22	12	Solid pseudopapillary neoplasm	body
2	Annali Ep & Achilli <i>al.</i>	1986	F	33	10	MCN with associated invasive carcinoma	tail
3	Todani T <i>et al.</i>	1988	F	16	8	Solid pseudopapillary neoplasm	tail
4	Panieri E <i>et al.</i>	1998	F	34	12	Solid pseudopapillary neoplasm	body
5	Ozden S <i>et al.</i>	2007	F	32	15	MCN with associated invasive carcinoma	tail
6	Bergensfeldt M <i>et al.</i>	2009	F	42	11	MCN with associated invasive carcinoma	body
7	Naganuma S <i>et al.</i>	2011	F	32	11	MCN with associated invasive carcinoma	head
8	Mohammadi A <i>et al.</i>	2012	M	39	12	Acinar cell carcinoma	head
9	Honda S <i>et al.</i>	2013	M	5	12	Pancreatoblastoma	body
10	Takamatsu S <i>et al.</i>	2013	F	13	4	Solid pseudopapillary neoplasm	tail
11	Pattanshetti VM <i>et al.</i>	2014	F	12	13	Solid pseudopapillary neoplasm	body
12	Omori H <i>et al.</i>	2015	F	31	-	Solid pseudopapillary neoplasm	body
13	Narita M <i>et al.</i>	2015	M	69	-	Ductal adenocarcinoma	body
14	Our patient	2019	F	32	12	Neuroendocrine tumor	tail

ent histotypes: solid pseudopapillary neoplasm (SPN) and mucinous cystic neoplasm (MCN) with associated invasive carcinoma. MCNs of the pancreas often grow slowly and can remain indolent for many years²¹. Since the stroma usually expresses estrogen and progesterone receptors²¹⁻²², MCNs that develop during pregnancy tend to be huge with a high risk of rupture and bleeding, as reported in three out of the four cases^{10,13,15}. Thus, the possibility of ruptured pancreatic mucinous cystic neoplasms should be kept in mind, especially facing an acute abdomen in pregnancy. SPNs are low grade malignant tumor accounting for 1-2% of exocrine pancreatic neoplasms and typically present in young females as a large asymptomatic epigastric mass¹². Clinical presentation as acute abdomen is considered rare for this tumor and the incidence of rupture in a large series was reported in 2.7% of 292 cases²³. We found six cases of spontaneous ruptures of SPN reported in the literature, all of them occurred in young women with a mean age of 21 years^{9,11,12,17-19}. The other histotypes reported in our review include ductal adenocarcinoma, acinar cell carcinoma and pancreatoblastoma^{7,16,19}. To our best knowledge, our patient is the first case of spontaneous rupture of PNET reported in the literature. Regarding surgical treatment of the reported cases, distal pancreatectomy with splenectomy was performed in five cases^{10,11,14,19,20}, while spleen preserving pancreatectomy was possible in four patients^{12,13,16,18}. Whipple's procedure (pancreatico-duodenectomy) was necessary in one case¹⁵; in the last three patients tumor enucleations were performed^{7,9,17}. One patient underwent laparoscopic surgery, while the others were submitted to urgent laparotomies¹⁷. Laparoscopic technique has been increasingly applied in recent years in the treatment of body and tail pancreatic lesions, leading to a significantly reduction in morbidity with uncompromised oncological outcomes²⁴. Even though this minimally invasive approach can be considered safe and adequate in elective circumstances, its role as emergency procedure should be further explored^{24,25}.

Thus, in case of ruptured lesions with active bleeding, an open approach with emergent laparotomy is considered the best choice. It is noted that, when performing distal pancreatectomy, especially in young patients, the spleen should be preserved in order to avoid the asplenic complications that may add much morbidity as well as mortality. In our case, since the hilar region of the spleen was infiltrated by the tumor, a splenopancreasectomy was necessary in order to achieve a radical removal and to reduce the risk of local recurrence. In conclusion, we reported the extremely rare case of a spontaneous rupture of a NF-PNET as cause of hemorrhagic shock. Even if considered slow growing neoplasms usually late diagnosed, NF-PNETs can be rare source of spontaneous intraabdominal bleeding requiring emergency surgery.

Riassunto

BACKGROUND: I tumori neuroendocrini del pancreas (PNET) sono un gruppo di tumori rari che rappresentano il 2% di tutte le neoplasie del pancreas, anche se la loro incidenza è aumentata negli ultimi 20 anni. La maggior parte dei PNET sono sporadici e tendono a colpire gli individui più anziani. A differenza dei tumori funzionali, che si presentano con i sintomi derivanti dall'ormone specifico in fase di elaborazione, i tumori neuroendocrini del pancreas non funzionanti (NF-PNET) presentano tipicamente sintomi correlati all'effetto massa locale o a malattia metastatica. Oggi, a causa del crescente uso di imaging addominale, i NF-PNET presentano un'incidenza aumentata.

CASE REPORT: Una donna di 32 anni è giunta al nostro pronto soccorso per l'aggravarsi di un dolore addominale irradiantesi alla schiena. Poco dopo l'ammissione, lo stato della paziente peggiora ulteriormente sviluppando segni di shock e peritonite. Una scansione tomografica computerizzata addominale ha mostrato una massa solida (9 x 12 cm) della coda del pancreas con emoperitoneo. La paziente è stata sottoposta a laparotomia esplorativa e successiva splenopancreasectomia distale per un tumore sanguinante. Il rapporto istopatologico ha mostrato un tumore neuroendocrino ben differenziato (G1). Il decorso postoperatorio è stato regolare, la paziente è stata dimessa in X giornata post-operatoria.

CONCLUSIONE: la rottura spontanea di neoplasie neuroendocrine solide del pancreas può causare addome acuto con effetti potenzialmente devastanti

References

1. Vortmeyer AO, Huang S, Lubensky I, Zhuang Z: *Non-islet origin of pancreatic islet cell tumors*. J Clin Endocrinol Metab, 2004; 89(4):1934-938. PubMed PMID:15070966.
2. Lawrence B, Gustafsson BI, Chan A, Svejdá B, Kidd M, Modlin IM: *The epidemiology of gastroenteropancreatic neuroendocrine tumors*. Endocrinol Metab Clin North Am, 2011; 40(1):1-18, vii. doi: 10.1016/j.ecl.2010.12.005. Review. PubMed PMID: 21349409.
3. Gorelik M, Ahmad M, Grossman D, Grossman M, Cooperman AM: *Nonfunctioning Incidental Pancreatic Neuroendocrine Tumors: Who, When, and How to Treat?* Surg Clin North Am, 2018; 98(1):157-67. doi: 10.1016/j.suc.2017.09.014. Review. PubMed PMID: 29191272.
4. Halldanarson TR, Rabe KG, Rubin J, Petersen GM: *Pancreatic neuroendocrine tumors (PNETs): incidence, prognosis and recent trend toward improved survival*. Ann Oncol 2008; 19: 1727-733. PMID: 18515795 DOI: 10.1093/annonc/mdn351.
5. Franko J, Feng W, Yip L, Genovese E, Moser AJ: *Non-functional neuroendocrine carcinoma of the pancreas: Incidence, tumor biology, and outcomes in 2,158 patients*. J Gastrointest Surg, 2010; 14: 541-548. PMID: 19997980 DOI: 10.1007/s11605-009-1115-0.
6. Kuo JH, Lee JA, Chabot JA: *Nonfunctional pancreatic neuroendocrine tumors*. Surg Clin North Am, 2014; 94(3):689-708. doi:

- 10.1016/j.suc.2014.02.010. Epub 2014 Apr 13. Review. PubMed PMID: 24857584.
7. Mohammadi A, Porghasem J, Esmaili A, Ghasemi-Rad M: *Spontaneous rupture of a pancreatic acinar cell carcinoma presenting as an acute abdomen*. Int J Surg Case Rep, 2012; 3(7):293-95. doi: 10.1016/j.ijscr.2012.03.025. Epub 2012 Mar 30. PubMed PMID: 22543229; PubMed Central PMCID: PMC3356555.
8. Furlan A, Fakhraan S, Federle MP: *Spontaneous abdominal hemorrhage: causes, CT findings, and clinical implications*. AJR Am J Roentgenol, 2009; 193(4):1077-87. doi: 10.2214/AJR.08.2231. Review. PubMed PMID: 19770332.
9. Bombí JA, Milla A, Badal JM, Piulachs J, Estape J, Cardesa A: *Papillary-cystic neoplasm of the pancreas. Report of two cases and review of the literature*. Cancer, 1984; 54(4):780-4. PubMed PMID: 6744212.
10. Smithers BM, Welch C, Goodall P: *Cystadenocarcinoma of the pancreas presenting in pregnancy*. Br J Surg, 1986; 73(7):591. PubMed PMID: 3730799.
11. Todani T, Shimada K, Watanabe Y, Toki A, Fujii T, Urushihara N: *Frantz's tumor: A papillary and cystic tumor of the pancreas in girls*. J Pediatr Surg, 1988; 23(2):116-21. Review. PubMed PMID: 3278085.
12. Panieri E, Krige JE, Bornman PC, Graham SM, Terblanche J, Cruse JP: *Operative management of papillary cystic neoplasms of the pancreas*. J Am Coll Surg, 1998; 186(3):319-24. PubMed PMID: 9510263.
13. Ozden S, Haliloglu B, Ilter E, Akin FT, Kebudi A, Peker O: *An extremely rare cause of acute abdomen in pregnancy: ruptured pancreatic mucinous cystadenocarcinoma*. Pancreas, 2007; 34(4):474-76.
14. Bergenfeldt M, Poulsen IM, Hendel HW, Serizawa RR: *Pancreatic ascites due to rupture of a mucinous cystic neoplasm*. Acta Oncol, 2008; 47(5):978-81. PubMed PMID: 17917820.
15. Naganuma S, Honda K, Noriki S, Kimura S, Murakami M, Koneri K, Katayama K, Yamaguchi A, Itoh H: *Ruptured mucinous cystic neoplasm with an associated invasive carcinoma of pancreatic head in a pregnant woman: Report of a case and review of literature*. Pathol Int., 2011; 61(1):28-33. doi:10.1111/j.1440-1827.2010.02609.x. Epub 2010 Nov 3. Review. PubMed PMID: 21166940.
16. Honda S, Okada T, Miyagi H, Minato M, Suzuki H, Taketomi A: *Spontaneous rupture of an advanced pancreatoblastoma: Aberrant RASSF1A methylation and CTNNB1 mutation as molecular genetic markers*. J Pediatr Surg, 2013 ;48(4):e29-32. doi: 10.1016/j.jpedsurg.2013.02.038. PubMed PMID: 23583162.
17. Takamatsu S, Nagano H, Ohtsukasa S, Kawachi Y, Maruyama H: *A case of spontaneous ruptured solid pseudopapillary tumor of pancreas resected by laparoscopic surgery*. Case Rep Med, 2013; 2013:953240. doi: 10.1155/2013/953240. Epub 2013 Apr 30. PubMed PMID: 23737801; PubMed Central PMCID: PMC3657432.
18. Pattanshetti VM, Vinchurkar K, Pattanshetti SV: *Solid pseudo papillary tumor of pancreas: Presenting as acute abdomen in a female child*. Indian J Med Paediatr Oncol, 2014; 35(2):184-6. doi: 10.4103/0971-5851.139000. PubMed PMID: 25197185; PubMed Central PMCID: PMC4152640.
19. Omori H, Asahi H, Inoue Y, Irinoda T, Saito K: *Solid and cystic tumor of the pancreas with massive hemoperitoneum*. Hepatogastroenterology, 2005; 52(63):936-39. PubMed PMID: 15966236.
20. Narita M, Ikai I: *Spontaneous Rupture of Anaplastic Pancreatic Cancer*. J Gastrointest Surg, 2016 20(3):664-65. doi: 10.1007/s11605-015-3029-3. Epub 2015 Nov 23. PubMed PMID: 26597268.
21. Kosmahl M, Pauser U, Peters K, Sipos B, Lüttges J, Kremer B, Klöppel G: *Cystic neoplasms of the pancreas and tumor-like lesions with cystic features: A review of 418 cases and a classification proposal*. Virchows Arch 20,04;445(2):168-78. Epub 2004 Jun 8. PubMed PMID: 15185076.
22. Chiarelli M, Guttadauro A, Gerosa M, Marando A, Gabrielli F, De Simone M, Cioffi U: *An indeterminate mucin-producing cystic neoplasm containing an undifferentiated carcinoma with osteoclast-like giant cells: A case report of a rare association of pancreatic tumors*. BMC Gastroenterol, 2015;15:161. doi: 10.1186/s12876-015-0391-23. PubMed PMID: 26581412; PubMed Central PMCID:PMC4652416.
24. Mao C, Guvendi M, Domenico DR, Kim K, Thomford NR, Howard JM: *Papillary cystic and solid tumors of the pancreas: a pancreatic embryonic tumor? Studies of three cases and cumulative review of the world's literature*. Surgery, 1995; 118(5):821-28. Review. PubMed PMID: 7482268.
25. Kang CM, Choi SH, Hwang HK, Lee WJ, Chi HS: *Minimally invasive (laparoscopic and robot-assisted) approach for solid pseudopapillary tumor of the distal pancreas: A single-center experience*. J Hepatobiliary Pancreat Sci, 2011; 18(1):87-93. doi: 10.1007/s00534-010-0316-y. PubMed PMID: 20676697.
26. Chiarelli M, Gerosa M, Tagliabue F, Fumagalli L, Guttadauro A, Gabrielli F, Marando A, De Simone M, Cioffi U: *Left-sided pancreatic incidentalomas treated with laparoscopic approach: A report of 20 cases*. World J Surg Oncol, 2016; 14(1):204. doi: 10.1186/s12957-016-0949-7. PubMed PMID: 27487847; PubMed Central PMCID: PMC4973032.