

Contralateral axillary metastases from breast cancer.

Personal experience and review of literature



Ann. Ital. Chir., 2014 85: 260-264
pii: S0003469X14021903

Vittorio Pasta, Paolo Urciuoli, Valerio D'Orazi, Daniela Sottile, Massimo Monti, Adriano Redler

Department of Surgical Sciences, Sapienza University of Rome, Rome, Italy

Contralateral axillary metastases from the breast cancer. Personal experience and review of the literature

The contralateral axillary lymph node metastasis (CAM) from breast cancer are very rare, and pose a number of classification problems and therefore also on the surgery attitude to be adopted and the subsequent surgical oncological approach, making a distinction between synchronous and metachronous cases.

You must always wait for a reasonable period of time to exclude the presence of an occult cancer in the contralateral breast.

You make assumptions about the lymphatic pathways that determine this metastasis underlining that in the literature (rare) cases are reported in which the lymphoscintigraphic sentinel lymph node search has shown an uptake of contralateral axillary lymph nodes.

KEY WORDS: Breast cancer, Contralateral axillary lymph node metastasis, Lymph node metastasis

Introduction

As known, the breast metastasizes through the lymphatic route mainly in 3 locations:

- Axillary (I, II, III level);
- Interpectoral (Rotter);
- Lymph nodes of the internal mammary chain.

The contralateral axillary lymph node metastasis (CAM) are described in breast cancer with a variable incidence depending on the cases series, from 3.6 to 6%^{1,2} even if, according to Morcos B. and Coll.¹ (2011), this percentage is probably overestimated as in some studies the diagnosis was based only on clinical examination, and not in all studies a MRI had been performed.

The most frequent causes of CAM can be:

- presence of an occult cancer of the contra-lateral breast^{2,3};
- spread of contralateral breast cancer^{1,2};
- coexistence of a high type of tumor in other location: (thyroid, lungs, gastrointestinal tract, kidneys, uterus, ovaries, melanoma, lymphoma, etc.)^{1,2}.

Several studies have shown substantial changes in the routes of lymphatic breast drainage after breast surgery and of axillary lymph nodes, especially when the patient is subjected to radiation therapy^{1,2}. Indeed, the interruption of the lymphatic channels (both surgical & actinic) causes the development of a lymphatic circulation through alternative collateral routes.

In this regard, already in 1987, Pasta V. and Coll.⁴ with the intent to assess the presence of lymph node metastases of the internal mammary chain, executed a study on 11 patients, mastectomytized for cancer, in which the role of lymphoscintigraphy in the study of post-operative breast cancer was emphasized, and in particular, it noted also how with the presence of lymph node metastases in the internal mammary chain, the lymph flow suffers a cross-over on those of the contralateral chain.

Pervenuto in Redazione Maggio 2013. Accettato per la pubblicazione Agosto 2013

Correspondence to: Daniela Sottile, MD, Strada Paterno, 00010 Villa Adriana (Roma), Italy (e-mail daniela.sottile@alice.it)

These alternative routes, in the axilla, may develop through the dermal / epidermal lymphatic that enter into the deep lymphatic plexus of the chest wall below the contralateral breast.

The CAM can be both synchronous and metachronous, and if the development of alternative routes in patients undergoing surgery is explainable, the presence of CAM in patients not yet operated in which the percentage seems to be similar to that of patients operated is less immediate.¹

In fact, although it's rare, the lymphatic drainage towards the contralateral axilla was sometimes observed on the occasion of lymphography for the search of the sentinel lymph node.^{5,6}

In most cases it is a high grade invasive ductal carcinoma with presence of LVI and over-expression of HER2.¹ Furthermore, the involvement of 1-3 contralateral lymph nodes has a better prognosis at 5 years compared to patients with 4 or more lymph nodes.²

According to the TNM classification, the CAM detection must be considered as distant metastasis (M1) that means in a IV disease stage.

While, according to Gauthier T. and Coll.³ in 2010 and Agarwal A. and Coll.⁷ in 2005, the CAM could be considered a locoregional home (TN1M), same as the ipsilateral axillary lymph node metastases, in consideration of the direct drainage of the cancer to the contralateral lymph nodes.^{7,8}

For several years the guidelines have not recommended the sentinel lymph node biopsy in patients with breast cancer who already underwent axillary surgery, until 2005, when the American Society of Breast Cancer, revised this recommendation without considering the

previous axillary lymphadenectomy a contraindication for sentinel lymph node biopsy contralateral anymore, still recommending anyway an individualized surgical treatment.⁸

The observation of a patient with metachronous CAM has led us to an in-depth bibliography in order to frame the percentages, the characteristics and the distribution channels and the proper attitude to keep in these situations.

Material and Methods

Our experience refers to the observation of a patient that we have already operated 22 years ago on left excess outer quadrantectomy plus ipsilateral axillary lymphadenectomy for infiltrating ductal carcinoma (T1, N0 ER> 50%, PgR> 50%) at the once called III Surgical Clinic Institute, now the Department of Surgical Sciences, of Rome La Sapienza University, the patient was subjected to radiotherapy plus hormonal therapy (tamoxifen) for 5 years, and later on to periodic clinical instrumental. On the occasion of one of these controls (22 years after surgery) the presence of a recurrence on the scar of the previous quadrantectomy and the presence of some enlarged lymph nodes in volume and consistency in the contralateral armpit has been revealed.

It has been therefore executed:

- Rx mammography which noted the presence of a skin thickening under the scar of non-unique interpretation with suspicion of scar recurrence;
- Breast ultrasound that pointed out at surgical scar level of the previous surgical scar quadrantectomy eco structural alterations within a framework of fibrocica-

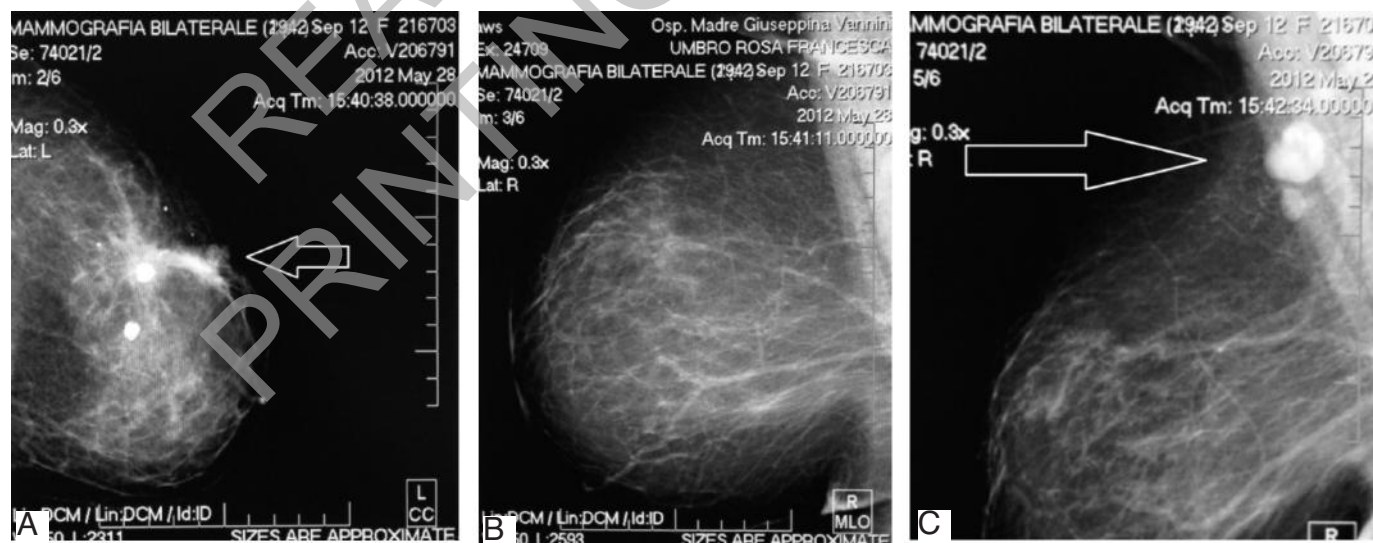


Fig. 1: Rx bilateral mammography:

- A) On the left, results of external previous QUART overcome, in the scar, as well as coarse calcifications outcome of previous steatonecrosis, you can notice a distortion of the scaffold-parenchima with stromal thickening and retraction of the floors above;
- B) On the right under normal mammogram, no suspicious lesions are noted;
- C) In the oblique projection of the right breast the presence of at least 4 ovoid opacity are highlighted.

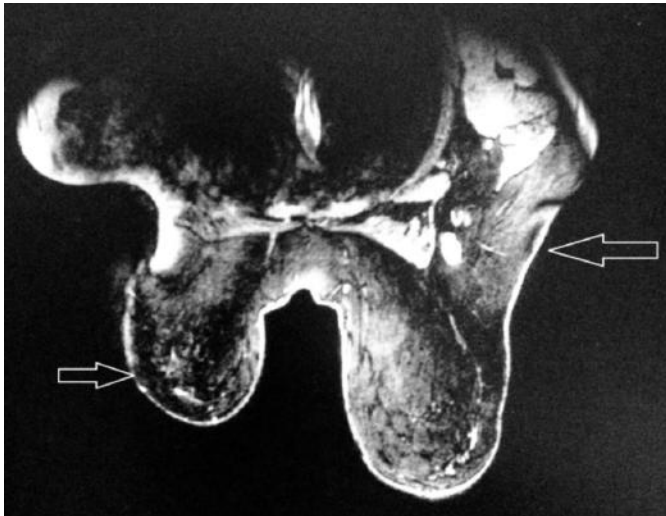

Fig. 2: R.M. bilateral breasts.

Outcomes of QUART, it is noted in the sub-scar area (about 17mm) enhancement after M. of C. There were no other places of enhancement bilaterally. In the right axilla it confirms the presence of enlarged lymph nodes with fatty hilum loss of probable pathological significance.

trizial outcomes and partially calcified. In the axilla contralateral side the presence of some lymph nodes grouped together in conglomerate of more than 2 cm in size is indicated, with a distinct thickening of the cortical and modest attenuation of the breast lymphatic echogenicity system. There were no eco graphically lymph nodes in the armpit on the side of the previous quadrantectomy. For this reason, during the same examination a sample with needle 27 G for cytologic examination was performed on the right axillary lymph nodes;

– Cytology eco guided axillary contralateral lymph nodes highlighted the presence of blood and amorphous material with numerous epithelial elements isolated or grouped in clusters with hyperchromatic and polymorphic nuclei, with little cytoplasm. The picture gives evidence of metastases from breast cancer;

– MRI demonstrated along the surgical scar, an area of enhancement with irregular margins of about 17mm in diameter. At the level of the right armpit in the seat of the sonographic findings described and subjected to cytology sample it confirmed the presence of some enlarged lymph nodes with rounded fatty hilum loss of probable pathological significance.

Therefore, the patient was operated after excision of the scar quadrantectomy whose extemporaneous histological examination confirmed the recurrence below the scar of the cancer of 22 years earlier.

Therefore the patient was operated by performing a radicalization previous quadrantectomy by mastectomy. So then a contralateral axillary lymphadenectomy was performed.

The definitive histological examination confirmed the

presence of relapse with suggestive figures of lymphatic vessels invasion. The histological examination of residual breast detected the presence in the adjacent parenchyma of some ductal carcinoma outbreaks in situ mild (DIN2) with characteristics similar to those of the tumor removed 22 years ago. UICC TNM Classification 2009: PNX RPT2 pM1 (considering the absence of cancer in the contralateral breast) G2.

Later on, the patient was sent to the oncologist for the therapy that followed the chemotherapy regimen (FEC) followed by radiation and finally hormone therapy. After 1 year, the patient has no recurrence either locally or at a distance and the remaining breast is exempt to-bacco use.

Review of the literature

From a review of the last 6 years of literature there are only 36 cases described by 9 authors of CAM, most of the authors (like us) (Herold C. and Coll. in 2011⁹, Cunha AL and Coll. in 2011¹⁰; Gauthier T. and Coll. in 2010³, Kinoshita S. and Coll. in 2010¹¹; Stevens H. and Coll. in 2007¹²; Capobianco G. and Coll. in 2007⁶) reports the observation of a single case.

Morcos B. and Coll. (2011) describe 21 of them¹ Lanitis S. and Coll. (2009) 2 of them². Huston T. and Coll. (2007) describe 7 of them¹³. Of the 36 cases reported in literature, 22 were metachronous CAM (with an interval changing between 12 months and 13 years after the first operation) and 14 synchronous.

In 2007, Capobianco G. and Coll.⁶, reported a single case of a woman of 52 years old, with an occult infiltrating lobular carcinoma of the accessory breast of the anterior chest wall, which was manifested with contralateral axillary lymphadenopathy. The patient was treated with left quadrantectomy and bilateral axillary lymphadenectomy followed by radiotherapy and chemotherapy.

In 2007, Stevens H. and Coll.¹² reported a case of a woman of 63 years old with a history of sternotomy for coronary artery bypass graft, which had an adenocarcinoma with lymphoscintigraphy on the right breast, which identified the sentinel lymph nodes in the armpit contralateral. The patient underwent mastectomy and right axillary lymphadenectomy where 29 metastatic lymph nodes arised, on the basis of lymphoscintigraphy at the same time the removal of 2 lymph nodes of the axilla contralateral was performed which resulted when recovering metastatic disease.

In 2007, Huston T.L. and Coll.¹³, reported 7 cases of women between 35 and 65 years old, all suffering from an infiltrating ductal carcinoma of the left breast. All patients were subjected to an ultrasound, mammography and MRI bilateral breast. The initial treatment consisted of a lumpectomy followed by irradiation breast in 6 cases, and radical mastectomy followed by radiation therapy post-surgery in the remaining case.

Lanitis S. and Coll. in 2009⁹, described 2 cases: 2 patients with contralateral axillary lymphadenopathy developed after treatment of breast cancer. An ultrasound, mammography, MRI Bilateral breast and lymph node biopsy were performed. All patients were subjected to axillary lymphadenectomy.

In 2010, Kinoshita S. and Coll.¹¹, reported a case of a 64 years old woman with invasive ductal carcinoma of the left breast, that 5 years after conservative therapy (lumpectomy, radiation therapy, axillary lymphadenectomy) was showing right axillary lymph node metastases. A year after axillary lymphadenectomy, mammography and breast ultrasound showed the presence of a new lesion in the left breast QSI, that the core biopsy revealed as an injury similar to the contralateral axillary metastases. The patient was then subjected to mastectomy.

Gauthier T. and Coll. in 2010³, reported a case of a 56 year old woman with a previous history of an invasive ductal carcinoma of the right breast in the QSE. The patient underwent quadrantectomy with removal of 3 lymph nodes, followed by radiotherapy and chemotherapy. After 13 years a recurrence in the contralateral right breast with axillary metastases has been pointed out.

In 2011 Morcos B. and Coll.,¹ described 21 patients aged between 29 and 71 years old, with CAM on a total of 276 patients operated for breast cancer. Ultrasound and mammography were performed on all patients, but only in 8 patients an MRI was performed. Of the 21 patients, 19 underwent a radical mastectomy and radiotherapy and 2 patients were not subjected to surgery for the presence of distant metastases.

Always in 2011, Herold C. and Coll.⁹ reported 1 case of a woman operated at the age of 22 years old for left breast carcinoma with conserving surgery plus axillary lymphadenectomy. After 9 years at the age of 31 the patient developed a second cancer, always on the left side with the presence of lymph node metastases on the right in the absence of suspicious lesions in this breast. The patient underwent, for personal choice, on a bilateral mastectomy and right axillary lymphadenectomy that confirmed the presence of CAM in the absence of neoplasia in the right breast, later on the patient was treated with chemotherapy and radiotherapy.

Finally in 2011 Cunha A.L and Coll.¹⁰ reported a very particular case of a patient 55 years old treated with neoadjuvant chemotherapy followed by quadrantectomy and radiotherapy for invasive ductal carcinoma of the right breast that after 6 years has developed an epithelioid angiosarcoma of the same breast with axillary contralateral metastases, after 1 year the patient had a recurrence in the abdominal wall skin with axillary lymph node metastases first with at axillary contralateral level treated with CHT and RT, and then after about 1 year the patient developed lymph node metastases even in the groin.

Discussion

The rare occurrence of axillary contralateral metastatic in patients with breast cancer leads inevitably the clinical to questions and considerations on why and through which way this could have happened.

First you have to perform all clinical and instrumental that allow to exclude the presence of an occult carcinoma, and therefore unrecognized of the contralateral breast, not by chance we waited 12 months after surgery to report our experience as CAM.

Actually you should distinguish between those cases (such as the one by us reported) in which metastasis has occurred at a distance of years after the first operation and particularly if this, in addition to lymphectomy, was followed by a radiation therapy, that by altering the natural lymphatic drainage could have led to a cross-over of alternative ways, first of all the one of the axillary lymph nodes, even if unable to prove it, it is not inconceivable that these metastases may have a particular tropism for the axillary lymph nodes, in fact, one wonders why, in these cases, there were no supraclavicular lymph nodes level first metastasis or at the level of those tributaries of the internal mammary.

It is assumed that the dense network subcutaneous lymphatic is a valid drainage alternative flowing in the contralateral mammary lymph. In fact, although rare the lymphatic drainage on the contralateral armpit was sometimes observed and described also in the occasion of lymphoscintigraphies for the search of sentinel lymph node ^{5,6}.

In particular, in the case we described it is a tumor that remained apoptosis for 22 years, that during this long period of time had to be a convenient alternative lymphatic drainage to the contralateral axilla, probably also because of the effect of radiotherapy also carried out on the internal mammary.

Instead it is more difficult to explain the presence of CAM synchronous with no evidence of bilaterality of neoplasia, not even at a distance (occult ca) in literature there are 14 resulting on a total of 36.

In fact, in our experience it happened in another case with suspected CAM in which, however, only later (at the time MRI did not exist) the presence of a ca occult of the contralateral breast was highlighted, and for this reason it has not been reported in our work.

The synchronous are less frequent and are more rare, in particular we signal 2 of the ones reported in literature in recent years, of which the first described by Capobianco G. in 2007⁶ revealed with right lymph node metastasis following a breast carcinoma arising on the supernumerary of the left chest wall, in this case the anomaly of the seat of the primitive could explain the different lymphatic drainage.

While the second case described by Stevens H. in 2007¹² refers to a patient previously operated on for stereotomy for coronary artery bypass graft, operated of mas-

tectomy of the right breast with 29 right metastatic lymph nodes and two on the left (marked with lymphoscintigraphy) in the absence of lesions on the left breast; this situation, although rare, raises further doubts on the routes followed by metastatic cells to achieve the contralateral lymph node stations.

Conclusions

The literature review shows that in the majority of cases of reported CAM metachronous metastases they were patients who had already undergone contralateral breast surgery followed by radiotherapy, this allows us to hypothesize that being the natural routes of lymphatic drainage closed alternative routes were opened in the axillary lymph nodes through the network side against the skin.

The synchronous cases are less frequent, and two in particular refer, the first in a patient with previous surgery on the internal mammary artery for coronary revascularization, and the second to a situation of anatomic abnormality of the number and position of the breast primary tumor site, in both cases the anatomy of the lymphatic drainage is not attributable to normal.

For this reason we can speculate that the presence of metachronous metastases from breast cancer in the contralateral axillary lymph nodes is due, most of the times, to the alteration of lymphatic drainage pathways induced by surgical and post-operative therapies including radiotherapy, even if it is legitimate the doubt that breast cancer has a certain preferential tropism for the axillary lymph nodes, in fact the only case described in the literature of CAM with nodal metastases also in the groin refers to a patient who had developed after RT a tumor with different characteristics and behavior, namely an epithelioid angiosarcoma¹².

Riassunto

Le metastasi linfonodali ascellari controlaterali (CAM) da cancro della mammella sono molto rare, e pongono una serie di problemi di classificazione e pertanto anche sull'atteggiamento chirurgico da adottare e sul successivo approccio oncologico, facendo una distinzione tra i casi sincroni e quelli metacroni.

Si deve sempre attendere un ragionevole periodo di tempo per escludere la presenza di un cancro occulto nella mammella controlaterale.

Si fanno ipotesi sulle vie linfatiche che determinano questa metastatizzazione sottolineando che in letteratura sono segnalati (rari) casi in cui la ricerca linfoscintigrafica del linfonodo sentinella ha dimostrato una captazione dei linfonodi ascellari controlaterali.

References

1. Morcos B, Jaradat I, El-Ghanem M: *Characteristics of and therapeutic options for contralateral axillary lymph node metastasis in breast cancer*. The Journal of Cancer Surgery, 2007; 37:418-21.
2. Lanitis S, Behranwala KA, Al-Mufti R, Hadjiminis D: *Axillary metastatic disease as presentation of occult or contralateral breast cancer*. The Breast, 2009; 18:225-27.
3. Gauthier T, Monteil J, Bourneton N, Jammet I: *Contralateral axillary involvement in breast cancer recurrence: locoregional disease or metastasis?* Eur J Gynaec Onc N, 2010; 6:694-96.
4. Pasta V, Trinci M, Nudo M, Monti M: *The role of lymphoscintigraphy in the role of postoperative patients operated on for breast cancer*. Annals of Surgery Italian, 1987; LIX: I-VI.
5. Carmon M, Mintz A, Hain D, et al.: *Clinical implications of contralateral axillary sentinel lymph nodes*. Breast, 2006; 15(2):266-68.
6. Capobianco G, Spaliviero B, Dessole S: *Lymph node axillary metastasis from occult contralateral infiltrating lobular carcinoma arising in accessory breast: MRI diagnosis*. The Breast Journal, 2007; vol. 13:305-07.
7. Agarwal A, Heron De, Sumkin J, Falk J: *Contralateral uptake and metastases in sentinel lymph node mapping for recurrent breast cancer*. Journal of Surgical Oncology, 2005; 92:4-8.
8. Wellner R, Dave J, Kim U, Menes TS: *Altered lymphatic drainage after breast conserving surgery and axillary node dissection: local recurrence with contralateral intramammary nodal metastases*. Clinical Breast Cancer, 2007; (7)6:486-88.
9. Herold CI, Gaughan EM, Lamb CC: *Second primary ipsilateral breast cancer with contralateral axillary involvement: a case report and literature review*. Clinical Breast Cancer, 2011; 11(6): 406-08.
10. Cunha AI, Amendoeira I: *High grade breast epithelioid angiosarcoma secondary to radiotherapy metastasizing to the contralateral lymph node: unusual presentation and potential pitfall*. Breast Care, 2011; 6:227-29.
11. Kinoshita S, Hirano A, Kobayashi S: *Metachronous secondary primary occult breast cancer initially presenting with metastases to the contralateral axillary lymph nodes: Report of a case*. Breast Cancer, 2010; 17(1):71-74.
12. Stevens H, Van Der Burgh J, Vierhout RJ: *Visualization of contralateral axillary sentinel node in breast cancer in a patient with a history of sternotomy*. Clinical Nuclear Medicine, 2007; 32(5):396-97.
13. Huston TL, Pressman PI, Moore A: *The presentation of contralateral axillary lymph node metastases from breast carcinoma: A clinical management dilemma*. The Breast Journal, 2007; 13(2):158-64.
14. Van Der Ploeg IMC, Oldenburg HSA, Rutgers EJT: *Lymphatic Drainage Patterns from the treated breast*. Ann Surg Oncol, 2010; 17:1069-75.
15. Shrenk P, Tausch C, Wayand W: *Lymphatic mapping in patients with primary or recurrent breast previous axillary surgery*. The Journal of Cancer Surgery; 2008; 34:851-56.