

A case of "silent" pheochromocytoma presenting as spontaneous retroperitoneal hematoma



Ann. Ital. Chir., LXXI, 6, 2000

N. Gullà, Alberto Patriti, L. Capitanucci, B. Fabbri, Aldo Patriti, B. Tiistaino

Università degli Studi di Perugia
Dipartimento di Scienze Chirurgiche
Direttore: Prof. Benedetto Tristaino

Abstract

Pheochromocytoma of the adrenal gland can be the cause of massive and lethal retroperitoneal haemorrhage presenting as acute abdomen. Here we report a case of retroperitoneal hematoma, with concomitant peritoneal spillage, due to the spontaneous rupture of a silent pheochromocytoma. The main clinical findings of this disease will be described. Therapy and prognosis will be also discussed.

Key-words: Pheochromocytoma.

Introduction

Pheochromocytoma is a rare tumor as it occurs in only 0.005-0.1% of the general population (5). Its clinical manifestations are characterized by signs and symptoms which are mainly attributable to the hyperincretion of catecholamine. A retroperitoneal hematoma is rare and can be a potentially mortal outcome of this disease.

We report a case of pheochromocytoma clinically silent until it ruptured spontaneously causing an extensive retroperitoneal hematoma which spread to the peritoneal cavity, provoking concomitant hemoperitoneum. The rapid development of an hemorrhagic shock required an urgent adrenalectomy.

In case of retroperitoneal hemorrhage caused by pheochromocytoma, the necessary preoperative preparations of restoring plasm volume and controlling hypertensive crises cannot be carried out as an immediate surgical operation is imperative.

Case report

A 55-year-old man was urgently hospitalized complaining of continuous lumbar pain, which had been present for about 18 hours. The patient was pale, sweaty and tachypnoic.

Clinical investigation resulted negative with the exception of a protosystolic heart murmur of 2/6; the abdomen was treatable without tenderness and no pathological masses were perceptible. Rectal exploration for melena proved to be negative. Blood pressure was 170/110 and pulse rate 120/min. Hemoglobin was 121 g/dl and hematocrit value

Riassunto

UN CASO DI ROTTURA SPONTANEA DI FEOCROMOCITOMA SILENTE CON MASSIVA EMORRAGIA RETROPERITONEALE

Descriviamo un caso di rottura spontanea di feocromocitoma clinicamente silente, che ha causato una massiva emorragia retroperitoneale con concomitante emoperitoneo.

L'intervento chirurgico, eseguito in urgenza, ha portato alla remissione della sintomatologia clinica e della ipertensione conseguente alla iperincrezione di catecolamine. Da una revisione della letteratura, appare la rarità di tale evento e l'elevata mortalità ad esso associata.

35.5. ECG revealed sinus rhythm and there were no signs of ischemia.

Thus, the patient was kept under observation. On hemochromocytometric examination, carried out an hour after hospitalization, the patient's hemoglobin value had fallen to 11.2 g/dl and the hematocrit one to 32.3, while his arterial pressure had risen to 190/115 mmHg. At the same time an arterial lower limbs echo-doppler was performed which resulted negative. A subsequent hematocrit check revealed that its value had dropped further to 31.8 while hemoglobin concentration was constant. Arterial pressure continued to increase, reaching a maximum value of 200/110 mmHg (Fig. 1).

Abdominal US examination raised the suspicion that a pool of fluid was present below the diaphragm.

Blood pressure vs Hb/Ht

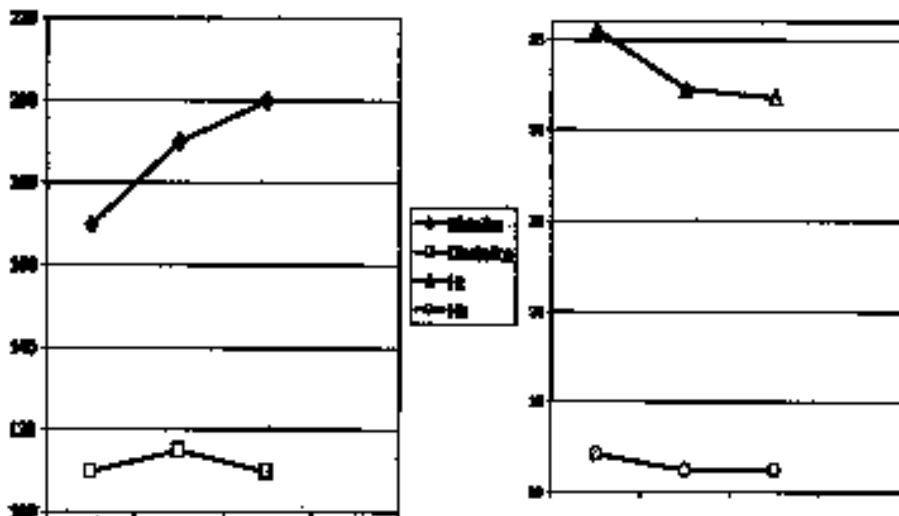


Fig. 1: Trends of blood pressure and Hb and Ht values.

CT examination revealed a massive intraperitoneal and retroperitoneal hematic effusion. The retroperitoneal component was mainly localized in the left perirenal space surrounding the pancreas at the level of the tail, in the front pararenal space and penetrating the thickness of the transverse mesocolon. The intraperitoneal component was mostly collected under both the right and left diaphragm in correspondence with the Morrison and the pelvic pouch. Due to the presence of such a massive hemorrhage, an exploratory laparotomy was then performed.

On opening the peritoneum, about 800 cc of blood were aspirated from the abdominal cavity and, opening the retroperitoneum, another 1500 cc were evacuated. The left adrenal gland was completely saturated with blood and was therefore removed. The surgical specimen was submitted to histological examination which revealed the presence of hyperplastic chromaffin glandular tissue with extensive phlogistic, necrotic and hemorrhagic foci.

The postoperative measurement of 24-hour urine for vanillylmandelic levels was within the norm (2.9 mg/24h after seven days, 3.4 mg/24h after fifteen days).

Two months after surgery, the patient was submitted to CT and scintigraphy with total-body $^{131}\text{MIBG}$ which showed no evidence of significant disease.

Discussion

The atypical situation of a pheochromocytoma with the development of a retroperitoneal hematoma can be caused by two equally unusual events: the spontaneous rupture of the neoplastic mass or a spontaneous hemorrhage within it.

The pathogenic mechanism of the spontaneous rupture of the pheochromocytoma is probably connected to the high

pressure reached within the tumor capsule, caused by rapid growth of the neoplasia or to an intracapsular hemorrhage (4).

The main cause of the hemorrhage is the assumption of alpha-blocking drugs used in the treatment of the paroxysmal hypertension in the pheochromocytoma syndrome and which might also have been responsible for the ischemic necrosis of the tumor (1-6).

The pathogenic mechanisms proposed to explain the action of such drugs are basically two. The drop in blood pressure caused by the administration of the drug is responsible for a decrease in blood flow to the neoplasia which is already inadequate in relation to its fast growth. The alpha-blockers can produce a sudden vaso-dilation within the tumor which transforms the ischemic necrosis zone into an hemorrhage infarction area, thus giving rise to a progressive interstitial hemorrhage throughout the entire gland (1).

However, the clinical picture is dominated, on one hand, by the blood loss in the retroperitoneal space and, on the other, by the release of catecholamine, secondary to the necrosis of the tumoral mass.

The clinical findings of blood loss are the fall in haematocrit and hemoglobin values.

These data are accompanied by extreme variability in the hemodynamic state of the patient which can result in full hypovolemic shock or, on the contrary, in a sudden and serious rise in pressure. These are the two apparently contradictory aspects that should lead the physician towards the diagnosis of a hemorrhage originating from a pheochromocytoma. Some other accompanying not specific findings such as abdominal or lumbar pain, abdominal tension, vomiting, palpation of an abdominal mass can also be present (2).

The detection of the cause of the hematoma is quite easy

when a pheochromocytoma has already been diagnosed; however, when acute abdomen is the origin of the clinical picture, it is difficult to make a differential diagnosis with other pathologic conditions like the rupture of an abdominal aneurysm, pancreatitis, urinary lithiasis, cholelithiasis, mesenteric infarction (3).

Also therapeutic approaches need to be different. In cases in which the pheochromocytoma has already been evidenced and it is hemodynamically stable, surgery can be deferred allowing the patient to be hydrated and to undergo anti-hypertensive therapy with phenossiben-zamin.

In cases in which hemorrhage from a pheochromocytoma is only suspected, an urgent CT is necessary to identify the origin of the hemorrhagic retroperitoneum. Then, the hemodynamic condition of the patient can be evaluated and preoperative treatment can start in preparation for elective surgery.

In both cases, however, the presence of a concomitant hemoperitoneum, secondary to the formation of a solution of continuity of the posterior parietal peritoneum, must be determined by means of CT.

Indeed, in such an event the blood pressure decreases in the retroperitoneal space which, in most cases, is able to spontaneously arrest the hemorrhage from the retroperitoneal vessels.

The inevitable consequence of such an event is the rapid development of anemia and a phase of shock in the patient.

Only in this case is emergency surgery necessary, also considering of the high rate of post and intraoperative mortality such patients risk.

In the Tanaka study 15 cases of spontaneous retroperitoneal hemorrhage due to the rupture of a pheochromocytoma are reported. Twelve of them were operated on in emergency with a right preoperative diagnosis in only two cases and with a consequent mortality rate of 33% (4).

In other series the mortality of these patients exceeds 50% as compared to that of the diagnosed patients (7).

These reports suggest that emergency resection is associated with an high mortality rate and that the most important factor which lead to lead a successful outcome is the correct diagnosis and the appropriate preoperative volume replacement and medical therapy.

Therefore, the operation must consist of total removal of the neoplastic mass, accurate revision of the hemostasis and placing of a retroperitoneal drain.

Later, it is advisable to submit the patient to a follow-up, which includes determination of urinary catecholamine, CT and ¹³¹MIBG scintigraphy in order to diagnose possible sites of metastasis.

Acknowledgements

The Authors thank Miss Beatrice Sensi for her technical assistance.

References

- 1) Terachi T., Teari A., Yoshida S., Yokota K., Fukunaga M.: *Spontaneous rupture of adrenal pheochromocytoma: a case report*. Urol Int, 44:235-237, 1989.
- 2) Lee P.H., Blute R., Malhotra R.: *A clinically "silent" pheochromocytoma with spontaneous hemorrhage*. J Urol, 138:1429-1432, 1987.
- 3) Jones D.J., Durning P.: *Pheochromocytoma presenting as an acute abdomen: report of two cases*. Brit Med J, 291:1267-1268, 1985.
- 4) Tanaka K., Noguchi S., Shuin T., Kinoshita Y., Kubota Y., Hosaka M.: *Spontaneous rupture of adrenal pheochromocytoma: a case report*. J Urol, 151:120-121, 1994.
- 5) Cryer P.E.: *Pheochromocytoma*. Clin Endocrinol Metab, 14:203, 1985.
- 6) Van Way C.W., Feraci R.P., Cleveland H.C.: *Hemorrhagic necrosis of pheochromocytoma associated with phentolamine administration*. Ann Surg, 184:26-30, 1975.
- 7) Simpson E.T., Marszalek W.W., Ramsaroop R.: *Nonfunctioning pheochromocytoma*. Urology, 25:632, 1985.

Autore corrispondente:

Dott. Alberto PATRITI
Dipartimento di Scienze Chirurgiche
Sez. di Chirurgia d'Urgenza
Policlinico Monteluce
Via Brunamonti
06100 PERUGIA
Tel. 075.5783432
e-mail: celso@edisons.it

