

Is sternotomy always necessary for the treatment of mediastinal ectopic thyroid goiter?



Ann. Ital. Chir., 2014 85: 304-307
pii: S0003469X1402185X

Fabrizio Scognamillo, Federico Attene, Panagiotis Paliogiannis, Matteo Walter Ruggiu, Antonio Cossu, Mario Trignano.

Department of Surgical, Microsurgical and Medical Sciences, University of Sassari, Italy

Is sternotomy always necessary for the treatment of mediastinal ectopic thyroid goiter?

Ectopic thyroid goiter accounts approximately for 1% of all substernal goiters and for 10-15% of all mediastinal masses. Sternotomy is generally accepted as the most adequate approach for the removal of ectopic thyroid goiters of the anterior mediastinum. We report two cases of mediastinal ectopic goiter removal through a cervical incision, without sternotomy. The technique is based on a careful and gentle traction of the mass by means of traction stitches and simultaneously on a blunt digital dissection, in order to exteriorize the lesion in the neck, as much as necessary to ligate its vascular pedicle before completing the removal. When performed with caution and precision, this approach can avoid sternotomy in selected patients with ectopic thyroid goiter.

KEY WORDS: Ectopic thyroid, Sternotomy, Thyroidectomy

Introduction

Ectopic thyroid goiter accounts approximately for 1% of all substernal goiters and for 10-15% of all mediastinal masses^{1,2}. It is of disembryogenic origin, depending on an impaired migration of the primitive thyroid tissue between the third and seventh week of gestation. Generally it becomes clinically manifested after a total thyroidectomy as the residual tissue becomes the main target of pituitary TSH³.

Surgery is the treatment cornerstone for substernal goiters. A cervical approach is generally enough for the removal of these lesions⁴. Combined approaches, like cervico-sternotomy, are generally indicated for giant, retro-vascular and malignant lesions^{5,6}. Sternotomy is unanimously accepted as the most adequate approach for the removal of ectopic thyroid goiters^{7,8}.

We report two cases of ectopic prevascular goiter treated without sternotomy and the technical details of the surgical procedures.

Cases report

The patients were females, 56 and 55 years old respectively, both without relevant comorbidities. Clinically, the first patient presented dyspnoea and dysphagia, while the second one mild dyspnoea. Both patients were in euthyroid state. Ultrasonography and computed tomography (CT) scan of the neck and the mediastinum revealed a

Pervenuto in Redazione Febbraio 2013. Accettato per la pubblicazione Giugno 2013

Correspondence to: Dr. Panagiotis Paliogiannis, Department of Surgical, Microsurgical and Medical Sciences, Surgical Pathology, University of Sassari, Viale San Pietro 43B, 07100, Italy (e-mail: ppaliogiannis@uniss.it)

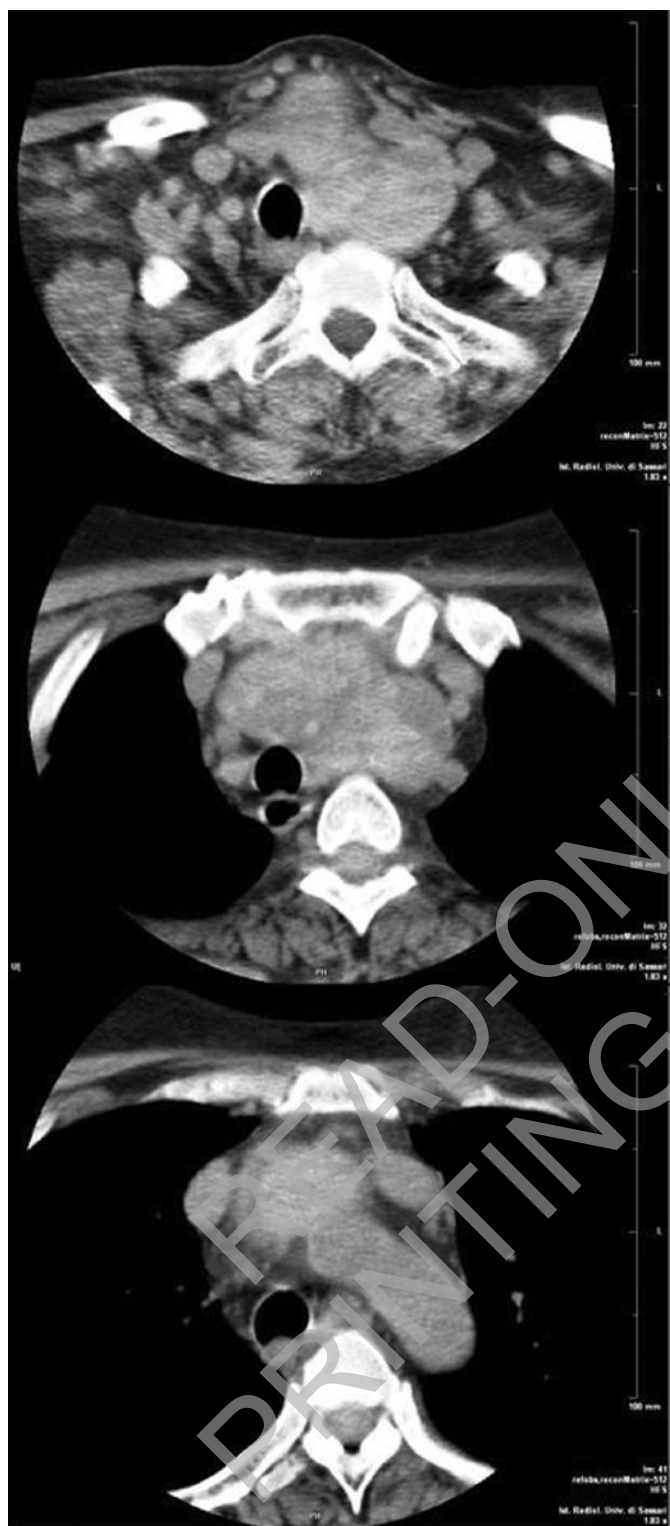

Fig. 1: CT scan sections of the neck and mediastinum of the second patient.

voluminous goiter, reaching the aortic arch in both cases and displacing the trachea on the right, as well as the epiaortic vessels (Fig. 1). The first patient presented some calcifications in the cervical part of the lesion.

Both patients were referred to surgery for a cervico-medi-

astinal goiter, but once the pre-thyroid muscles were opened and the thyroid gland inspected, it was found that the cervical and mediastinal part of the masses were separated and just tightly in contact each other in the area of the inferior pole of the left lobe. We initially performed in both cases a classical thyroidectomy, previous identification and salvation of the recurrent laryngeal nerves and parathyroid glands.

Once the cervical thyroidectomy was completed, a careful digital examination of the intrathoracic lesion was performed. In the second patient a big cyst, full of colloidal material, was identified in the superior aspect of the lesion; the cyst was emptied through an evacuative puncture, reducing the volume of the lesion and offering more space for a better digital palpation. A traction stitch was placed in both cases and a gentle pulling action was started, aided simultaneously by a digital mobilization of the mass. The finger progressed slowly in all directions, in order to free the mass from possible adhesions and verify whether its removal was practicable that way. In both cases the tip of the surgeon's finger gradually reaching these manoeuvres, repeated controls were performed to rule out any bleeding. While pulling the lesion with the traction stitches and pushing it with the finger, it was possible to feel its progressive mobilization and exteriorization. In both cases, a long vascular pedicle was identified and ligated manually, before completing the removal of the lesions.

At the end of the procedures two drain tubes were placed. The postoperative course was uneventful and the drains were removed 24 hours later. Neither laryngeal nerve damage, nor hypocalcaemia or other complications occurred and the patients were discharged on postoperative day two.

Discussion

Total or partial sternotomy is generally accepted as the most adequate approach for the removal of ectopic thyroid goiters in the anterior mediastinal compartment^{7,8}. More invasive procedures are necessary for lesions placed deep in the mediastinum, especially when involve mediastinal anatomical structures, compressing or infiltrating them. The main advantage of sternotomy is the possibility to properly dominate mediastinal masses, especially their vascular pedicles, through a wide operative field. Ectopic goiters have a proper vascularization and this must always be kept in mind, as mediastinal bleeding may be difficult to treat.

In both cases described in this paper the patients were referred to surgery for a secondary substernal goiter, because preoperative imaging was not able to distinguish the ectopic mass which was closely adherent to the left lower lobe of the gland. We have a certain experience in the removal of voluminous secondary substernal goiters using only a cervical access, as we work in an area

of endemic thyroid goiter, and we always try this approach before consider sternotomy^{4,9}. This is what we did for the ectopic goiters described in here. Our decision was based on the absence of infiltration of mediastinal anatomical structures, evidenced by pre-operative imaging, and on the fact that gentle traction and finger blunt dissection produced a progressive exteriorisation of the mass. Finally, once the lesion was partially exteriorized, the identification of a long vascular pedicle, which was immediately and easily ligated, gave as the possibility to proceed and conclude the operation successfully.

In our opinion the key points for a safe removal of ectopic thyroid goiters localized in the anterior compartment of the mediastinum without sternotomy are: 1) careful selection of the patients on the basis of clinical and radiological data, 2) experience in thyroid goiter surgery, 3) blunt, precise and gentle manoeuvres during traction and dissection of the lesion, 4) convert to sternotomy if difficulty in mobilizing the lesion arises or when bleeding occurs.

Riassunto

Il gozzo tiroideo ectopico rappresenta circa il 1% dei gozzi tiroidei immersi e il 10-15% di tutte le masse mediastiniche. La sternotomia è diffusamente accettata come l'approccio più adeguato per l'asportazione chirurgica dei gozzi ectopici nel mediastino anteriore. In questo articolo descriviamo l'asportazione di due gozzi ectopici mediastinici per via cervicotomica e senza sternotomia. La tecnica è basata su una doppia azione chirurgica sulla lesione: gentile trazione mediante punti trasfissi da una parte e digitoclasia previa dissezione per via smussa dall'altra, allo scopo di mobilizzare la lesione nel collo tanto da poter effettuare la legatura del suo pedun-

colo vascolare in sicurezza. Tale approccio, quando effettuato con cautela e precisione, permette il risparmio di sternotomie in pazienti selezionati con gozzo tiroideo ectopico nel mediastino.

References

1. Reeve TS, Rubenstein C, Rundle FF: *Intrathoracic goitre: Its prevalence in Sydney metropolitan mass x-ray surveys*. Med J Aust, 1957; 2:149-51.
2. Cougard P, Matet P, Goudet P, Bambili R, Viard H, Vaillant G, Vergès B, Brun JM: *Les goitres plongeants: 218 cas opérés*. Ann Endocrinol, 1992; 53:230-35.
3. Delbridge L: *Total thyroidectomy: The evolution of surgical technique*. ANZ J Surg 2003; 73:761-68.
4. Paliogiannis P, Scognamillo F, Denti S, Trignano E, Attene F, Trignano M: *Surgical treatment of a patient with retrosternal thyroid goiter*. Ann Ital Chir, 2009; 80:429-33.
5. Huins CT, Georgalas C, Mehrzad H, Tolley NS: *A new classification system for retrosternal goitre based on a systematic review of its complications and management*. Inter J Surg, 2008; 6:71-76.
6. Picardi N, Di Rienzo M, Annunziata A, Bartolacci M, Relmi F: *L'accesso transclavicolare per la liberazione di gozzo immerso per-magno. Una proposta chirurgica alternativa*. Ann Ital Chir, 1999; 70:741-48.
7. Rugiu MG, Piemonte M: *Surgical approach to retrosternal goitre: Do we still need sternotomy?* 2009; 29:331-38.
8. De Perrot M, Fadel E, Mercier O, Farhamand P, Fabre D, Mussot S, Darteville P: *Surgical management of mediastinal goiters: When is a sternotomy required?* Thorac Cardiovasc Surg, 2007; 55:39-43.
9. Cossu A, Budroni M, Paliogiannis P, Palmieri G, Scognamillo F, Cesaraccio R, Attene F, Trignano M, Tanda F: *Epidemiology of thyroid cancer in an area of epidemic thyroid goiter*. J Cancer Epidemiology, 2013; 584768.

Commento e Commentary

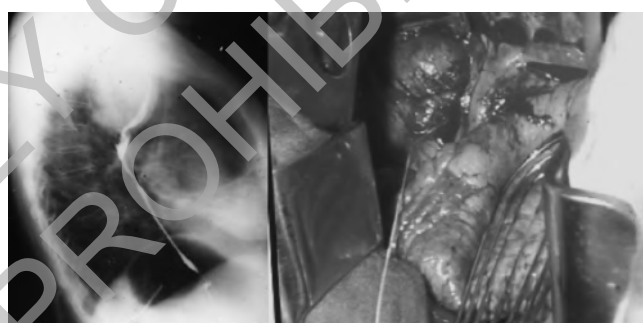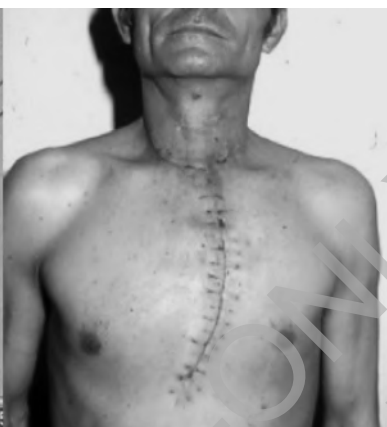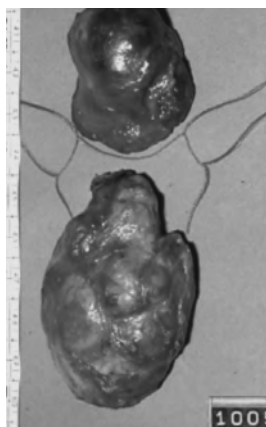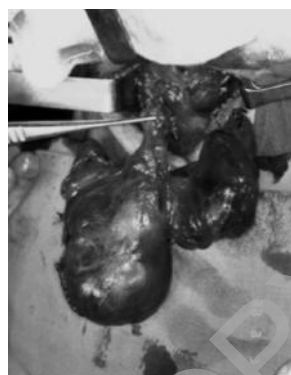
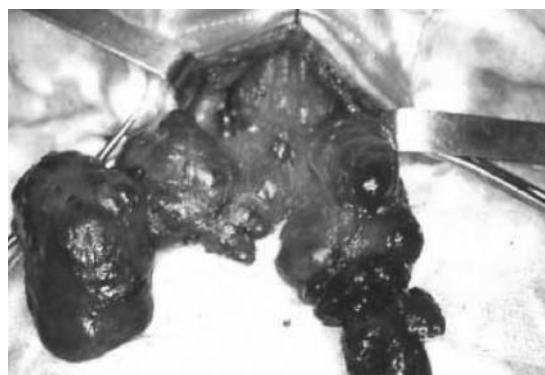Prof. NICOLA PICARDI
Ordinario f.r. di Chirurgia Generale

The issue of intrathoracic goiter's access, for those of cervical derivation, actually recognizes a shared orientation about the possibility, almost without exception, to proceed at their removal through an only cervical approach, even for very bulky masses. In very rare case it is also possible consider the exceptional trans-clavicular approach, but only if the upper thoracic outlet is unaffordable.

The distinction, however, is the main anatomical and surgical data of the location of the intrathoracic goiter if in the anterior mediastinum or in the posterior.

As shown by the Authors, even for ectopic goiters, provided localized in the anterior mediastinum – and those are the most current observations – the only cervical access appears adequate in most cases, provided a careful and delicate execution of the surgical times well described in their study. A limit can be represented by the volume of endo-thoracic goiter itself, that may oblige to a sternotomy

Another thing is whether the localization of an endothoracic goiter is in the posterior mediastinum, and here plays a role the migration path followed, ie if there is a crossing retrovascular or retro-oesophageal, which should be carefully studied preoperatively. In these cases, after the preliminary cervical hemostasis an adjunctive thoracotomic approach may be necessary not for risking vascular damages that can become catastrophic in the absence of an adequate domain of the operative field.



La questione dell'accesso ai gozzi endotoracici ad origine cervicale riconosce attualmente un orientamento condiviso circa la possibilità, quasi senza eccezioni, dell'asportazione attraverso la sola via cervicale, anche per masse molto voluminose. In casi estremi è anche possibile adottare un approccio trans-clavicolare se lo stretto toracico superior si dimostra di calibro insuperabile. La distinzione anatomo-chirurgica principale è però data dalla collocazione del gozzo intratoracico nel mediastino anteriore o in quello posteriore. Come dimostrano gli Autori, anche per i gozzi ectopici, purchè localizzati nel mediastino anteriore – e sono la maggioranza – l'accesso cervicale appare nella generalità dei casi adeguato, pur con attenta e delicata esecuzione dei tempi chirurgici descritta nel loro studio. Un limite può però essere rappresentato dal volume del gozzo endotoracico

Altra cosa è invece se la localizzazione del gozzo endotoracico è nel mediastino posteriore, e qui gioca un ruolo la via di migrazione seguita, cioè se a migrazione crociata retrovascolare o retro-esofagea, che va attentamente studiata in fase preoperatoria. In questi casi, perfezionata l'emostasi preventiva a livello cervicale, può essere necessario un approccio accessorio mediante una toracotomia per non rischiare danni vascolari che possono diventare catastrofici in assenza di un adeguato dominio del campo operatorio.

References

1. Negre E., Mary IL, Marcade P: *Goitres plon-géants rétro-vasculaires croisés. (Goitres mé-diastinaux en écharpe)*. J. Chir, Paris, 1972; 103: 143.
2. Merlier M, Eschapaspe H: *Les goitres à déve-loppement thoracique*. Paris: Ed. P. Baillière, 1973.
3. Picardi N, Pasta V, Monti M: *Contributo allo studio dell'accesso chirurgico dei gozzi endotoracici*. Ann Ital Chir, 48(5-6): 403-18.
4. Picardi N, Stella S, Franceschini R: *Endothoracic goitre with crossed retro-tracheo-oesophageal migration*. Min Chir, 1977; 32(4):197-202.
5. Picardi N, Di Renzo M, Annunziata A, Relmi F: *L'accesso transclavicolare per la liberazione di gozzo immerso permangono una risposta alternativa*. Ann. Ital Chir, 1999; 70(5):741-48.
5. Valdoni P, Tonelli L: *I gozzi endotoracici*. Relaz. 59° Congr Soc It Chir Arch ed Atti Soc It Chir, vol. I, Roma: EMES, 1957.
6. Witz JP, Gillet M, Miech G, Wein AG: *Les goitres plongeants, les goitres thoraciques. Re-flexion à propos d'une serie intégrale de 61 observations*. J Chir, (Paris) 1967; 93:429.