



Diagnosis of micropapillary carcinoma of the breast by endometrial biopsy in a postmenopausal patient with abnormal uterine bleeding



Ann Ital Chir, 2021; 10 - Genn. 20
pii: S2239253X21035106
Online Epub

Eser Colak*, Ozgur Hilal Erinanc**, Duygu Ozdemir*

Baskent University School of Medicine, Konya Medical and Research Center, Turkey

*Department of Gynecology and Obstetrics

**Department of Pathology

Diagnosis of micropapillary carcinoma of the breast by endometrial biopsy in a postmenopausal patient with abnormal uterine bleeding

Metastasis of breast cancer to the uterus is quite rare. The majority of reported cases have evolved from previously known invasive ductal and lobular carcinomas of the breast. Herein, a rare case of invasive micropapillary carcinoma of the breast that was diagnosed via endometrial biopsy, without a previous diagnosis or history of breast cancer, was presented. A 58-year-old postmenopausal patient, who had no history of cancer, presented with complaints of abnormal uterine bleeding (AUB) that had begun 2 weeks prior. After undergoing transvaginal ultrasonography, endometrial biopsy, tomography, and positron emission tomography/computed tomography, the patient was preliminarily diagnosed with invasive carcinoma of the breast. The biopsy confirmed the diagnosis of metastatic invasive micropapillary carcinoma of the breast. In postmenopausal AUB, endometrial metastasis of breast cancer should be kept in mind, especially in underdeveloped and developing countries where regular breast cancer screening has not been achieved.

KEY WORDS: Breast cancer, Endometrium, Metastasis, Micropapillary carcinoma

Introduction

Breast cancer is the most common cancer in women and it has a high mortality rate. It most commonly spreads to the liver, lungs, and bones, while metastasis to genital organs is quite rare^{1,2}. The uterus accounts for only 4% of all metastases to genital organs³. Invasive micropapillary carcinoma is a rare form of invasive breast cancer that accounts for approximately 0.9%-2% of invasive breast cancers⁴. Micropapillary carcinoma is a well-known type of adenocarcinoma that has been described

in various anatomical regions, including the breasts, bladder, lungs, and ovaries. This increasingly common morphological variant has been associated with an increased risk of lymph node metastasis, especially when it originates from primary breast or bladder cancers⁵. The literature comprises reports of patients who had been previously diagnosed with breast cancer, in whom the cancer spread to the uterus during treatment. Herein, a case of invasive micropapillary carcinoma of the breast, which was diagnosed via endometrial biopsy following abnormal uterine bleeding (AUB), with no previous diagnosis or history of breast cancer, was presented.

Case Presentation

A 58-year-old postmenopausal woman, who had no medical or family history of cancer, presented to the gynecological clinic complaining of AUB that had begun 2 weeks prior. The medical history indicated that the

Pervenuto in Redazione Novembre 2020. Accettato per composizione Dicembre 2020

Correspondence to: Eser Col, Department of Gynecology and Obstetrics, Baskent University School of Medicine, Medical and Research Center, Selcuklu, Konya Turkey (e-mail: dresercolak@hotmail.com)

patient had only had 1 Pap smear (at an external center) and had never had a breast cancer screening exam. Transvaginal ultrasonography revealed the endometrium to be 24 mm thick, to have a heterogeneous echogenicity, and a calcified intramural leiomyoma (55 mm). The patient subsequently underwent endometrial biopsy by probe curettage.

Hematoxylin and eosin staining of the endometrial specimen revealed metastatic carcinoma with micropapillary morphology. Microscopic examination showed isolated or papillary clusters of neoplastic epithelial cells that had infiltrated the endometrial stroma. Tumor cells had a moderately eosinophilic cytoplasm, prominent cytoplasmic membrane, and intermediate-to-high-grade nuclei, and formed small cohesive clusters floating in lacunar spaces. Occasional normal endometrial glands were identified (Fig. 1A). The pathology findings revealed micropapillary carcinoma, which is not typical of primary uterine tumors. The immunohistochemistry showed strong positive staining for CK7, GATA-3, and GCDF-15 (Figures 1B and 1C) and negative staining for CK20, WT1, PAX-8, P53, P16, Vimentin, CEA, CDX2, HBM45, CK19, P63, and P40. In view of the morphologic and immunohistochemical profile, the tumor was defined as being metastatic from invasive micropapillary carcinoma of the breast.

Mammography revealed a 28- to 15-mm mass with irregular and spiculated contour that had created stromal distortion in the right breast (Fig. 2). The positron emission tomography/computed tomography (PET/CT) exam confirmed the presence of a spiculated mass in the right breast. There was also right axillary lymphadenopathy or

increased fluorodeoxyglucose uptake in the left occipital lobe, cerebellar vermis, liver and lymph nodes (Fig. 3). The cranial magnetic resonance imaging findings were consistent with metastatic lesions. In light of these findings, the patient was preliminarily diagnosed with invasive carcinoma of the breast and referred for a breast biopsy.

The fine needle aspiration biopsy specimen showed an invasive carcinoma with a significant micropapillary component. The tumor cells from the breast were negative for P63, smoldering multiple myeloma, and cerB2, and positive for estrogen receptors (ER) and progesterone receptors (Fig. 1D).

The patient was referred to the medical oncology department for chemoradiotherapy with a diagnosis of metastatic invasive micropapillary carcinoma of the breast.

Discussion

It is rare for extragenital organ cancers to spread to genital organs. After gastrointestinal cancers, breast cancer is the most common cancer to metastasize to genital organs. One study in the literature analyzed 52 cases of breast cancer that metastasized to gynecological organs and found that 46 of these metastasized to the ovaries, while only 2 were to the uterus³. The majority of breast cancer metastases to the uterus have consisted of invasive lobular and invasive ductal carcinomas (or invasive carcinoma of the breast of no special type, according to the new classification). Invasive micropapillary carcinoma of the breast was first described by Siriaunkgul and

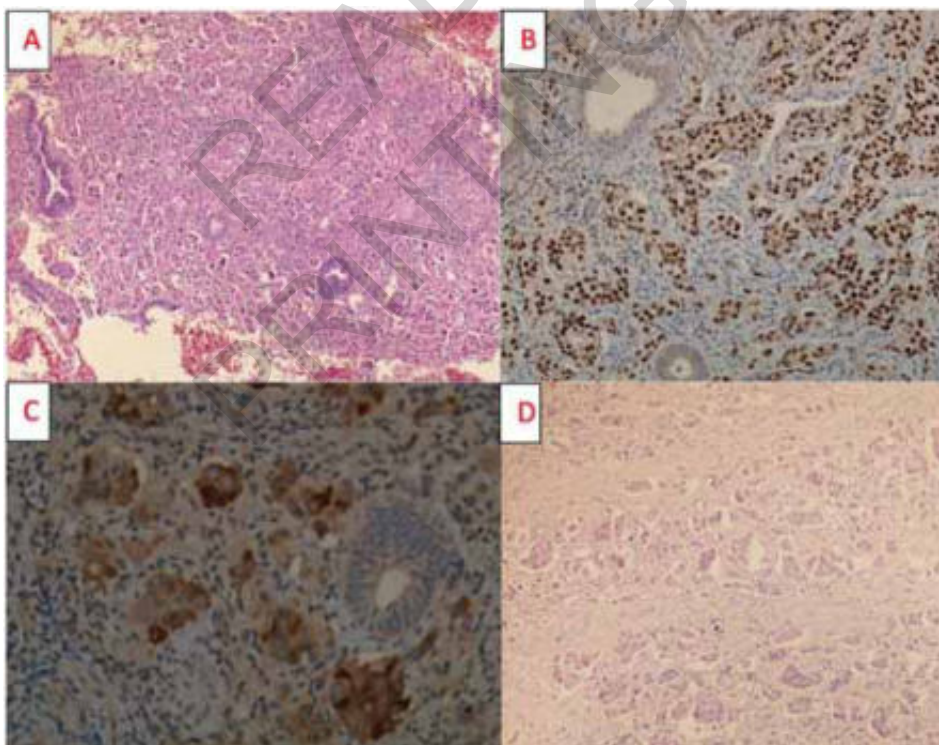


Fig. 1: A) Normal endometrium involve with micropapillary carcinoma of breast(HE x10); B) Diffuse, nuclear pattern of immunostaining for GATA 3 in tumor cells (GATA 3x20); C) Tumor cell Show patchy positive for GCDFP15 (GCDFP15x40); D) Clusters of neoplastic micropapillary cells surrounded by clear spaces in breast parenchyma (HE x 20) similar to metastatic endometrium in Fig. 1A.

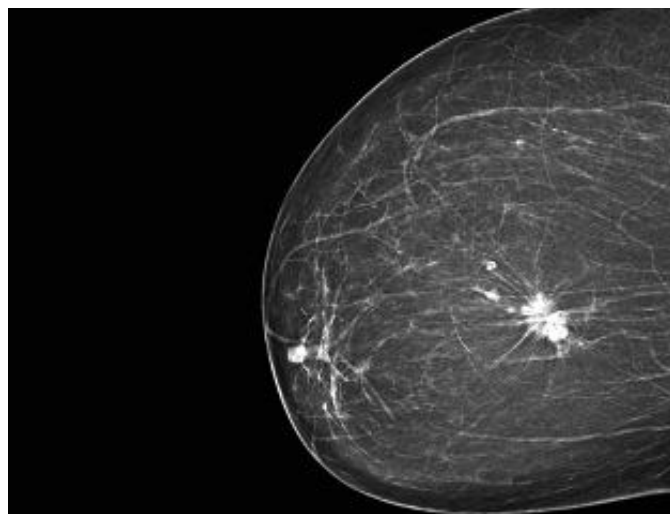


Fig. 2: Irregular and spiculated contour that created stromal distortion in the right breast mammography.

Tavassoli in 1993⁶. Ramalingam et al. reported metastasis to the urinary bladder and endometrium in a patient who had been treated for microinvasive breast cancer for 2 years⁷.

Invasive micropapillary carcinoma most commonly involves the breast, urinary bladder, lung, ovary, and colorectum. It has rarely been reported in metastatic endometrial cancers⁷. Morphologically, invasive micropapillary carcinoma is characterized by cell clusters that are surrounded by lacunar spaces in fibrous stroma. Micropapillary carcinomas can be distinguished from papillary carcinomas by a lack of fibrovascular cores. The lacunar spaces are lined by delicate strands of fibro collagenous stroma that do not have an endothelial lining. It is assumed that these spaces are artifacts of retraction. For the patient herein, PAX8, WT1, and p53 were test-

ed to differentiate the tumor from ovarian serous tumors with micropapillary features. Scarce data exist regarding uterine involvement in ovarian carcinoma epithelial ovarian cancers (EOC), and ovarian and endometrial carcinomas are estimated to be concomitant in approximately 3%-10% of EOC patients. Over 95% of ovarian serous carcinomas are PAX-8-positive⁸. WT-1 is typically expressed in serous carcinoma of the upper genital tract; however, it has been reported to be expressed in a small percentage of carcinomas of the breast⁹. The biopsy samples of the patient herein tested negative for PAX, WT1, and p53.

The specimen was tested for GCDF-15 and GATA-3 to investigate whether the tumor originated from breast tissue. GCDFP-15 is a highly sensitive and specific marker for the differential diagnosis of breast cancer. GATA-3 is also used for the differential diagnosis of cancers of the breast; however, its sensitivity for triple-negative carcinomas of the breast is 70% when compared to 95% for ER-positive breast carcinomas.

Most reported cases of metastasis to the uterus have indicated a history of breast cancer diagnosis and treatment^{10,11}. To the best of our knowledge, there have only been 2 reported patients who did not have a history of breast cancer, yet were diagnosed with breast carcinoma following metastasis to the uterus^{12,13}. In both cases, the patients presented with AUB and were diagnosed with invasive ductal carcinoma of the breast. Similarly, the patient herein presented with complaints of AUB and did not have a known history of breast cancer. The endometrial biopsy revealed micropapillary carcinoma, a rare type of invasive breast cancer with poor prognosis.

Conclusion

In postmenopausal AUB, it should be consider the possibility of metastatic spread of breast cancer to the

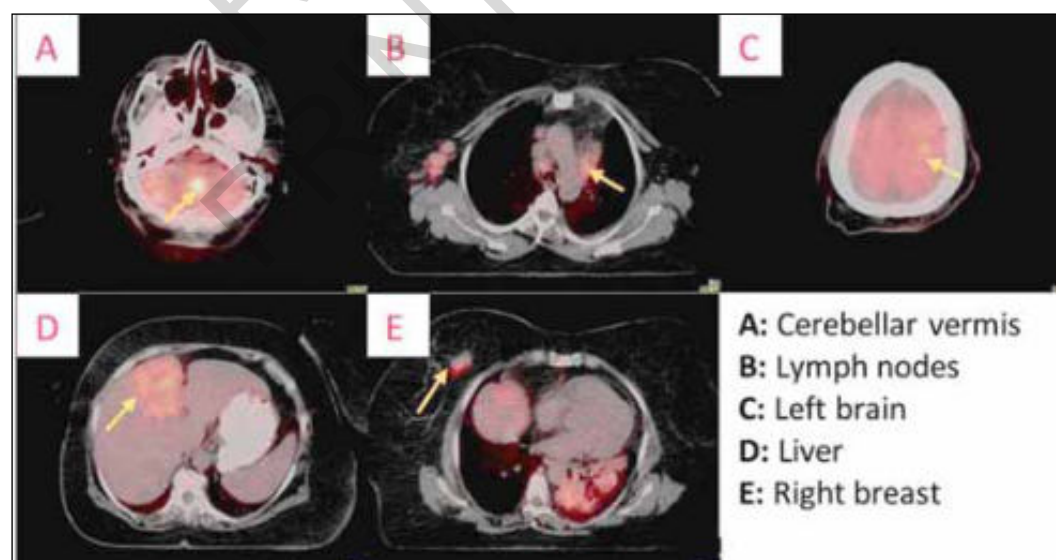


Fig. 3: Metastatic lesion images on positron emission tomography.

endometrium, especially in underdeveloped and developing countries where regular breast cancer screening is not achieved. In addition, in this group of patients, pathologists should keep in mind about metastatic spread of other cancer type other than endometrial cancer while examining the biopsy material.

Riassunto

La metastatizzazione del cancro del seno all'utero è piuttosto rara. La maggior parte dei casi segnalati si riferisce a carcinomi duttali e lobulari invasivi della mammella già noti in precedenza. Qui si presenta il raro caso di carcinoma micropapillare invasivo della mammella che è stato diagnosticato tramite biopsia endometriale, senza una precedente diagnosi o storia di cancro al seno. Si trattava di una paziente di 58 anni in postmenopausa, che non aveva una storia di cancro, ma si presentava con segnalazione di anomalo sanguinamento uterino (AUB) che era iniziato 2 settimane prima. Dopo aver ecografia transvaginale, la biopsia endometriale, la tomografia e la tomografia a emissione di positroni / tomografia computerizzata, è stato preminarmente diagnosticato alla paziente un carcinoma invasivo della mammella. La biopsia ha confermato la diagnosi di carcinoma micropapillare metastatico invasivo della mammella. Nell'AUB postmenopausale, è necessario tenere presente le metastasi endometriali del cancro al seno, specialmente nei paesi sottosviluppati e in via di sviluppo in cui non è stato raggiunto uno screening regolare del cancro al seno.

References

1. Kumar NB, Hart WR: *Metastases to the uterine corpus from extra genital cancers. A clinic pathologic study of 63 cases.* Cancer, 1982; 50: 2163-169.
2. Hara F, Kiyoto S, Takabatake D, Takashima S: *Endometrial metastasis from breast cancer during adjuvant endocrine therapy.* K, Ohsumi S, et al.: Case Reports in Oncology. 2010; 3: 137-41.
3. Mazur MT, Hsueh S, Gersell DJ: *Metastases to the female genital tract: Analysis of 325 cases.* Cancer, 1984; 53(9): 1978-984.
4. Paterakos M, Watkin WG, Edgerton SM, Moore II DH, Thor AD: *Invasive micropapillary carcinoma of the breast: A prognostic study.* Human pathology. 1999; 30: 1459-463.
5. Middleton LP, Tressera F, Sobel ME, Bryant BR, Albuquerque A, Grases P, et al.: *Infiltrating micropapillary carcinoma of the breast.* Modern pathology. 1999; 12: 499-504.
6. Siriaunkgul S, Tavassoli FA: *Invasive micropapillary carcinoma of the breast.* Modern pathology: an official journal of the United States and Canadian Academy of Pathology, Inc, 1993; 6(6), 660-62.
7. Ramalingam P, Middleton LP, Tamboli P, Troncso P, Silva EG, Ayala AG: *Invasive micropapillary carcinoma of the breast metastatic to the urinary bladder and endometrium: Diagnostic pitfalls and review of the literature of tumors with micropapillary features.* Annals of diagnostic pathology, 2003; 7: 112-19.
8. Xiang LI, Kong B: *PAX8 is a novel marker for differentiating between various types of tumor, particularly ovarian epithelial carcinomas.* Oncology letters, 2013; 5(3), 735-38.
9. Moritani S, Ichihara S, Hasegawa M, Endo T, Oiwa M, Yoshikawa K, et al.: *Serous papillary adenocarcinoma of the female genital organs and invasive micropapillary carcinoma of the breast. Are WT1, CA125, and GCDFP-15 useful in differential diagnosis?* Human Pathology, 2008; 39: 666-71.
10. Gomez M, Whitting K, Naous R: *Lobular breast carcinoma metastatic to the endometrium in a patient under tamoxifen therapy: A case report.* SAGE Open Med Case Rep, 2020; 16;8.
11. Arif SH, Mohammed AA, Mohammed FR: *Metastatic invasive lobular carcinoma of the breast to the endometrium presenting with abnormal uterine bleeding: Case report.* Ann Med Surg (Lond). 2020; 51:41-43. doi: 10.1016/j.amsu.2020.01.008.
12. Rahmani M, Nili F, Tabibian E: *Endometrial Metastasis from Ductal Breast Carcinoma: A Case Report with Literature Review.* The American Journal of case reports, 2018; 19, 494.
13. D'souza MM, Sharma R, Tripathi M, Saw SK, Anand A, Singh D, et al.: *Cervical and uterine metastasis from carcinoma of breast diagnosed by PET/CT: An unusual presentation.* Clinical nuclear medicine; 2010; 35: 820-23.