

# Kidney transplantation and large anastomotic pseudoaneurysm.

## Transplant management considerations



Ann. Ital. Chir., 2013 84: 275-279

Published online 29 October 2012

pii: S0003469X12020258

[www.annitalchir.com](http://www.annitalchir.com)

Michele L. Santangelo\*, Umberto M. Bracale\*\*, Nicola Carlomagno\*\*\*, Davide De Rosa\*, Sergio Spiezia\*, Alessandro Scotti\*, Vincenzo Tammaro\*, Massimo Porcellini°, Andrea Renda\*

\*Department of Surgery, Anesthesia and Emergency Science, School of Medicine, O.U. of General Surgery and Organ Transplantations, University of Naples "Federico II", Italy.

\*\*O.U. of Vascular Surgery, University of Palermo, Italy.

\*\*\*Department of Surgery, Anesthesia and Emergency Science, School of Medicine, University of Naples "Federico II", Italy. O.U. of General and Abdominal Surgery

°Department of Surgery, Anesthesia and Emergency Science, School of Medicine, University of Naples "Federico II", Italy. O.U. of Vascular Surgery

### Kidney transplantation and large anastomotic pseudoaneurysm. Transplant management considerations

**AIM:** Pseudoaneurysm (PA) at the anastomosis site in kidney transplantation is a rare but serious complication that usually requires graft nephrectomy. Literature reports are sporadic and usually focused on limb rather than graft salvage. In this paper we focus on this last point.

**MATERIAL OF STUDY:** 6 patients presenting large PA at the anastomosis between iliac and graft artery were identified in our series. The diagnosis was performed with US, AngioTC scan and angiography. Blood cultures and labeled leukocyte scintigraphy were also performed. All patients underwent open surgery.

**RESULTS:** Transplant nephrectomy was needed in all cases except one, in which it was possible to perform a graft replanting on hypogastric artery. Our perioperative mortality and morbidity rate was recorded.

**DISCUSSION:** Etiology of PA is multifactorial, however an association with chronic rejection or infection must be also considered. Our mortality and morbidity rates are in accordance to literature. In our experience we observed only large PA so to require an open surgery but this approach has allowed the rescue of graft functioning just in a single case. Endovascular procedures are linked to higher rate of graft salvage than surgery but they can be used just in selected cases.

**CONCLUSIONS:** Our experience and literature review led us to believe that the rate of graft salvage in patients with large PA at anastomosis site could be improved only by a planned therapeutic program that includes surgical and endovascular approach, taking the advantages of both technique and overcoming their limits.

**KEY WORDS:** Anastomotic pseudo-aneurysm, Surgical treatment, Transplantation nephrectomy, Kidney transplantation.

### Introduction

Kidney transplant is the best treatment for end-stage chronic renal failure<sup>1</sup>. The average life of transplanted

kidney is 10-15 years, ranging between few months to 20-30 years<sup>1-4</sup>. The main cause of loss of transplanted kidneys is the rejection, while only a small number of grafts are lost due to surgical complications<sup>5</sup>, such as urological and vascular problems<sup>6-8</sup>. Arterial complications represent about 5% of graft dysfunction causes<sup>9,10</sup>. The renal artery stenosis are the most common, while pseudoaneurysms (PA) are very rare (approximately 1% of arterial post-transplant complications)<sup>11-15</sup>. The pseudo-aneurysm of renal graft is a life and graft impaired post-transplant complication that usually requires transplant nephrectomy.

Pervenuto in Redazione Agosto 2012. Accettato per la pubblicazione Settembre 2012

Correspondence to: Prof. Michele L. Santangelo MD, Università degli Studi di Napoli Federico II - Facoltà di Medicina e Chirurgia, Via S. Pansini 5, 80131, Napoli - Dipartimento Universitario di Scienze Chirurgiche, Anestesiologiche, Rianimatorie e dell'Emergenza (e-mail: [michele.santangelo@unina.it](mailto:michele.santangelo@unina.it))

## Material of study

Over the past 30 years we observe 6 patients with PA of anastomotic site between graft and iliac artery (Fig. 1). Two patients were transplanted in our center, while 4 originated from other Transplant Centers.

In all cases the diagnosis was made on US, followed by a AngioCT scan. Three patients also underwent to angiography procedure before the operation. Labeled leukocyte scintigraphy was performed just in 2 patients. All patients underwent blood cultures. Two patients had fever on admission, including 1 with positive blood culture for *Candida Albicans*. Patient infected with *Candida* was treated with antifungal therapy based on intravenous amphotericin B for 3 weeks. The other patient with fever presented always negative blood cultures and negative urine culture and was treated with empirical antibiotic therapy. In a patient with negative blood cultures, the culture of the pseudo-aneurysm wall after surgery showed a mixed infection (*Candida* / *Staphylococcus*).

Just a patient developed a pseudo-aneurysm early, within 3 months after transplantation. One patient (Case 5), before surgery, was subject to an unsuccessful treatment of percutaneous embolization of pseudoaneurysm.

All clinical data of our patients (age, size, interval from transplantation, symptoms, culture sampling, treatment, complication and outcome) are summarized in Table I.

One patient died in post operative period, while no one showed signs of impaired vascular supply to inferior limb. Three patients developed major complications.

## Results

Our patients were all treated with open surgery because they were symptomatic and/or had large aneurysms (4.6-12.0 cm). In our experience transplant kidney patients with anastomotic pseudoaneurysm showed a high morbidity rate with a high percentage of losing transplanted organ. In 2 patients although a conservative procedure had been planned, during surgery we were forced to perform transplant nephrectomy for technical difficulties and for saving patient's life. In other 3 patients transplant nephrectomy was preoperatively planned for impaired/loss of graft function. So 5/6 of our patients were operated on graft nephrectomy. Just in case n.2 was possible to perform a graft replanting on hypogastric artery: this patient presented an acceptable kidney function over the following 4 years.

In all patients, the vascular supply of lower limb was secured by implanting a prosthesis and we did not observe complications directly related to this procedure (Table I). Our perioperative mortality rate was acceptable. Just one patient died on 10<sup>th</sup> post operative day of MOF.

TABLE I - Clinical data of patients with anastomotic pseudoaneurism.

Patient (Sex)	Age (y)	Size (cm)	Interval from transplantation	Symptoms	Culture	Treatment	Complications	Outcome
Case 1 (M)	43	5.8	7 mo	Pulsatile mass	Negative	Excision and interposition graft (polyester) Transplant nephrectomy	–	Alive
Case 2 (F)	39	5.5	49 mo	Asymptomatic	Negative	Excision and interposition graft (polyester) Omolateral hypogastric artery replanting	–	Alive
Case 3 (F)	40	6.8	78 days	Fever, local pain, tender mass	<i>Candida A</i>	Excision, ePTFE crossover femoral-femoral graft Transplant nephrectomy	Pneumonia	Alive
Case 4 (M)	67	15 (rupture)	5 mo	Sudden abdominal pain, hypotension	Negative	Stent grafting Transplant nephrectomy	Wound infection and dehiscence	Alive
Case 5 (M)	50	12	7 mo	Anemia, local pain, tender mass	Negative	Excision and interposition graft (silver polyester) Transplant nephrectomy	Iliac fossa abscess and wound infection Sepsis	Exitus (MOF) 10 days after treatment
Case 6 (M)	47	4.7	10 mo	Fever, pulsatile mass	<i>Candida A</i> <i>Staph E</i>	Excision and interposition graft (silver polyester) Transplant nephrectomy	–	Alive

## Discussion

Vascular complications represent an important cause of morbidity and mortality after renal transplantation. The factors predisposing to vascular complications are: vascular suturing failure, kinking of the renal artery, instrumental damage during perfusion, dissection of vasa vasorum, surgeon's experience and immunological mechanisms<sup>5,16,17</sup>.

PA are a rare vascular complications and can be localized inside the graft or at anastomotic site.

Intrarenal PA in many cases are due to arterial injury during percutaneous biopsy, more rarely during perfusion procedures<sup>18,19</sup>. The intrarenal PA are frequently asymptomatic and self-limiting, although some patients present a massive hematuria due to spontaneous opening of the aneurysm in the urinary tract. The best treatment of intrarenal PA is the embolization of the damaged vessel with angioscopic techniques. This procedure is always associated to good results and high rate of graft salvage.

Extrarenal PA may affect the anastomotic site between iliac and renal arteries and their etiology is attributable to vascular suturing technical errors or mycotic/bacterial infection. Surgical technique defects or vessel wall ischemia are the main causes in most cases when PA appears early, usually few weeks after transplantation<sup>20</sup>. A late presentation (after 6 years) is a rare condition and

usually related to infection, although Buckley and colleagues reported an interval of 7 years<sup>21</sup>. Only one of our patients developed a PA early (3 months) while the others had a mean time of onset of 15.6 months (range 5-49).

The symptomatology of the PA is vary: pain at the implant site, fever and leukocytosis<sup>22,23</sup>, chronic deterioration of renal function<sup>24</sup>. Also our patients had heterogeneous symptoms, ranging from stable clinical presentation to emergency, as showed in Table I.

US, CT and angioCT are considered as the golden standard imaging procedure to diagnose PA by many authors. Angiography should be indicated only if it is used also as a therapeutic procedure. Labeled leukocyte scintigraphy has not yet showed its value in anastomotic PA diagnostic protocol. In our experience, scintigraphy was performed just in 2 cases but with little reliability: a false negative result despite of infection positive culture of PA wall (case n. 6).

Siu<sup>25</sup> claims that small PA can be treated with conservative therapy with periodic ultrasound monitoring, as in Zavos' experience<sup>26</sup> concerning two patients treated with intravenous amphotericin for two months and a stent placement before retransplanting with good results in 2 years follow-up. Broken, large or infected PA should be treated surgically<sup>27,28</sup>. Open conservative technique contemplates direct suture or graft removal/replanting with patch or other vessels (hypogastric artery, contralateral iliac axis). These techniques are highly invasive and threaten graft survival, furthermore there is a high probability of recurrence or dissemination when PA is infected. So transplant nephrectomy is the most common technique performed in these cases for the high risks linked to the conservative techniques (including rebleeding).

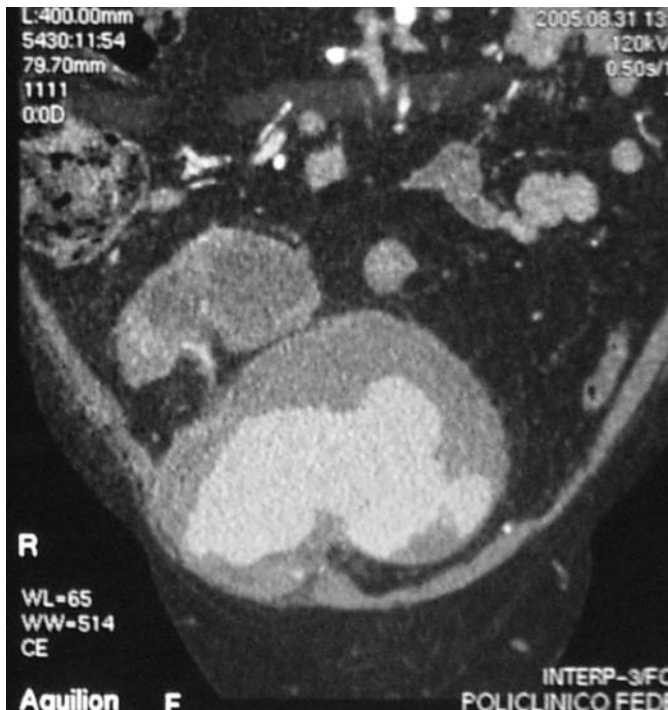

Fig. 1: Anastomotic pseudoaneurysm: Massive pseudo aneurysm from which originates renal artery of the graft filled by contrast at AngioCT coronal reconstruction study.

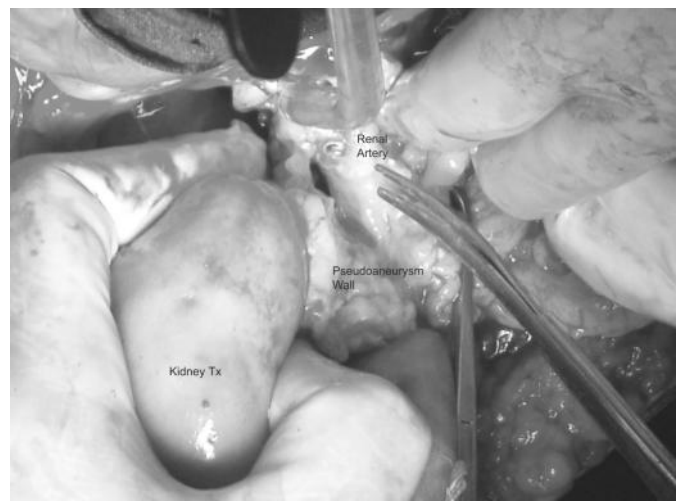


Fig. 2: Previous case. Intraoperative image. Transplant nephrectomy. Are recognizable the kidney, part of pseudoaneurysm wall in the context of which is visible the lumen of the sectioned renal artery.

The analysis of these data from literature and from our series leads us to formulate some considerations:

- 1) The anastomotic PA should be identified early, and this condition can be fulfilled only with periodic ultrasound monitoring in post-transplant follow up.
- 2) Blood cultures are essential, especially a blood sample directly from the PA, when possible.
- 3) The embolization is good technique and has a good success rate when applied to intrarenal PA.
- 4) Conservative procedures should be considered in patients in good condition with preserved graft function and without symptoms or signs of infection. Their adoption must take in account the following points: a) graft removal/replanting procedure is linked to high failure rate for the great technical difficulties; b) placement of endoprostheses covering the iliac artery-anastomosis to seal leaks is a good technical option but it requires a graft removal/replanting or its revascularization by hypogastric artery or patch. However these procedures are associated with high failure and complications rate; c) placement of endoprostheses covering the iliac-anastomosis-graft artery to seal leaks have to be preferred but requires revascularization of femoral axis by extra-anatomical bypass (possibly a femoral-femoral bypass), procedures with a low risk rate than the previous; d) para-surgical procedure, when indicated, are preferable to open surgery for their good results and low complications.
- 5) When performing conservative procedures close follow up is always needed for long time.
- 6) Direct open surgical approach to repair the PA can lead, with high probability, to a final graft removal and a reconstruction of vascular continuity with a prosthesis.
- 7) The early PA are frequently due to errors in the execution of vascular suture and have a higher cure rate.

## Conclusions

Surgical treatment of kidney transplanted patients with large PA usually need graft nephrectomy. We believe that previously exposed topics should be taken in consideration for the management of these patients to increase graft salvage rate. This goal could be achieved only by planned therapeutic programs including surgical and endovascular approach, taking the advantages of both technique and overcoming their specific limits.

## Riassunto

**PREMESSE:** Gli pseudo aneurismi anastomotici (PA) di grosse dimensioni rappresentano una rara ma temibile complicanza del trapianto di rene che generalmente richiede l'espianto del graft. In letteratura sono presenti solo sporadici reports, generalmente focalizzati sulle problematiche connesse con il salvataggio dell'arto piuttosto

che con quello del graft. In questo lavoro ci soffermeremo su quest'ultimo punto

**MATERIALI E METODI:** In oltre 30 anni abbiamo osservato 6 pazienti con PA tra l'arteria iliaca e l'arteria del graft. La diagnosi è stata effettuata con ecografia, angioTC, angiografia, emocolture e, in alcuni casi, scintigrafia con leucociti marcati. Tutti i pazienti sono stati sottoposti a riparazione a cielo aperto.

**RISULTATI:** L'espianto del rene è stato necessario in tutti i casi tranne uno, in cui è stato possibile eseguire una reimpianto dell'organo sull'arteria ipogastrica. Il tasso di morbidità e di mortalità perioperatoria è stato accettabile.

**DISCUSSIONE:** L'eziologia del PA è multifattoriale, tuttavia, una associazione con rigetto cronico o infezione deve sempre essere presa in considerazione. Il tasso di morbidità e di mortalità che abbiamo registrato è in linea con quello della letteratura. Nella nostra esperienza abbiamo osservato solo PA di grosse dimensioni per cui l'approccio "open" è stato il nostro metodo di scelta per il trattamento di questa patologia, sebbene ci abbia permesso di salvare il graft in un solo caso. Le procedure endovascolari, sebbene si associno ad un tasso più alto di salvataggio del graft, possono essere utilizzate solo in casi selezionati.

**CONCLUSIONI:** La nostra esperienza e la revisione della letteratura ci porta a ritenere che solo un programma terapeutico ben pianificato e che fonda l'approccio open con quello endovascolare può aumentare il tasso di salvataggio dei graft nei pazienti sottoposti a trapianto di rene ed affetti da PA anastomotici di grosse dimensioni.

## References

1. Santangelo M, De Rosa P, Spiezia S, et al.: *Healing of surgical incision in kidney transplantation: A single transplant center's experience.* Transplant Proc, 2006; 38 (4), 1044-46.
2. Santangelo M, Zuccaro M, De Rosa P, et al.: *Older kidneys donor transplantation: five years' experience without biopsy and using clinical laboratory and macroscopic anatomy evaluation.* Transplant Proc, 2007; 39 (6), 1835-837.
3. Santangelo M, Clemente M, Spiezia S, et al.: *Wound complications after kidney transplantation in nondiabetic patients.* Transplant Proc, 2009; 41(4), 1221-223.
4. Picascia A, Giannattasio P, Grimaldi V, et al.: *Preliminary analysis of kidney transplantation in Naples from 2000 to 2006.* Tissue Antigen, 2012; 79(6):502.
5. Rijksen JFWB, Koolen MI, Walazewski JE, et al.: *Vascular complications in 400 consecutive renal allotransplants.* J Cardiovasc Surg 1982; 2:91-98.
6. Gerbens D, Teyssou H, Manteau G, et al.: *Ultrasonography and surgical complications after kidney transplants.* JOP 2012; 13(1):83-86.
7. Yap R, Madrazo B, OH HK, et al.: *Perirenal fluid collection after renal transplant.* Int J Surg Pathol, 2009; 17(3):250-54.
8. Santangelo M, Clemente M, De Rosa P, et al.: *The finding of*



*vascular and urinary anomalies in the harvested kidney for transplantation.* Transplant Proc, 2007; 39(6):1797-99.

9. Jordan ML, Cook GT, Cardella CJ, et al.: *Ten years of experience with vascular complications in renal transplantation.* J Urol, 1982; 128:689-92.

10. De Rosa P, Santangelo M, Ferrara A, et al.: *Suboptimal kidney: The experience of a single transplant unit.* Transplant Proc, 2004; 36(3), 488-90.

11. Palleschi J, Novick AC, Braun WE, et al.: *Vascular complications of renal transplantation.* Urology, 1980; 16:61-7.

12. Goldman MH, Tilney NL, Vineyard GC, et al.: *A twenty year survey of arterial complications of renal transplantation.* Surg Gynecol Obstet, 1975; 141:758-60.

13. Hohnke C, Abendroth D, Schleibner S, et al.: *Vascular complications in 1,200 kidney transplantations.* J Exp Clin Can Res, 2009; 28(1):861.

14. Grenier N, Douws C, Morel D, et al.: *Detection of vascular complications in renal allografts with color Doppler flow imaging.* Radiology, 1991; 178:217-23.

15. Bracale UM, Santangelo M, Carbone F, et al.: *Anastomotic pseudoaneurysm complicating renal transplantation: treatment options.* Eur J Vasc Endovasc Surg, 2010; 39(5):565-68.

16. Santangelo M, Spinosa G, Grassia S, et al.: *In situ elongation patch in right kidney transplantation.* Transplant Proc, 2008; 40(6):1871-72.

17. Grimaldi V, Picascia A, Giannattasio P, et al.: *Kidney transplantation and immunohematological profile in Naples: A coordinating regional experience from 2000 to 2006.* Vox Sanguinis 2012; 103 (Supp 1) Pages: 269.

18. Dodd GD III, Tublin ME, Shah A, et al.: *Imaging of vascular complications associated with renal transplants.* AJR 1991; 157:449-59.

19. Moreau JF, Merland JJ, Descamps JM, et al.: *Post-biopsy false arterial aneurysm of a transplanted kidney: Treatment by bucrylate transcatheter embolization.* J Urol 1982; 128:116-18.

20. Baxter GM: *Ultrasound of renal transplantation.* Clin Radiol, 2001; 56(10):802-18.

21. Buckley JG, Salimi Z, George E, et al.: *Late onset renal allograft anastomotic pseudoaneurysm with absent Doppler signal.* J Urol, 1992; 148:392.

22. Ngan CY, Luke PP: *Renal artery pseudoaneurysm of infectious etiology: A life-threatening complication after renal transplantation.* Urology, 2006; 68:668-69.

23. Taghavi M, Shojaei A, Mehraei R, et al.: *Late onset anastomotic pseudoaneurysm of renal allograft artery: Case report, diagnosis, and treatment.* Transplant Proc, 2005; 37:4297-299.

24. Peel RK, Patel J, Woodrow G, et al.: *Iliac artery false aneurysm following renal allograft: Presentation with non-specific inflammatory response and treatment by endovascular stent graft.* Nephrol Dial Transplant, 2003; 18:1939-940.

25. Siu YP, Tong MK, Leung KT, et al.: *Renal artery pseudoaneurysm following renal transplantation and treatment by percutaneous thrombin injection.* Hong Kong Med J, 2006; 12:80-81.

26. Zavos G, Pappas P, Kakisis JD, et al.: *Endovascular repair as first-choice treatment of iliac pseudoaneurysms following renal transplantation.* Transplant Proc, 2005; 37:4300-02.

27. Kyriakides GK, Simmons RL, Najarian JS, et al.: *Mycotic aneurysms in transplant patients.* Arch Surg, 1976; 111:472-76.

28. Koo CK, Rodger S, Baxter GM, et al.: *Extrarenal pseudoaneurysm: An uncommon complication following renal transplantation.* Clin Radiol, 1999; 54:755-58.

