

# Thoracotomy versus triportal VATS in pulmonary hydatid cyst surgery:

## A single center experience



Ann Ital Chir, 2022 93, 5: 517-523

pii: S0003469X22034145

Online ahead of print 2022 - July 4

free reading: www.annitalchir.com

Gürhan Öz\*, Suphi Aydin\*, Adem Gencer\*\*, Ahmet Dumanli\*, Elif Baki\*\*\*, Suleyman Emre Akin\*\*\*\*, İsa Dongel\*\*\*\*

\*Department of Thoracic Surgery, Afyonkarahisar Health Science University, Afyonkarahisar, Turkey

\*\*Department of Thoracic Surgery, Afyonkarahisar State Hospital, Afyonkarahisar, Turkey

\*\*\*Department of Anesthesiology, Afyonkarahisar Health Science University, Afyonkarahisar, Turkey

\*\*\*\*Department of Thoracic Surgery, SDU Medical Faculty, Isparta, Turkey

### Thoracotomy versus triportal VATS in pulmonary hydatid cyst surgery: a single center experience

**OBJECTIVE:** The aim of this study was to compare triportal videothoroscopic thoracic surgery and thoracotomy in pulmonary hydatid cyst surgery to help determine the most appropriate surgical method according to the characteristics of the pulmonary hydatid cyst.

**METHODS:** The study included 57 patients who underwent thoracotomy and triportal videothoroscopic thoracic surgery (TVATS) due to lung cystic disease between January 2012 and March 2019. The patients were separated into two groups as TVATS and Thoracotomy groups. Statistical comparisons were made of the groups in terms of age, visual analog (VAS) pain score, length of hospital stay, length of surgery, complications, ASA score and cyst features. Probability values less than  $p = 0.05$  were considered significant.

**RESULTS:** Length of surgery, and length of hospital stay were significantly longer and ASA score, postoperative VAS pain scores, total number of cysts, and cyst sizes were found to be significantly higher in the Thoracotomy Group. There was no significant difference between the groups in respect of age, gender and postoperative complications.

**CONCLUSION:** Triportal Videothoroscopic Surgery (TVATS) in the treatment of pulmonary hydatid cyst surgery was seen to be superior to thoracotomy in respect of operation and hospitalization time, and postoperative pain scores. While videothoroscopic cyst excision and capping can be performed more easily than giant cysts in peripheral and 10 cm cysts, it is more difficult in central and giant cysts. Considering that it may cause bronchopleural fistulae if not done well, it may be appropriate to prefer thoracotomy, especially in giant cysts, until they have sufficient experience with VATS.

**KEY WORDS:** Pulmonary hydatid cyst, Triportal VATS, Thoracotomy

### Introduction

Hydatid cyst (HC) is a zoonotic disease caused by echinococcus granulosus larvae<sup>1,2</sup>. It is widespread all over the world<sup>3</sup>. Surgical treatment is preferred primarily in the treatment of pulmonary hydatid cyst.

Medical treatment with benzimidazoles is used to prevent recurrence in patients cyst size of < 6 cm not suitable for surgery, and after cyst surgery<sup>3-5</sup>. Open surgery (thoracotomy and sternotomy) and video assisted thoracoscopic surgery (VATS) are used in the treatment of pulmonary hydatid cysts<sup>5</sup>. The aim of both methods is to aspirate the cyst fluid properly, remove the parasite from the host, prevent recurrence and leave as much healthy tissue as possible<sup>6,7</sup>. VATS reduces postoperative complications related to intercostal pain compared to open thoracic surgery. However, pulmonary hydatid cyst VATS case series are limited due to severe adhesions, size of cyst cavity, hemoptysis, prolonged air leak, difficulties in bronchopleural fistula control<sup>8</sup>.

Pervenuto in Redazione Luglio 2020. Accettato per la pubblicazione Luglio 2020

Correspondence to: Gürhan Öz, MD, Prof Afyon Health Science University School of Medicine, Department of Thoracic Surgery, 03200 Afyonkarahisar, Turkey (e-mail: gurhanoz06@gmail.com)

The aim of this study was to help determine the most appropriate method for patients by comparing the clinical features, and operation results of patients who underwent Triportal VATS and thoracotomy due to pulmonary hydatid cyst and to contribute to the literature.

## Material and Methods

A retrospective analysis was made of the medical records of 57 patients (26 male and 31 female) who were operated on between January 2012 and March 2019 due to pulmonary hydatid cyst. The demographic characteristics of all patients were collected together with perioperative information. The mean age was  $44.44 \pm 14.68$  years (range, 12-66 years) in the TVATS group and 36.81 years (range, 13-79 years) in the thoracotomy group. The symptoms on hospital admission were cough (48%), hemoptysis (10.5%), abdominal pain (8%), swelling of the face and neck (vena cava superior syndrome) (2%), chest pain (10.5%), and 12 patients (12%) were asymptomatic (Table I). Preoperative chest radiography and computed thorax tomography were performed in all patients, and blood count and biochemistry tests were examined. The patients were separated into 2 groups as Thoracotomy and Triportal Vats (TVATS) groups. The total number of cysts was 54 (64%) in the Thoracotomy group and 31 (36%) in the TVATS group. In 8 patients applied with TVATS, the surgery was changed to open thoracotomy due to single lumen tube intolerance ( $n = 3$ ), central localization ( $n = 3$ ) and adhesion ( $n = 2$ ), and these patients were then included in the thoracotomy group. Symptoms of dizziness and swelling in the face and neck (vena cava superior compression) were seen in 1 patient on presentation. (Fig. 1) For postoperative pain control, 2mg/kg/day tramadol hydrochloride and 2g/day paracetamol were used for both groups. The Visual analog scores (VAS) of both groups were measured 3 times a day for 2 days. These scores were then averaged and recorded.

TABLE I - Symptoms of Patients

Symptoms	(n)	(%)
Cough	27	48
Abdominal pain	5	8
Hemoptysis	6	10.5
Chest pain	6	10.5
Swelling of the face and neck	1	2
Asymptomatic	12	21
Total	57	100

Data obtained in the study were analyzed statistically using IBM SPSS Statistics vn. 18 software. Data were expressed as median, and mean  $\pm$  standard deviation (SD) values. The Student's t-test or the Mann Whitney U-test was used to compare continuous variables, and the Chi-square test was used to compare categorical variables. Probability values of  $p < 0.05$  were considered statistically significant.

Approval for this retrospective study was granted by the Ethics Committee of Afyon Health Sciences University and the need for patient consent was waived.

## Surgical Technique

In the Thoracotomy Group, standard posterolateral thoracotomy was performed in the patients by entering the 5th intercostal space in the lateral decubitus position. Sponges soaked with 2% povidone iodine were placed around the cyst. The cyst content was aspirated and the cyst membrane was removed. The cyst cavity was cleaned with sponges soaked with 2% povidone iodine. Bronchial communications were sutured with 2/0 and 3/0 vicryl, and the capitonnage procedure was performed to close the cavity. (Figs. 4 A, B). At the end of the operation, bupivacaine at a dose of 2mg/kg diluted with saline was applied to the 4th, 5th and 6th intercostal spaces and the pleural space. In patients with giant cysts, 2 chest

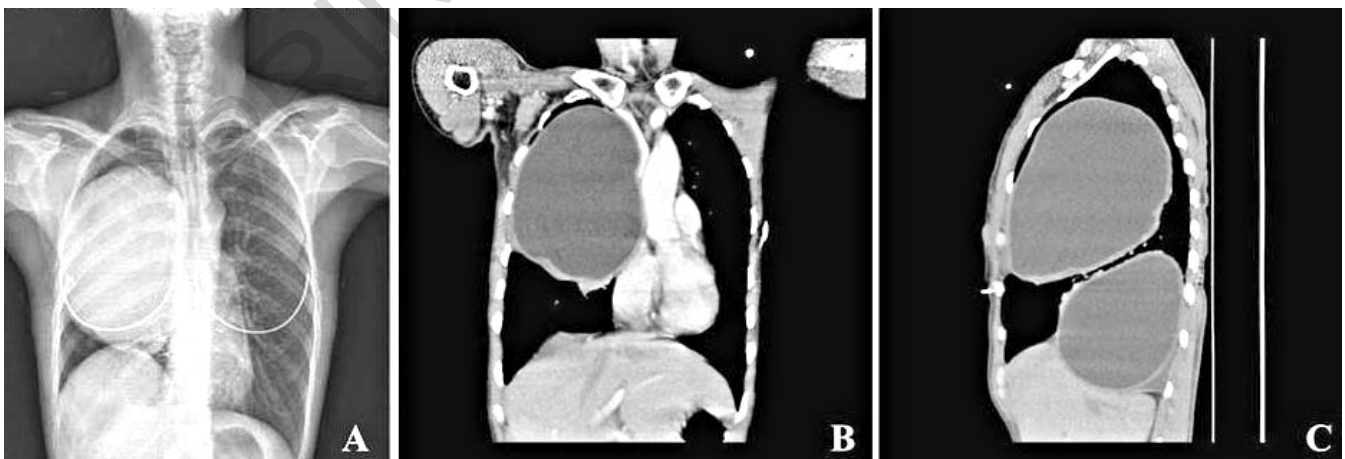


Fig. 1: Giant cyst compressing vena cava superior.

drains were placed and 1 chest drain was used for smaller cysts.

In the TVATS group, 3 thoracoports were used. After double lumen intubation, the first port was placed in the 6th intercostal space for the anterior axillary line for the 30° telescopic camera. The second thoracoport was placed in the anterior axillary line in the 4th intercostal space and the third thoracoport port was placed in the posterior axillary line in the 7th intercostal space. After double lumen intubation, sponges soaked with 2% povidone iodine were placed around the cyst to prevent contamination of the cyst. The cyst cavity was cleaned with sponges soaked with 2% povidone iodine. Bronchial communications were sutured with 2/0 and 3/0 vicryl, and the capitonnage procedure was performed to close the cavity. In cysts < 4 cm in size with peripheral localization, the cyst excision method was used with wedge resection using a stapler (Figs. 5 A,B,C). At the end of the operation, bupivacaine 2mg / kg diluted with saline was applied to the 4th, 5th, and 7th intercostal spaces and the pleural space. After checking for air leakage, a 24F chest drain was placed in the thorax.

## Follow Up

All patients were given albendazole treatment for 3 months after the operation. Liver function tests and chest x-rays were applied in follow-up examinations. Chest radiographs were repeated at 6 and 12 months, after which follow-up was terminated.

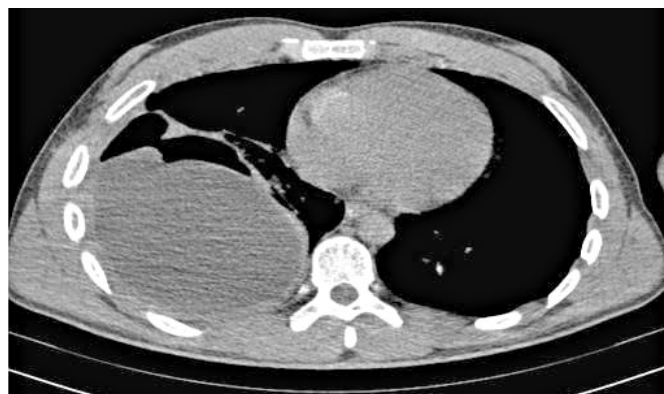

Fig. 2: Ruptured lower right lobe giant cyst.

## Results

The operation time (minutes) was found to be significantly longer in the Thoracotomy group compared to the TVATS group (116.03 ± 23.98 mins vs. 91.04 ± 23.40 mins p < 0.001).

The mean length of hospital stay was longer and postoperative first and second day visual analog scores (VAS1, VAS2) were significantly higher in the thoracotomy group (p= 0.04, p= 0.012, p < 0.01 respectively). No significant difference was found between the groups in respect of post-operative complications and ASA (American Society of Anesthesiologists) Scores (p= 0.094, p= 0.184) (Table II). The total number of pulmonary cysts, central cyst, and mean cyst diameter values were significantly higher in the

TABLE II - Perioperative Characteristics

	TVATS Group (n=25)	Thoracotomy Group (n=32)	p value
Gender			
Female	15	16,452*	
Male	10	16	
Age (years)	44,44±14,68	36,81±16,30	0,073&
Complications			
None	23	24,094*	
Present	2	8	
Length of surgery (minutes)	91,04±23,40	116,13±19,98	0,000&
ASA scor (n)			
1	12	14	
2	13	14	
3	0	40,184*	
Length of stay (days)	5(3-11)	5(4-12)	0,040#
VAS 1	5(3-7)	6(5-7)	0,012#
VAS 2	2(1-4)	5(3-6)	0,000#

\*Chi-Square, & T-test, #Mann-Whitney U test

VAS 1: Visual analog pain scor day 1; VAS 2: Visual analog pain scor day 2; ASA: American society anesthesiologists score

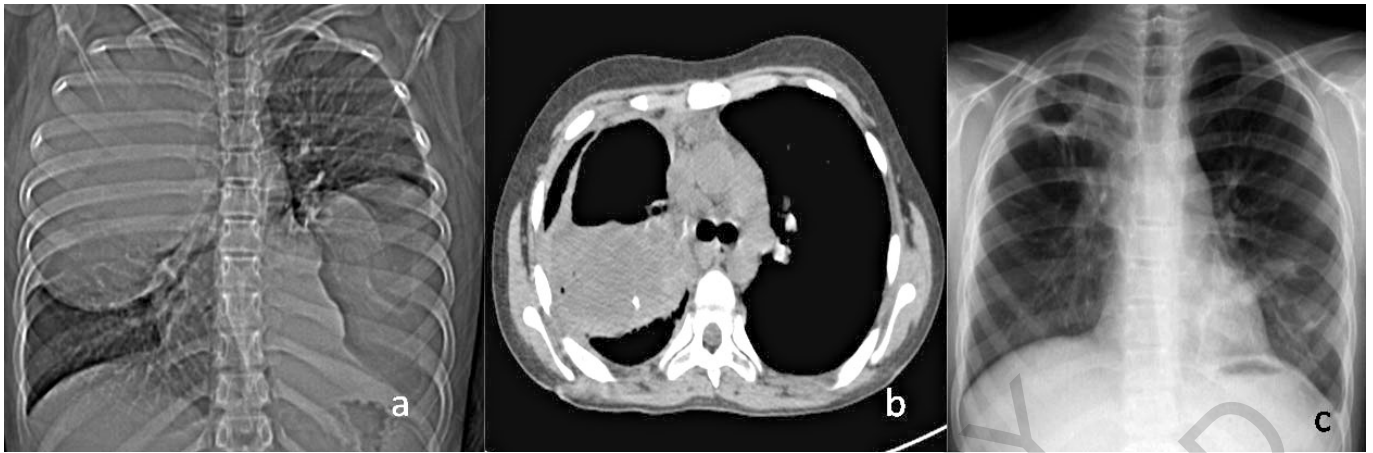


Fig. 3: A) Preoperative view of the cyst; B) Bronchopleural fistula; C) Chest x-ray after right upper lobectomy.

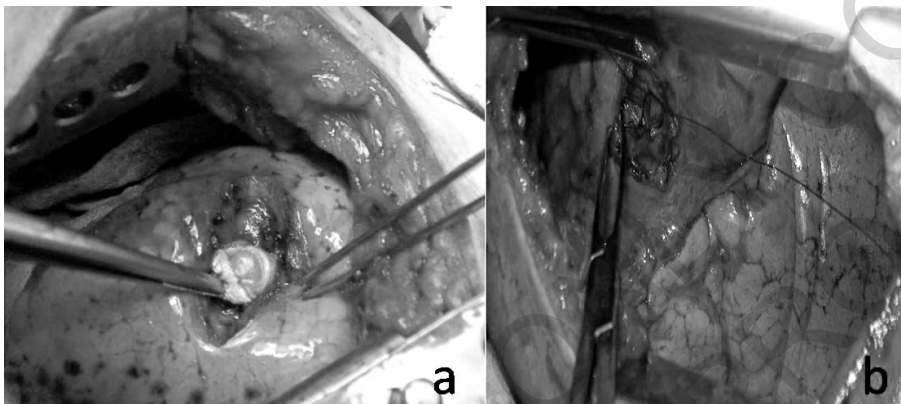


Fig. 4: Cystotomy and capping by thoracotomy.

Thoracotomy Group ( $p = 0.016$ ,  $p < 0.001$ ,  $p = 0.048$  respectively). The properties of cysts in both groups are shown in Table III. A patient with a cyst diameter of 20 cm in the thoracotomy group was urgently operated on and a lower right lobectomy was performed (Fig. 2). In the TVATS group, 1 patient underwent left lower lobectomy due to cyst size and lung destruction. In the thoracotomy group, re-thoracotomy was performed with left upper lobectomy in 1 patient because massive hemoptysis developed 10 days postoperatively, and in 1 patient with right upper lobectomy because of the development of bronchopleural fistula 11 days postoperatively (Fig. 3). There was no mortality perioperatively or in the 1-year follow-up period of both groups.

## Discussion

*Echinococcus granulosus* is a parasite which causes hydatid cyst (HC) disease worldwide, but especially in developing countries<sup>1,2</sup>. Although HC disease can affect the entire body, the liver and lungs are most often involved. Surgical treatment with the addition of medical therapy remains the gold standard for this disease<sup>9</sup>.

The aim of surgical treatment should be to remove the cyst contents without infecting the thoracic cavity, captonnage the cyst cavity, preserving as much lung tissue as possible and minimizing perioperative complications. In pulmonary hydatid cyst surgery, the two main methods are open thoracotomy and videothoracoscopic thoracic surgery (VATS)<sup>10-12</sup>. In recent years, studies on videothoracoscopic hydatid cyst surgery, which have been applied in small patient groups, have started to be published. Alpay et al reported a series of 77 patients comparing biportal vats with thoracotomy and Akar et al reported that thoracotomy with videothoracoscopy was successfully applied to 39 patients with uniportal vats and thoracotomy<sup>13-16</sup>. The surgical treatment of pulmonary hydatid cyst including all the stages of cyst removal and captonnage is the same for VATS and thoracotomy. When videothoracoscopic surgery was first performed by Paterson and Blyth in 1996, it was recommended only for dead cysts and did not provide any advantage in living and non-perforated cysts<sup>17</sup>. However, as experience in VATS has increased, it has been proven that it can also be performed for non-perforated cysts<sup>13,16</sup>. Videothoracoscopic cyst surgery, using ultrasound when necessary, primarily for peripheral cysts < 6 cm in

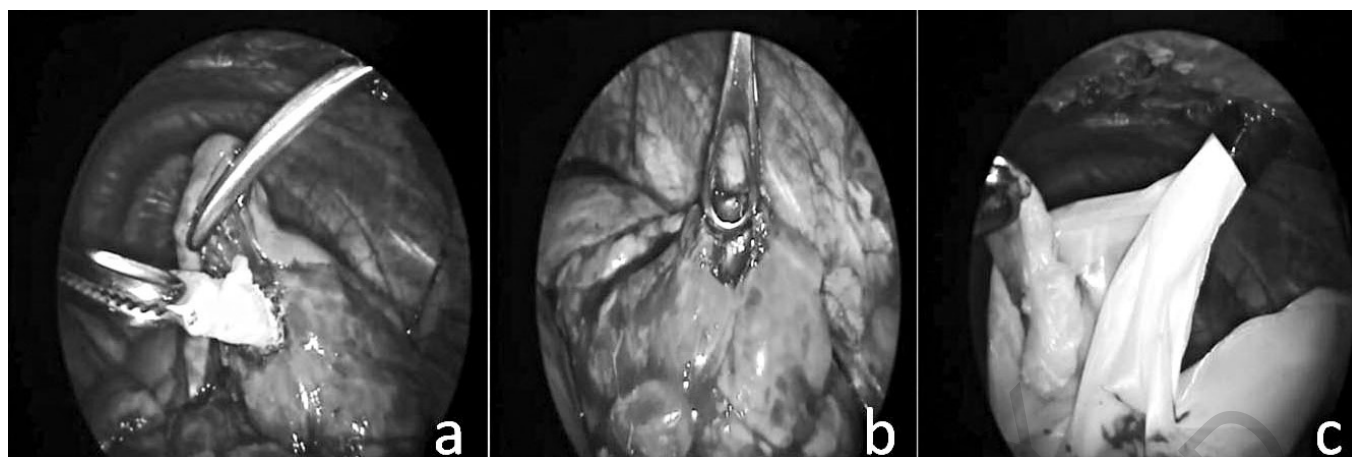


Fig. 5: Peripheral cyst excision with triportal vats.

TABLE III - Pulmonary Hydatid Cyst Characteristics

	TVATS (n=25)	Thoracotomy (n=32)	P value
Diameter( cm)	4(2-10)	7(2-20)	0,001#
Side (n)			
Right	7	17	
Left	16	10	
Bilaterally	2	50,048*	
Peripheral	27 (%87)	25 (%46)	0,080#
Central	4 (%13)	29 (%64)	0,000#
Number of total lung cyst	31	540,016#	
Intact	19 (%61)	28 (%52)	0,821#
Ruptured	12 (%39)	26 (%48)	0,133#

\*Chi-Square, & T-test, #Mann-Whitney U test

size, is a very rational approach<sup>16</sup>. Uniportal VATS can be difficult for the surgeon and requires advanced experience in giant cysts and centrally located cysts. In the current study, the number of central and large cysts was significantly higher in the Thoracotomy group than in the TVATS group.

Although Alpay et al.<sup>13</sup> stated that the size of the cysts was not a contraindication for videothoroscopic surgery, it is clear that capitonnage with VATS is more difficult than for small cysts, especially in giant cysts >10 cm. Capitonnage should be performed first in small cysts where there is less chance of air leakage. As the surgeon's experience increases, it can then be applied in central and large cysts.

One of the advantages of videothoroscopic surgery is that postoperative pain is less than in thoracotomy and the length of hospital stay is shorter<sup>13,16</sup>. In a study by Metha et al, the operating time (minutes) and length of hospital stay (days) were significantly shorter in the VATS group (n= 14) compared to the thoracotomy group (n= 18) (95.21 minutes versus 137.77 minutes and mean, 4.92 versus 13.94 days respectively)<sup>13</sup>. In the current study, these values were compatible with the lit-

erature. However, the difference between the length of stay (days) was not so significant. (91.04 ± 23.40 minutes versus 116.13 ± 19.98 and 5<sup>3-11</sup> days versus 5<sup>(4-12)</sup> p= 0.040) Due to less intercostal pain after VATS, there have been thought to be fewer complications than in thoracotomy, but not of a statistically significant level<sup>13-16</sup>. In the current study, there was no significant difference between the groups in respect of complications, consistent with the literature (p = 0.094).

In a study of 12 patients, Findıkçıoğlu et al. reported wedge resection with TVATS for hydatid cyst and recommended that this method should only be applied in peripheral and small cysts<sup>15</sup>. In the current study, it was also considered that wedge resection with TVATS was not suitable for central and large cysts because it can cause air leakage and pulmonary artery injury and therefore it was not applied to these patients. In principle, it can be considered appropriate to start the operation with VATS in all peripheral and small cysts, and to transfer to open thoracotomy in cases where there are adhesions, and central and giant cysts do not permit capitonnage.

This study has some limitations, primarily the small

number of the population. Other limitations were that the number of central and peripheral cysts between the groups was quite different from each other.

Conclusively, Triportal Videothoroscopic Surgery (TVATS) in the treatment of pulmonary hydatid cyst surgery was seen to be superior to thoracotomy in respect of operation and hospitalization time, and postoperative pain scores. However, it may be necessary turn to thoracotomy especially in central and giant cysts where capitonage cannot be done with TVATS.

## Riassunto

**OBIETTIVO:** Sebbene ci siano un gran numero di serie di casi e risultati positivi nel trattamento chirurgico con toracotomia della cisti idatidea polmonare, la serie di chirurgia toracoscopica video-assistita e i risultati positivi sono limitati. Lo scopo del nostro studio è di confrontare la chirurgia toracoscopica video-assistita (triportal) e la toracotomia e per aiutare a determinare il metodo chirurgico più appropriato nel trattamento dei cisti idatidea polmonare.

**MATERIALE E METODO:** Lo studio ha incluso 57 pazienti che sono stati operati, a causa della cisti idatidea polmonare, attraverso la toracotomia e la chirurgia toracoscopica video-assistita (triportal) tra gennaio 2012 e marzo 2019. I pazienti sono stati divisi in 2 gruppi come Gruppo di Chirurgia Toracoscopica Video-ssistita (triportal) e Gruppo di Toracotomia. Chirurgia toracoscopica video-assistita (triportal) è stata eseguita su 25 pazienti e la toracotomia su 32 pazienti (56%). Tutti i pazienti sono stati valutati mediante radiografia del torace e torotomia calcolata e confrontati statisticamente in termini di età, dolore, durata della degenza in ospedale, tempo di intervento, complicanze, caratteristiche del punteggio ASA. Valori di probabilità inferiori a  $P = 0,05$  sono stati considerati significativi.

**RISULTATI:** Il tempo di operazione e il tempo di dimissione sono stati significativamente più lunghi nel gruppo di toracotomia. Punteggio ASA, punteggi del dolore postoperatorio, numero totale di cisti, dimensioni delle cisti erano significativamente più elevate rispetto al gruppo di chirurgia toracoscopica video-assistita (triportal). Nessuna differenza significativa è stata trovata tra età, sesso e complicanze postoperatorie. Sono state rilevate complicanze in 6 (18%) pazienti nel gruppo della toracotomia e in 2 (8%) pazienti nel gruppo della chirurgia toracoscopica video-assistita. La cisti gigante è stata rilevata in 18 pazienti e la cisti epatica in 13 pazienti. 4 pazienti sono stati sottoposti a lobectomia. Nessuna mortalità o recidiva sono state osservate in entrambi i gruppi.

**CONCLUSIONE:** La chirurgia toracoscopica video-assistita (triportal) è superiore alla toracotomia in termini di tempo di ricovero, punteggio del dolore postoperatorio e cosmeticamente. Mentre l'escissione e la trapuntatura

delle cisti periferiche e inferiori a 10 cm sono più facili con chirurgia toracoscopica video-assistita (triportal), rispetto alle cisti giganti. Questo è molto più difficile per le cisti centrali e giganti. Può causare fistola bronchopleurale quando non eseguita da personale medico esperto. Soprattutto nelle cisti giganti e nelle cisti centrali, è opportuno scegliere la toracotomia fino a quando non si ottiene un'esperienza sufficiente nella chirurgia videotoracoscopica.

## References

1. Eser I, Karabag H, Gunay S, Seker A, Cevik M, Ali ZH, A Sak, Yalcin F, Aydin MS, et al.: *Surgical approach for patients with unusually located hydatid cyst*. Ann Ital Chir, 2014; 85(1):50-5.
2. Oz G, Eroglu M, Gunay E, Bal A, Kacar E, Eser O, et al.: *Aggressive hydatid cysts: Characteristics of six cases*. Surg Today, 2015; 45(7):864-70, doi: 10.1007/s00595-014-1019-9. Epub 2014 Aug 28.
3. Burgos R, Varela A, Castedo E, et al.: *Pulmonary hydatidosis: Surgical treatment and follow-up of 240 cases*. Eur J Cardiothorac Surg, 1999; 16:628-35.
4. Dogan R, Yuksel M, Cetin G, et al.: *Surgical treatment of hydatid cysts of the lung: Report on 1055 patients*. Thorax, 1989; 44:192-99.
5. Cetin G, Dogan R, Yuksel M, et al.: *Surgical treatment of bilateral hydatid disease of the lung via median sternotomy: Experience in 60 consecutive patients*. Thorac Cardiovasc Surg, 1988; 36:114-17.
6. Bagheri R, Haghi SZ, Amini M, Fattahi AS, Noorshafiee S: *Pulmonary hydatid cyst: Analysis of 1024 cases*. Gen Thorac Cardiovasc Surg, 2011; 59:105-09.
7. Organization WH: *Guidelines for treatment of cystic and alveolar echinococcosis in humans. WHO informal working group on echinococcosis*. Bull World Health Organ, 1996; 74:231-42.
8. Abbas N, Zaher Addeen S, Abbas F, Al Saadi T, Hanafi I, Alkhatib M, Turk T, Al Khaddour A: *Video-assisted thoracoscopic surgery (VATS) with mini-thoracotomy for the management of pulmonary hydatid cysts*. J Cardiothorac Surg, 2018; 13(1):35, doi: 10.1186/s13019-018-0716-7.
9. Al-Jawabreh A, Ereqat S, Dumaidi K, et al.: *The clinical burden of human cystic echinococcosis in Palestine, 2010-2015*. Plos Negl Trop Dis 2017; 11:e0005717.
10. Utku R, Yilmaz HG, Onat S, Ozcelik C: *Surgical treatment of pulmonary hydatid cysts: report of 139 cases*. Int Surg, 2006; 91:77-81.
11. Karaoglanoglu N, Kurkcuoglu IC, Gorguner M, Eroglu A, Turkyilmaz A: *Giant hydatid lung cysts*. Eur J Cardiothorac Surg, 2001; 19:914-17.
12. Yalcinkaya I, Er M, Ozbay B, Ugras S: *Surgical treatment of hydatid cyst of the lung: Review of 30 cases*. Eur Respir J, 1999; 13:441-44.
13. Alpay L, Lacin T, Atinkaya C, et al.: *Video-assisted thoracoscopic removal of pulmonary hydatid cysts*. Eur J Cardiothorac Surg, 2012; 42:971-75.

14. Mehta KD, Gundappa R, Contractor R, Sangani V, Pathak A, Chawda P: *Comparative evaluation of thoracoscopy versus thoracotomy in the management of lung hydatid disease.* World J Surg, 2010; 34:1828-31.
15. Findikcioglu A, Karadayi S, Kilic D, Hatiopoglu A: *Video assisted thoracoscopic surgery to treat hydatid disease of the thorax in adults: Is it feasible?* J Laparoendosc Adv Surg Tech A, 2012; 22:882-85.
16. Abu Akar F, Gonzalez-Rivas D, Shaqqura B, Salman W, Ismail M, Safadi T, Adwan R, Al-Hassan H, Rumman N, Hijeh N: *Uniportal video assisted thoracoscopy versus open surgery for pulmonary hydatid disease. A single center experience.* J Thorac Dis, 2020; 12(3):794-802, doi: 10.21037/jtd.2019;12.73.
17. Paterson HS, Blyth DF: *Thoracoscopic evacuation of dead hydatid cyst.* J Thorac Cardiovasc Surg, 1996; 111:1280-281.

READ-ONLY COPY  
PRINTING PROHIBITED