

# The early anti-inflammatory effect of Kefir in experimental corrosive esophagitis



Ann. Ital. Chir., 2013 84: 681-685

Published online 3 October 2012

pii: S0003469X12018672

[www.annitalchir.com](http://www.annitalchir.com)

Mehmet Yasar\*, Ali Kemal Taskin\*, Bulent Kaya\*\*, Metin Aydin\*, Ismet Ozaydin\*, Abdulkadir Iskender\*, Havva Erdem\*, Handan Ankatali\*\*, Hayati Kandis\*\*\*\*

\*Duzce University, Medical Faculty, Department of General Surgery, Duzce, Turkey

\*\*Fatih Sultan Mehmet Training and Research Hospital, Department of General Surgery, Istanbul, Turkey

\*\*\*Duzce University, Medical Faculty, Department of Statistics, Duzce, Turkey

\*\*\*\*Duzce University, Medical Faculty, Department of Emergency Medicine, Duzce, Turkey

## The early anti-inflammatory effects of Kefir in experimental corrosive esophagitis

**AIM:** Corrosive esophageal burns are still an important problem. The aim of this study was to evaluate the effect of kefir in an experimental corrosive esophagitis model.

**MATERIAL AND METHOD:** Twenty-four male wistar albino rats were used in this experimental study. The rats were randomized into three groups according to the procedure and treatment type (each group has eight rats).

Group I: (Control group), Group II: (Induction of corrosive esophagitis with 5 % NaOH without any treatment) and Group III: (Corrosive esophagitis treated with kefir). The rats were sacrificed on the first and seventh days. Mediastinum and abdominal cavity of rats were explored. Approximately 1.5 cm of esophagus was removed for histopathological examination. Inflammation, injury in the muscularis mucosa and collagen deposition were evaluated.

**RESULTS:** Histopathological results on the first day after caustic injury; inflammation was detected in three rats in Group II and there were no inflammation in rats in Group III. This difference was statistically significant ( $p < 0.05$ ). Injury in muscularis mucosa was detected in three rats in Group II and in one rat in Group III. Histopathological results on the seventh days after caustic injury; Inflammation was positive in four rats in Group II and three rats in Group III. Injury in muscularis mucosa was equal in two groups (three rats each). Collagen deposition with high grade (Grade 2) was detected in two rats in Group II and in four rats in Group III ( $p < 0.05$ ).

**CONCLUSION:** Kefir has anti-inflammatory effect specially in early phase of caustic injury. It has also some beneficial effect in wound healing.

**KEY WORDS:** Caustic injury, Corrosive esophagitis, Kefir.

## Introduction

Corrosive esophageal injury is an important problem specially in the pediatric age group.

Approximately 90 % of these injuries are caused by alkaline substances such as potassium and sodium hydroxi-

de<sup>1,2</sup>. Ingestion of caustic agents can cause a wide range of injuries changing from mild esophagitis to fatal hollow viscus perforation. Alkaline substances are usually associated with liquefaction necrosis in esophageal mucosa. If they penetrate deep into the muscular layers, serious injury is inevitable.

Kefir is a fermented milk similar to yogurt but containing different fermentation microbes. Kefir grains constitute both lactose-fermenting yeasts (*Kluyveromyces marxianus*) and non-lactose-fermenting yeasts (*Saccharomyces unisporus*, *Saccharomyces cerevisiae*, and *Saccharomyces exiguus*). The word 'kefir' comes from the turkish word 'keif' which can loosely be translated as "feeling good". The beneficial effects of kefir has been known since eigh-

Pervenuto in Redazione Marzo 2012. Accettato per la pubblicazione Giugno 2012

Correspondence to: Dr Bulent Kaya, Fatih Sultan Mehmet Training and Research Hospital, Department of General Surgery/Istanbul-Turkey (e-mail: drbkaya@yahoo.com)

teenth century. Many studies have demonstrated that kefir has antibacterial, antifungal and immunomodulator properties<sup>3-5</sup>. Although several chemical substances and drugs have been used in the treatment of corrosive esophagitis, kefir has not been used for this purpose until now. We evaluated the effects of kefir in corrosive esophagitis in this experimental study.

## Material and Method

Twenty-four male wistar albino rats (body weights 250-300 g, average age 6 months) were used in this experimental study. The study was approved by the local ethical committee at Duzce University, Medical School. Surgical procedures were performed with premedication by 75 mgr/kg ketamine hydrochloride given intraperitoneally and anesthesia was induced by ketamine 25 mgr/kg and xylazine 3 mg/kg. After cleaning the incision site with iodine solution, a median laparotomy was performed in all groups. The distal esophagus was explored. Approximately 1.5 cm esophageal segment was isolated and tied from upper and lower parts with 3-0 silk sutures (Fig. 1). The consistent agent for each group (0.9 % saline, 5 % NaOH and kefir solution) instilled into the esophageal cavity via 24 F cannula. The experimental rats were randomized into three groups (each group having eight rats) according to the procedure and treatment type:

**GROUP I** (The control group): One ml of 0.9% saline was instilled with 24 F intravenous cannula into the esophageal cavity.

**GROUP II** (The corrosive esophagitis group without treatment): One ml of 5% NaOH solution was instilled through the isolated esophagus with 24 F intravenous cannula for 3 minutes. After this procedure, the esophageal cavity was cleaned with distilled water for 1 minute.

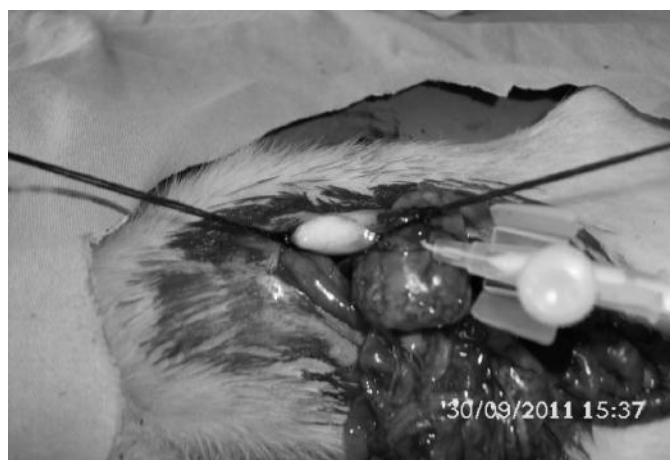

Fig. 1: Exploration of esophagus and installation of lumen with 24 F cannula.

**GROUP III** (The corrosive esophagitis group treated with kefir): After induction of corrosive esophagitis and cleaning with 1 ml distilled water, 1 ml of kefir solution was instilled into the distal esophagus for 3 minutes and kefir was also cleaned with distilled water. The rats were allowed to recover from the anesthetic and fed by food and water following surgery.

The rats were sacrificed on the first and seventh days. Mediastinum and abdominal cavity of rats were explored. Approximately 1.5 cm of esophagus was removed for histopathological examination. Resected tissue was fixed in 10 % paraformaldehyde in 0.1 mol/L phosphate-buffered saline and embedded in paraffin. Paraffin sections (4 µm) were stained with hematoxylin-eosin (H&E) and examined with light microscope. In each specimen, inflammation, injury in muscularis mucosa, collagen deposition in tunica muscularis were investigated. Collagen deposition in tunica muscularis was graded as none (0), mild (1) and marked (2). Mild collagen deposition was defined as submucosal collagen at least twice the thickness of the muscularis mucosa. Marked collagen deposition was defined as submucosal collagen more than twice the thickness of the muscularis mucosa. SPSS for Microsoft Windows (Version 18.0) was used for statistical analysis. Mann-Whitney U or chi-square tests were used to define the statistical differences between the histopathological parameters.

## Results

The results of histopathological examination in rats that were sacrificed on the first day after caustic injury ; There was no inflammation in rats in Group I. When compared to Group II, the difference was significant ( $p<0.05$ ) (Table I). Inflammation was detected in three rats in Group II and there were no inflammation in rats in Group III. This difference was statistically significant ( $p<0.05$ ). Injury in muscularis mucosa was detected in three rats in Group II and in one rat in Group III. All results are shown in (Table II).

TABLE I - Histopathological results of Group I and Group II on the first day after caustic injury

Histopathological finding	Group I	Group II	p value
Inflammation	0/+ 4/-	3/+ 1/-	<0.05**
Injury in muscularis mucosa	0/+ 4/-	3/+ 1/-	<0.05**
Collagen deposition in tunica muscularis			
Grade 0	4/+	1/+	>0.05
Grade 1		2/+	
Grade 2		1/+	

\* Statistically significant  $p<0.05$

TABLE II - Histopathological results of Group II and Group III on the first day after caustic injury

Histopathological finding	Group II	Group III	p value
Inflammation	3/+ 1/-	0/+ 4/-	<0.05**
Injury in muscularis mucosa	3/+ 1/-	1/+ 3/-	>0.05
Collagen deposition in tunica muscularis			
Grade 0	1/+	2/+	>0.05
Grade 1	2/+	2/+	
Grade 2	1/+	0/+	

TABLE III - Histopathological results of Group II and Group III on the seventh days after caustic injury

Histopathological finding	Group II	Group III	p value
Inflammation	4/+ 0/-	3/+ 1/-	>0.05
Injury in muscularis mucosa	3/+ 1/-	3/+ 1/-	>0.05
Collagen deposition in tunica muscularis			
Grade 0	2/+	0/-	<0.05**
Grade 1	0/-	0/-	
Grade 2	2/+	4/+	

TABLE IV - Comparison of histopathological results in Group II and Group III on the first and seventh days after caustic injury

	Inflammation	IMM	CTM
<b>Group II</b>			
First day	3/+	3/+	1/+
Seventh days	4/+	3/+	2/+
P value	0.2	1.0	0.1
<b>Group III</b>			
First day	0/+	1/+	0
Seventh days	3/+	3/+	4/+
P value	<0.05**	>0.05	<0.05**

\*IMM: Injury in muscularis mucosa

\*CTM:Collagen deposition in tunica muscularis

The results of histopathological examination in rats that were sacrificed on the seventh days after caustic injury; Inflammation was positive in four rats in Group II and in three rats in Group III. Injury in muscularis mucosa was equal in two groups (three rats each). High grade collagen deposition was detected in two rats in Group II and in four rats in Group III ( $p < 0.05$ ). Results are shown in Table III.

Comparison of the first and seventh days results in Group II are shown in (Table IV). There were no sta-

tistically significant differences for histopathological results.

On the other hand, inflammation and collagen deposition in tunica medialis were parameters that were statistically different in Group III between the first and seventh days (Table IV).

The histopathological examinations in light microscope are shown in (Figs. 2, 3, 4).

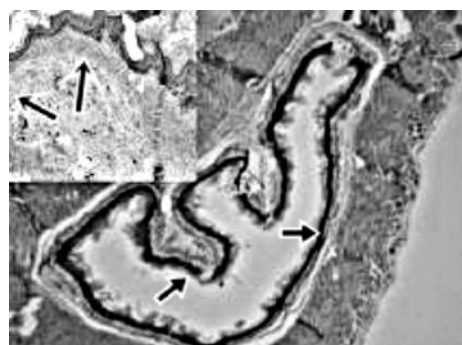

Fig. 2: Comparison of Group I (large picture) and Group II (small picture). Normal esophageal mucosa (large picture-arrows) and polymorphonuclear infiltration and collagen deposition (small picture-arrows) (H&E 100X).

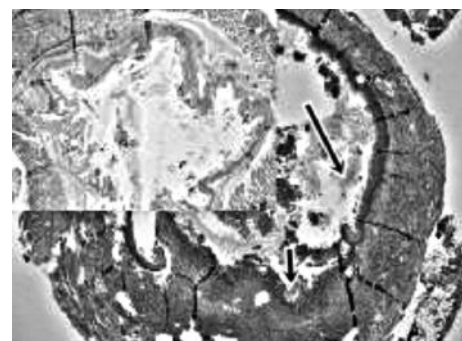


Fig. 3: (Corrosive esophagitis-Group II). Small picture shows the severe inflammation on the 1.day with polymorphonuclear infiltration, large picture shows more severe inflammation with ulcers (arrows) on the 7 days H&E, 40X.

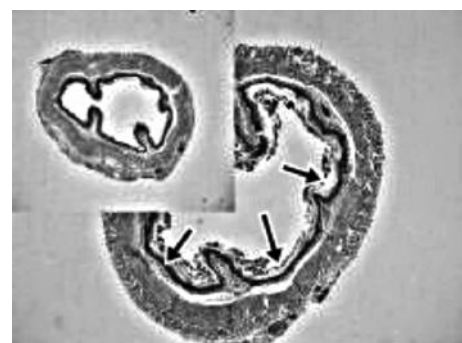


Fig. 4: (Corrosive esophagitis and kefir treatment-Group III) Small and large pictures show the minimal inflammatory changes on the 1. and 7. days in treated rats. (H&E 100X).

## Discussion

Caustic injury to the gastrointestinal tract is an important public health problem specially in the developing countries. The early results are mucosal burns, perforation and even mortality. Long term complications may also be observed such as stricture formation and development of esophageal carcinoma <sup>6</sup>. Caustic agents have great capacity to damage mucosal surfaces. Minor damage after caustic injury is characterized by simple erythema and edema on mucosal surface. However, deep tissue necrosis with catastrophic perforation in a hollow viscus may cause mortality.

Probiotics are defined as live microbial food supplements that when ingested can survive gastrointestinal tract and exert positive influence on host health. The mode of action of probiotics is complex and not yet fully elucidated. Many mechanisms have been suggested to explain probiotic actions such as antagonism against intestinal pathogens, enhancement of mucosal barrier activity, or modulation of host's immune functions <sup>7-9</sup>. Oliveira M et al <sup>10</sup> showed the beneficial effect of *Lactobacillus paracasei* to reduce the intestinal inflammation in experimental colitis model. They also stated that probiotics can be used as a supportive agent in the treatment of inflammatory bowel disease. In a clinical study, thirty patients with ulcerative colitis were treated with either sulphasalazine or probiotic. It was demonstrated that probiotics decreased the accumulation of white blood cells and production of IL-6 and TNF alfa, thus diminishing the severity of colitis <sup>11</sup>. It was reported that *S. Boulardii*, as a probiotic, decreases the production of pro-inflammatory cytokines by inhibiting main regulators of inflammation, including nuclear factor  $\kappa$ B (NF- $\kappa$ B), mitogen-activated protein kinases (MAP kinases), ERK1/2 and p38. It also suppresses bacterial infection by inhibiting adhesion and/or overgrowth of bacteria <sup>12</sup>. Several agents have been used in the treatment of caustic injury <sup>13-16</sup>. Somuncu S et al used the Tradipil which is an inhibitor for phosphodiesterase and platelet-derived-growth factor for caustic burns in rats <sup>17</sup>. They emphasise the importance of free oxygen radicals in early phase of caustic injury. The Tradipil decreased the malondialdehyde and nitric oxide levels in rats and improved the healing of mucosal ulcers. It was also reported that kefir has significant anti-oxidant activity in *Salmonella* species <sup>18</sup>.

In this study, kefir has demonstrated an anti-inflammatory effect in early phase of caustic injury. Inflammation level was significantly lower in treatment group in first day ( $p < 0.05$ ). Kefir also decreased the inflammation level in long term (seventh days) but the difference was not statistically significant. It was reported that, kefir can inhibit the total inflammatory cell count after intra-gastric administration <sup>19</sup>. Kefir has cumulative effect for both inhibiting activity of inflammatory cells and free oxygen radicals. While the acute inflammation is the first

event in wound healing process it is coherent with results of this study that kefir can be more effective in early phase of caustic injury. Kefir has also well known wound healing properties. Moreira ME showed the cicatrizing activity of kefir in rats <sup>20</sup>. Collagen deposition was significantly higher in rats treated with kefir in our study. This was especially true for the seventh days after caustic injury. Halper J et al demonstrated the wound healing and angiogenic effects of *Lactobacillus* extract which was injected subcutaneously to the rats <sup>21</sup>. The injection of *Lactobacillus* extract was associated with new blood vessel formation. The wound healing effect of *Lactobacillus* extract was detected with long term inflammatory cell progression to the wound site and very properly formed young connective tissue. It may be argued that high collagen deposition can be associated with stricture formation. In this study, the newly formed collagen was structurally normal. Moreover, it is impossible to presume the stricture development in seventh days of wound healing process.

**In conclusion:** our data suggest that Kefir has anti-inflammatory effect specially in early phase of caustic injury. It can demonstrate this effect probably by inhibiting inflammatory cell count and decreasing free oxygen radicals. It also increases the collagen deposition. Further studies can be performed for time related effects of kefir specially in terms of antiinflammation and collagen deposition.

## Riassunto

Le causticazioni esofagee da agenti corrosivi costituiscono tutt'ora un problema importante. Lo scopo di questo studio è quello di valutare l'effetto del Kefir su un modello sperimentale di causticazione esofagea.

Per lo studio sono stati impiegati 24 ratti albini wistar, randomizzati in tre gruppi secondo il tipo di trattamento e relative procedure, ciascun gruppo costituito da 8 ratti.

I gruppo di controllo. II gruppo: induzione di esofagite corrosiva con NaOH al 5% senza alcun trattamento. III gruppo: esofagite corrosiva trattata con Kefir.

I ratti sono stati sacrificati al primo ed al settimo giorno, esplorando mediastino e cavità addominale. È stato asportato circa 1,5 cm dell'esofago per esame istopatologico, valutando flogosi, danneggiamento della muscolaris mucosa e depositi di collagene.

Come risultato al primo giorno dopo la noxa corrosiva si è rilevata flogosi in 3 ratti del II gruppo, assente in tutti i ratti del III gruppo. Tale differenza è statisticamente significativa ( $p < 0.05$ ). Danni della muscolaris mucosa erano evidenti in 3 ratti del II gruppo ed in 1 ratto del III gruppo.

Risultati istopatologici al settimo giorno dopo la noxa caustica: infiammazione in 4 ratti del II gruppo e 3 ratti del III gruppo; lesioni della muscolaris mucosa sovrapponibili nei due gruppi, con 3 ratti ciascuno; depo-



siti di collagene di grado elevato (grado 2) in 2 ratti del II gruppo ed in 4 ratti del III gruppo ( $p < 0.05$ ). In conclusione il Jefir dimostra un effetto antinfiammatorio specialmente nella fase precoce del danno corrosivo. Inoltre presenta qualche efficacia positiva nella guarigione delle lesioni.

## References

1. Janousek P, Kabelka Z, Rygl M, Lesný P, Grabec P, Fajstavr J, Jurovcík M, Snajdauf J: *Corrosive injury of the oesophagus in children*. Int J Pediatr Otorhinolaryngol, 2006; 70:1103-107.
2. Ozel SK, Dagli TE, Yuksel M, Kiyan G, Kotiloglu E: *The roles of free oxygen radicals, nitric oxide, and endothelin in caustic injury of rat esophagus*. J Pediatr Surg, 2004; 39:1381-385.
3. Rodrigues KL, Caputo LR, Carvalho JC, Evangelista J, Schneedorf JM: *Antimicrobial and healing activity of kefir and kefir extract*. Int J Antimicrob Agents, 2005; 25:404-08.
4. Bakken JS: *Resolution of recurrent Clostridium difficile-associated diarrhea using staggered antibiotic withdrawal and kefir*. Minn Med, 2009; 92:38-40.
5. Vinderola CG, Duarte J, Thangavel D, Perdigon G, Farnworth E, Matar C: *Immunomodulating capacity of kefir*. J Dairy Res, 2005; 72:195-202.
6. Lupa M, Magne J, Guarisco JL, Amedee R: *Update on the diagnosis and treatment of caustic ingestion*. Ochsner J, 2009; 9:54-59.
7. Gareau MG, Sherman PM, Walker WA: *Probiotics and the gut microbiota in intestinal health and disease*. Nature Reviews Gastroenterology and Hepatology, 2010; 7:503-14.
8. Rakoff-Nahoum S, Medzhitov R: *Role of the innate immune system and host-commensal mutualism*. Curr Top Microbiol Immunol, 2006; 308:1-18.
9. Madsen K: *Probiotics and the immune response*. J Clin Gastroenterol, 2006; 40:232-34.
10. Oliveira M, Bosco N, Perruisseau G, Nicolas J, Segura-Roggero I, Duboux S, Briand M, Blum S, Benyacoub J: *Lactobacillus paracasei reduces intestinal inflammation in adoptive transfer mouse model of experimental colitis*. Clin Dev Immunol, 2011; 2011:807483.
11. Hegazy SK, El-Bedewy MM: *Effect of probiotics on pro-inflammatory cytokines and NF-kappaB activation in ulcerative colitis*. World J Gastroenterol, 2010 7; 16:4145-151.
12. Im E, Pothoulakis C: *Recent advances in Saccharomyces boulardii research*. Gastroenterol Clin Biol, 2010; 34:S62-70.
13. Bautista A, Varela R, Villanueva A, Estevez E, Tojo R, Cadranet S: *Effects of prednisolone and dexamethasone in children with alkali burns of the oesophagus*. Eur J Pediatr Surg, 1996; 6:198-203.
14. Çakmak M, Natch A, Renda N, et al.: *The effect of corticosteroids and pentoxifylline in caustic esophageal burns*. Int Surg, 1997; 82:371-75.
15. Duman L, Büyükyavuz BI, Altuntas I, Gökcimen A, Ceyhan L, Darici H, Aylak F, Tomruk O: *The efficacy of single-dose 5-fluorouracil therapy in experimental caustic esophageal burn*. J Pediatr Surg, 2011; 46:1893-897.
16. Akbal E, Köklü S, Karaca G, Astarci HM, Koçak E, Ta A, Beyazıt Y, Topcu G, Haznedaroğlu IC: *Beneficial effects of Ankaferd Blood Stopper on caustic esophageal injuries: an experimental model*. Dis Esophagus, 2011 doi:10.1111/j.1442-2050.2011.01231.
17. Somuncu S, Cakmak M, Erdogan S, Caglayan O, Akman H, Kaya M: *Trapidil, an inhibitor for phosphodiesterase and platelet-derived-growth factor, ameliorates corrosive esophageal burn in rats*. Tohoku J Exp Med, 2005; 207:203-08.
18. Liu JR, Chen MJ, Lin CW: *Antimutagenic and antioxidant properties of milk-kefir and soymilk-kefir*. J Agric Food Chem, 2005 6; 53:2467-474.
19. Lee MY, Ahn KS, Kwon OK, Kim MJ, Kim MK, Lee IY, Oh SR, Lee HK: *Anti-inflammatory and anti-allergic effects of kefir in a mouse asthma model*. Immunobiology, 2007; 212:647-54.
20. Moreira ME, Dos Santos MH, Zolini GP, Wouters AT, Carvalho JC, Schneedorf JM: *Anti-inflammatory and cicatrizing activities of a carbohydrate fraction isolated from sugary kefir*. J Med Food. 2008; 11:356-61.
21. Halper J, Leshin LS, Lewis SJ, Li WI: *Wound healing and angiogenic properties of supernatants from Lactobacillus cultures*. Exp Biol Med, 2003; 228:1329-337.

