

An unusual symptomatic case of mediastinal myelolipoma treated by VATS approach



Ann. Ital. Chir., 2014 85: 85-87
pii: S0003469X14022040

Marcello Migliore*, Damiano Calvo*, Alessandra Criscione*, Rosario Caltabiano**, Nunzio Platania***, Giuseppe Barbagallo***, Vincenzo Albanese***

University of Catania, Catania Italy

*Department of Surgery, Section of Thoracic Surgery

**Department GF Ingrassia, Section of Anatomic Pathology

***Department GF Ingrassia, Section of Neurosurgery

An unusual symptomatic case of mediastinal myelolipoma treated by VATS approach.

Symptomatic mediastinal location of an extra-adrenal myelolipoma is extremely rare. We describe a 56-year-old female with unusual pain in the right lower posterior chest radiated to the neck and to the upper abdomen. Chest CT showed a lesion of 3.5 x 2.2 cm in the posterior mediastinum. Video-assisted resection was performed and the final pathologic examination revealed the presence of a myelolipoma. Herein we discuss the clinical presentation, the differential diagnosis and treatment of mediastinal myelolipoma.

KEY WORDS: Mediastinum, Minimally invasive surgery, Myelolipoma, Thoracoscopy, Tumor, VATS

A 56-year old obese female (BMI 44Kg/m²) was admitted to the hospital for severe pain in the right lower posterior chest radiated to the neck and anteriorly to the upper abdomen. Past medical history included surgery for thymoma and myasthenia gravis and cerebral meningioma. Thoracic physical examination and blood laboratory tests were normal. A chest-computed-tomography (CT) revealed a smooth, well-defined, right-sided paravertebral lesion, and the magnetic resonance (MR) of the dorsal and lumbosacral spine confirmed the lesion measuring 3.5x2.2 cm. in the Th8-Th9 intersomatic space well demarcated from the aorta. The lesion was

adherent to the vertebral soma and to the origin of the 8th rib (Fig. 1). Chest tomography of the brain and abdomen was normal. A fine needle aspiration biopsy (FNAB) was not attempted, and surgical resection of the tumor was planned because the presence of symptoms. The operation was performed using a three ports VATS technique. The lesion was found to be tightly adherent to the vertebral soma. During the dissection some bleeding was detected, and following numerous attempts the definitive source of bleeding was not found, we decided to enlarge the posterior port from 2 to 6 cm. The blood was found coming from the vertebral soma and was treated with 5 min. manual compression and haemostatic sponges. The roundish and soft lesion was then removed. Histopathologic examination showed erythropoietic bone marrow mixed with mature adipose tissue, fibrovascular and connective tissue as shown in Fig. 2. The final diagnosis of mediastinal myelolipoma was made. The follow-up included a physical examination, laboratory investigations and spinal-dorsal MR. No signs of recurrence or chest pain were found at the 11 month follow-up.

Pervenuto in Redazione Luglio 2013. Accettato per la pubblicazione Settembre 2013.

Correspondence to: Marcello Migliore, MD, PhD, Department of Surgery, Sect. Thoracic Surgery, University of Catania, Ospedale Policlinico, Via Passo Gravina 63, 95123 Catania, Italy (e-mail: mmiglior@hotmail.com)

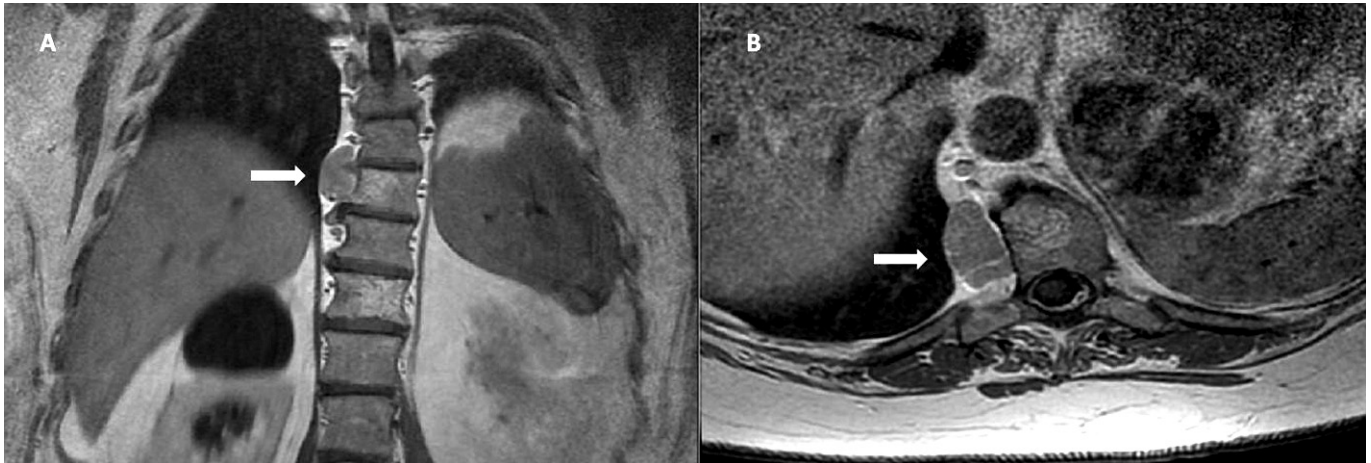


Fig. 1: Magnetic resonance images. A right-sided well defined paravertebral lesion is shown. A) sagittal view; B) cross-sectional view.

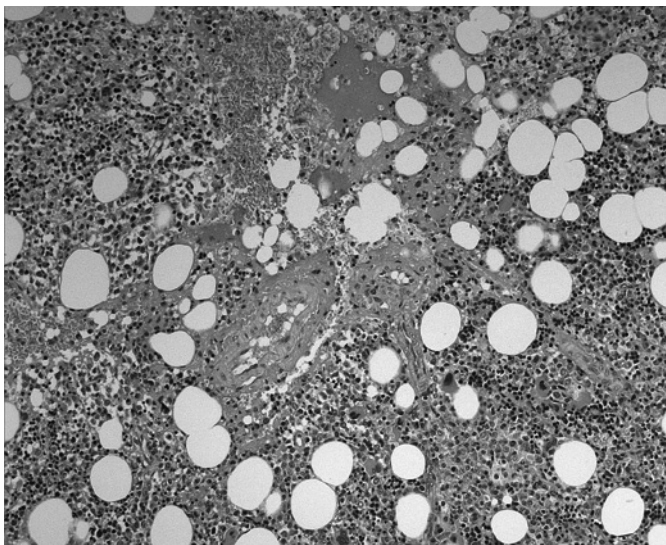


Fig. 2: Histologic examination of the lesion. Hematopoietic bone marrow mixed of mature adipose tissue, fibrovascular and connective tissue (Hematoxylin and Eosin stain, x 400 original magnification).

Discussion

Myelolipoma is a benign, rare, and usually solitary and asymptomatic tumor of the adrenal gland with a slight predominance in the female population ¹. Myelolipomas occur extra-adrenally in 15% of cases, and are commonly found in the presacral or other retroperitoneal regions ². Extra-adrenal myelolipomas have been reported in the liver, stomach, mesentery, spleen, retroperitoneum, presacral area, and leptomeninges. In a few cases myelolipomas have been reported in the chest, and only 3% affect the posterior mediastinum ^{3,4}. Although several hypothesis have been reported, the etiology of myelolipoma remains

unclear. The presence of obesity has already been reported and associated with myelolipomas ⁴. Most myelolipomas are asymptomatic and detected incidentally at necropsies or imaging evaluation for other conditions. There is only one case report of MM and chest pain ⁵. The most interesting finding of our patient was that the unusual distribution of pain considering the anatomic site of the lesion because it irradiated posteriorly to the neck and anteriorly to the upper abdomen. The pain disappeared after the surgical removal of MM. Preoperative diagnostic evaluation included thoracic and abdominal CT-scan, dorsal and lumbosacral MR. CT-guided biopsy and fine needle aspiration biopsy can be useful for the diagnosis of MM in asymptomatic patients. In our patient we omitted this procedure because the patient was symptomatic, and consequently surgery was necessary. Differential diagnosis of MM includes teratoma, neurofibroma, schwannoma, malignant nonseminomatous germ cell tumors, thymolipoma, angiolipoma, epidural lipomatosis. Extramedullary haematopoietic tumors pose the most difficult differential diagnosis. These tumors are multiple, and characterised by the presence of anaemia, hepatosplenomegaly, the predominance of haematopoietic elements and marked bone marrow hyperplasia. Coagulation and fibrinolytic parameters must be carefully checked before needle biopsy or operation ⁶. Computed tomography guided needle aspiration biopsy is useful in establishing the diagnosis avoiding the need for surgical resection in asymptomatic cases. In the situation we describe, however, the fact that the lesion was causing pain and compressing the adjacent mediastinal structures made surgical removal necessary. There is no gold-standard therapeutic approach for myelolipoma, and a multidisciplinary approach is advocated ⁷. Minimally invasive techniques for operation in the mediastinum are nowadays commonly used, and also in our unit ⁸⁻¹⁰. Some authors suggest that surgery could be avoided in asymptomatic patients with benign radiolog-

ical signs. Further suggestions are that such tumors should be removed only when they grow to more than 10 cm. while other authors propose surgical resection even in cases with asymptomatic lesions because the risk of spontaneous rupture in larger myelolipomas ¹¹. The prognosis for myelolipoma is excellent.

The message learnt with this case report is that in symptomatic patients with MM surgical removal is recommended and essential to treat the symptom, and to confirm the histopathology.

Riassunto

La localizzazione mediastinica di un mielolipoma è molto rara. Riportiamo il caso clinico di una donna di 56 anni con dolore inusuale nel torace destro irradiato al collo ed all'addome superiore. La TAC ha mostrato una lesione di 3,5 x 2,2 cm nel mediastino posteriore. L'asportazione è stata effettuata mediante VATS e la diagnosi patologica finale è stata di mielolipoma. Discutiamo la presentazione clinica, la diagnosi differenziale ed il trattamento del mielolipoma mediastinico.

References

1. Cristofaro MG, Lazzaro F, Fava MG, Aversa C, Musella M: *Mielolipoma gigante del surrene: case report e review of the literature*. Ann Ital Chir, 2004; 75(6):677-82.
2. Franiel T, Fleischer B, Raab BW, Füzesi L: *Bilateral thoracic extraadrenal myelolipoma*. Eur J Cardiothorac Surg, 2004; 26: 1220-22.
3. Sagan D, Zdunek M, Korobowicz E: *Primary myelolipoma of the chest wall*. Ann Thorac Surg, 2009; 88:e39-41.
4. Vaziri M, Sadeghipour A, Pazooki A, Shoolami LZ: *Primary mediastinal myelolipoma*. Ann Thorac Surg, 2008; 85:1805-06.
5. Mohan K, Gosney JR, Holemans JA: *Symptomatic mediastinal myelolipoma*. Respiration, 2006; 73(4):552.
6. Vecchio R, Cacciola E, Martino M, Cacciola RR, MacFadyen BV: *Modifications of coagulation and fibrinolytic parameters in laparoscopic cholecystectomy*. Surg Endosc, 2003; 17(3):428-33.
7. Migliore M, Vecchio I, Rampello L, Borrata f, Astuto M, Rampello L: *Multidisciplinary approach of non-thymomatous myasthenia gravis*. Acta Medica Mediterranea, 2012; 28(3):211-13.
8. Migliore M, Pulvirenti G, Okatyeva V, Cannizzaro MA: *Persistent hyperparathyroidism owing to a giant parathyroid adenoma in posterior mediastinum*. Surgery, 2013; 154(1):132-33.
9. Migliore M, Alongi G, Rampello L, Astuto M: *Video assisted trans-cervical thymectomy A minimally invasive approach to treat non-thymomatous myasthenia gravis*. Ann Ital Chir, 2012; 83. doi:pii: S0003469X12000000.
10. Migliore M, Criscione A, Calvo D, Routledge T: *Minimal access anterior mediastinotomy*. Updates Surg, 2013; 65(1):59-61.
11. Schittenhelm J, Jacob SN, Rutczynska J, Tsiflikas I, Meyermann R, Beschorn R: *Extraadrenal paravertebral myelolipoma mimicking a thoracic schwannoma*. BMJ Case Rep. 2009 March. DOI: 10.1136/bcr.07.2008.0561.