

Malignant thymoma invading pulmonary artery. Changing treatment options



Ann. Ital. Chir., LXXIII, 2, 2002

D. Weissberg*, A.J. Cohen*, H. Hayat**,
A. Schachner*

Departments of *Thoracic Surgery and **Oncology,
Tel Aviv University Sackler School of Medicine, Tel Aviv,
and E. Wolfson Medical Center, Holon, Israel

Thymoma is a tumor arising from thymic epithelium, although its microscopic appearance is one of a mixture of lymphocytes and epithelial cells (1). Thymomas are classified into lymphocytic, epithelial, mixed and spindle cell types (2).

It is generally agreed that microscopic examination of the neoplasm does not suffice for determination of malignancy.

The surgeon is usually in a better position to assess the invasive nature of thymoma from the findings at thoracotomy than the pathologist who examines the specimen after resection (3).

Malignancy of thymoma is thus determined by its invasion beyond the capsule of the tumor. This distinction does not apply to thymic carcinoma, in which determination of malignancy is based on microscopic features (4).

The only curative treatment of thymoma is resection; however, this may be precluded by invasion of vital organs, thus restricting treatment to radiotherapy.

The role of chemotherapy is controversial; it may be used in combination with resection and irradiation (5, 6).

Two patients with malignant thymoma; one invading the pericardium, the left lung and the left pulmonary artery; the other, the pericardium, the left lung, the left pulmonary artery and the left innominate vein, were treated by resection.

Abstract

Background: Curative treatment of malignant thymoma is resection; however, this may be precluded by invasion of vital organs.

Patients and methods: Two patients with extensive intrathoracic spread of thymoma (Stages III and IV A) are presented. Treatment involved a combination of resection, radiotherapy and chemotherapy.

Results: One patient survived 9 years, 4 months, but eventually died of metastatic spread; the other one is well and without evidence of disease 30 months after treatment.

Conclusions: Thymoma is a slow-growing tumor. Successful surgical treatment in advanced cases is possible, if aided by radiotherapy and chemotherapy. The adjuvant therapy converts a non-resectable tumor to a resectable one.

Key words: Thymoma, malignant thymoma, advanced thymoma.

Riassunto

*TIMOMA MALIGNO CON INVASIONE DELL'ARTE-
RIA POLMONARE; CAMBIAMENTI NELLE OPZIO-
NI TERAPEUTICHE*

La resezione è il trattamento terapeutico del timoma maligno, sebbene potrebbe essere preclusa con l'invasione degli organi vitali. Il lavoro presenta due casi clinici di timoma con invasione di strutture vascolari mediastiniche (stadio III e IV A) trattati con terapia multinodale combinata: resezione, radioterapia e chemioterapia.

Un paziente è vissuto 9 anni e 4 mesi ed è morto per metastasi; l'altro sta bene e non presenta recidiva della malattia 30 mesi dopo il trattamento.

Il timoma è una neoplasia a crescita lenta; il trattamento chirurgico con esito favorevole è possibile nei casi più avanzati se combinato con la radioterapia e la chemioterapia.

L'utilizzo della terapia adiuvante trasforma il tumore non aggreddibile chirurgicamente in tumore operabile.

Patient n. 1

A 40-year-old female, mother of three, was seen in February 1979 because of chest pain lasting several months and increasing with cough. Chest roentgenogram

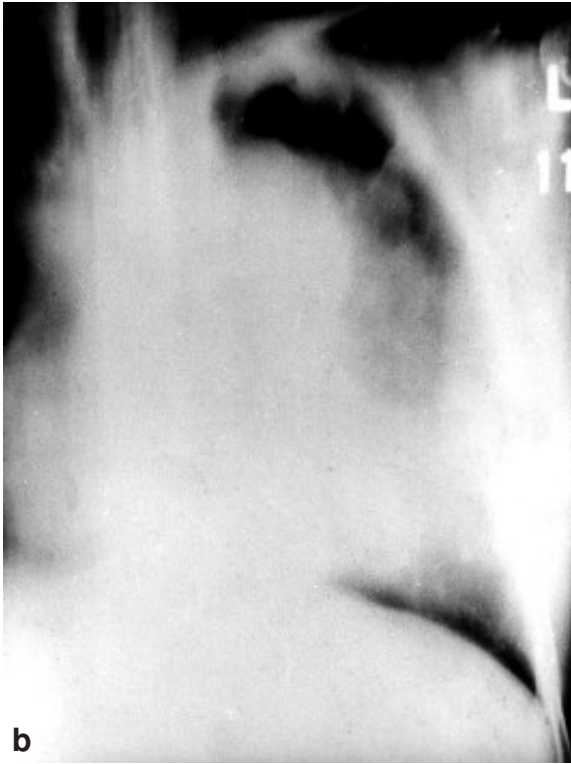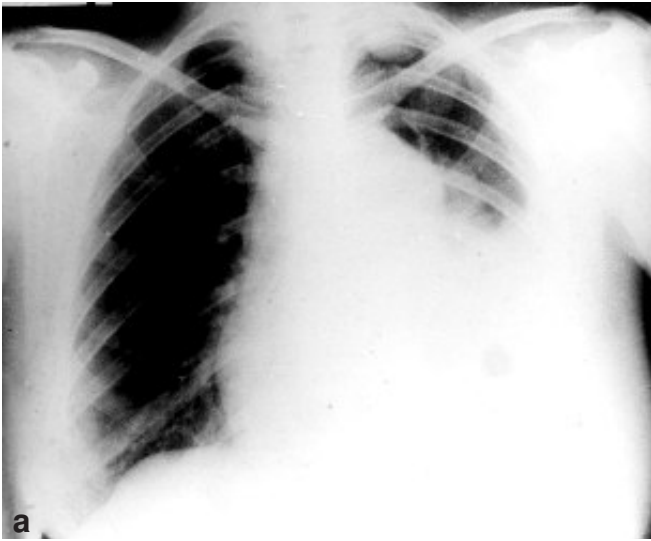


Fig. 1: Patient 1. a), chest roentgenogram. b) linear tomography. Note multiple pleural masses.

showed abnormally wide mediastinum and multiple masses in the left pleura (Fig. 1, a and b).

The diagnostic workup included pleuroscopy and biopsy of a pleural mass, which showed metastases of lymphocytic thymoma. Exploration of the chest (February 20th 1979) carried out through a midsternotomy, disclosed a 13x11x8 cm anterior mediastinal mass based in the thymus, with extensive invasion of the pericardium, the left lung and the left main pulmonary artery. Multiple masses ranging in size from 1 cm to 5 cm were scattered over the parietal pleura on the left side. Resection of the entire mass, including the left lung and the pericardium was performed. All visible pleural metastases were also resected. The resection of all malignant tissue was macroscopically complete. The resection was followed by a course of chemotherapy, which included cytophosphan, oncovine and prednisone, and cobalt radiotherapy of 3000 cGy. This treatment was completed 60 days after the resection (April 19th 1979). The patient remained well until May 1984, when a local recurrence was noted, as well as a retroperitoneal metastatic mass. Treatment with chemotherapy was ineffective, and she again received a course of radiotherapy with symptomatic improvement. A new mass was then noted in the base of the right lung and the left pleura. This was attended with another course of chemotherapy, followed by disappearance of all masses. The patient remained apparently free of tumor through 1985. In March 1986, a 5 cm mass was noted in the right breast, attached to the chest wall. Biopsy confirmed metastasis of thymoma. During the following two years, the patient was given several courses of chemotherapy, until her death from widespread metastases in June 1988.

Patient n. 2

An 18-year-old male was hospitalized in November 1997 because of four months of pain in the chest and left shoulder, six weeks of hoarseness and cough, and three weeks of weakness and anorexia. Except for general weakness and fever of 38°C, physical examination did not disclose abnormal findings. Chest radiograph and computerized tomography showed a large anterior mediastinal mass (Fig. 2). Biopsy of the mass disclosed thymoma, predominantly mixed type. On exploration of the mediastinum through median sternotomy (January 8th 1998), a large thymoma was found, invading the pericardium, both phrenic nerves, the left lung, the left pulmonary artery and the left innominate vein. It was adherent to the descending aorta. Resection was impossible, and the tumor was biopsied, with histologic diagnosis of malignant thymoma. After the operation the patient received four courses of Cisplatin, Adriamycin and Cytophosphan. This was followed by a marked regression of the mass (Fig. 3). On second exploration of the mediastinum (May 12th 1998), the tumor was found considerably smaller. It still invaded the pericardium and both phrenic nerves, the left innominate vein and the upper lobe of the left lung, but the pulmonary artery was now free. Resection of the thymus was carried out, including in the specimen the pericardium, segments of both phrenic nerves and the left innominate vein. The tumor was dissected off the aorta and the left pulmonary artery. Invasion of the left upper lobe was managed by a wedge resection, staying at a 2 cm distance from the neoplasm. The postoperative course was uneventful, and

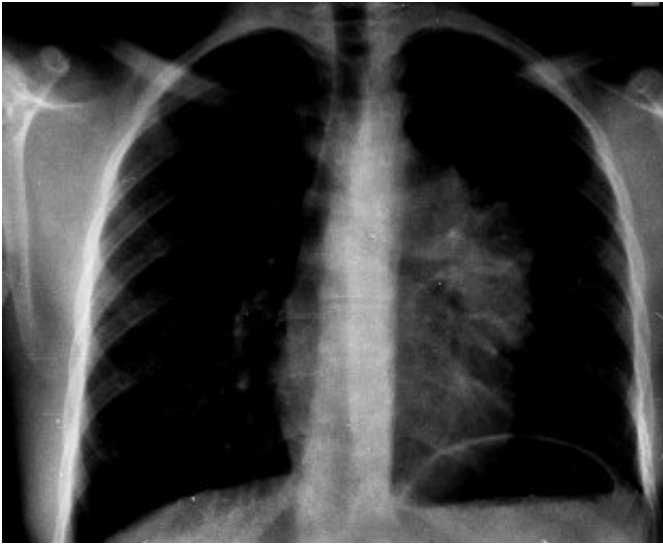

Fig. 2: Patient 2. Roentgenogram shows large mediastinal mass.

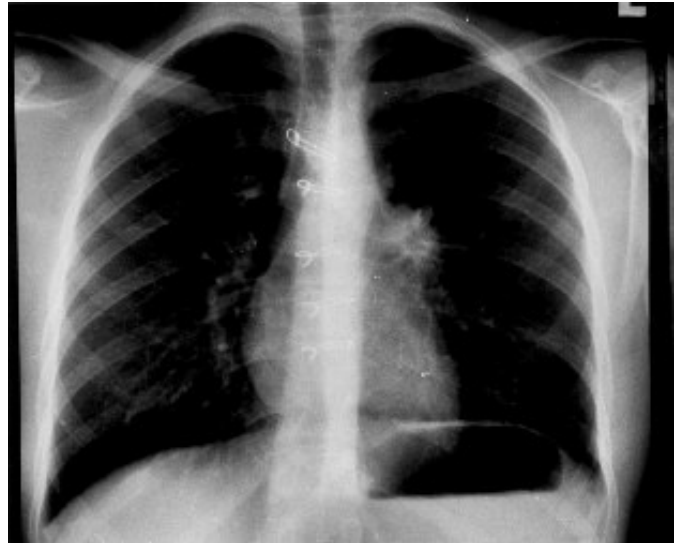

Fig. 3: Roentgenogram of patient 2 shows marked regression of the neoplasm following chemotherapy.

during the following months, the patient received local irradiation with 4500 cGy and two more courses of Cisplatin, Adriamycin and Cytophosphan. At the last follow-up 30 months after the resection, age 21, he was asymptomatic, studying and working. There was no evidence of recurrence.

Discussion

The main therapy of thymoma is surgical resection (7-11). Its outcome depends on local invasiveness of the neoplasm (9, 10, 12-14). Among the various staging systems, the most commonly accepted is that of Masaoka and associates (15). It defines Stage I as an encapsulated tumor with no gross or microscopic invasion; Stage II as capsular or pleural invasion; Stage III as macroscopic invasion of lung, pericardium, vena cava or aorta. Stage IV A is defined as dissemination within the chest, the pleura or the pericardium, and Stage IV B involves distant metastatic spread.

Okamura and associates (11), in their review of 194 consecutive patients with thymoma, found involvement of the great vessels to be the single most important prognostic factor, with greater adverse effect on survival than completeness of resection. They also pointed out that in patients with Stage III disease, resection should be judged as subtotal, even when all the lesions appear to be resected (11). Resection in Stage IV (A and B alike) is by definition non-curative and adjuvant therapy is mandatory.

The role of adjuvant radiotherapy in patients with Stages III and IV thymoma has been stressed by several authors (9, 16, 17): in Stage III patients who had complete resection followed by adjuvant radiotherapy, the five-year survival rate approached that of normal subjects (16, 17). However, the prognosis was much worse for those with tumors that could not be completely resected.

The role of chemotherapy is controversial. In the experience of Regnard and colleagues (10), chemotherapy was not very effective in thymomas. In contrast, several investigators reported encouraging results with the use of Cisplatin-based chemotherapy for advanced disease (18-22). Loehrer and colleagues (18) demonstrated the effectiveness of chemotherapy in 30 patients with metastatic or recurrent thymomas, with a 50% response rate and a median duration of 11.8 months. Giaccone and associates (22) reported on similar results.

In view of these encouraging data, a combination of both, radiotherapy and chemotherapy should be tried in these advanced cases. Our two patients were classified as Stage IV A (Patient n. 1) and Stage III (Patient n. 2). They were treated 20 years apart, reflecting to some extent the change in approach; but there was another difference in the two. In the first patient, the neoplasm was resectable, although in order to achieve resection, the left lung had to be sacrificed. In our second patient, we preferred to secure the full benefit of adjuvant therapy, before carrying out the resection, thus saving the patient's lung.

Thymoma is a slow-growing tumor. Successful surgical treatment in advanced cases is possible, if aided by radiotherapy and chemotherapy. The adjuvant therapy enables conversion of a non-resectable tumor to a resectable one.

References

- 1) Wilkins E.W. Jr.: *Thymoma*. In: Pearson F.G., Deslauriers J., Ginsberg R.J., Hiebert C.A., McKneally M.F., Urschel H.C. Jr., eds. *Thoracic surgery*. Churchill Livingstone, New York, 1419-27, 1995.
- 2) Bernatz P.E., Harrison E.G., Clagett O.T.: *Thymoma: a clinicopathologic study*. *J Thorac Cardiovasc Surg*, 42:424-44, 1961.

- 3) Rosai J., Levine G.D.: *Tumors of the thymus*. In: *Atlas of tumor pathology*. 2nd Ser. Fasc. 13. Armed Forces Institute of Pathology, Washington, 34, 1976.
- 4) Kirchner T., Müller-Hermelink H.K.: *New approaches to the diagnosis of thymic epithelial tumors*. In: Fenoglio-Preiser C.M., Wolff M., Rilke F., eds. *Progress in surgical pathology*, vol. 10. Field and Wood Medical Publishers, New York, 167-89, 1989.
- 5) Gödel N., Böning L., Fredrik A., Hölzel D., Hartenstein R., Willmanns W.: *Chemotherapy of invasive thymoma: a retrospective study of 22 cases*. *Cancer*, 63:1493-1500, 1989.
- 6) Kirschner P.A.: *Reoperation for thymoma: report of 23 cases*. *Ann Thorac Surg*, 49:550-54, 1990.
- 7) Weissberg D., Goldberg M., Pearson F.G.: *Thymoma*. *Ann Thorac Surg*, 16:141-47, 1973.
- 8) Maggi G., Giaccone G., Donadio M., et al.: *Thymomas. A review of 169 cases, with particular reference to results of surgical treatment*. *Cancer*, 58:765-76, 1986.
- 9) Cooper J.D.: *Current therapy for thymoma*. *Chest*, 103:334S-35S, 1993, (Supplement, April 1993).
- 10) Regnard J.F., Magdeleinat P., Dromer C., et al.: *Prognostic factors and long-term results after thymoma resection: a series of 307 patients*. *J Thorac Cardiovasc Surg*, 112:376-84, 1996.
- 11) Okamura M., Miyoshi S., Takeuchi Y., et al.: *Results of surgical treatment of thymomas with special reference to the involved organs*. *J Thorac Cardiovasc Surg*, 117:605-13, 1999.
- 12) Batata M.A., Martini N., Huvos A.G., et al.: *Thymoma: clinicopathological features, therapy and prognosis*. *Cancer*, 34:389-96, 1974.
- 13) LeGolvan D.B., Abell M.R.: *Thymomas*. *Cancer*, 39:2142-57, 1977.
- 14) Gamondes J.P., Balawi A., Greenland T., et al.: *Seventeen years of surgical treatment of thymoma: factors influencing survival*. *Eur J Cardiothorac Surg*, 5:124-31, 1991.
- 15) Masaoka A., Monden Y., Nakahara K., et al.: *Follow-up study of thymomas with special reference to their clinical stages*. *Cancer*, 48:2485-92, 1981.
- 16) Nakahara K., Ohno K., Hashimoto J., et al.: *Thymoma: results with complete resection and adjuvant postoperative irradiation in 141 consecutive patients*. *J Thorac Cardiovasc Surg*, 95:1041-47, 1988.
- 17) Urgesi A., Monetti U., Rossi G., Ricardi U., Casadio C.: *Role of radiation therapy in locally advanced thymoma*. *Radiother Oncol*, 19:273-80, 1990.
- 18) Loehrer P.J. Sr., Perez C.A., Roth L.M., et al.: *Chemotherapy for advanced thymoma: preliminary results of an intergroup study*. *Ann Intern Med*, 113:520-24, 1990.
- 19) Macchiarini P., Chella A., Ducci F., et al.: *Neoadjuvant chemotherapy, surgery and postoperative radiation therapy for invasive thymoma*. *Cancer*, 68:706-13, 1991.
- 20) Rea F., Sartori F., Loy M., et al.: *Chemotherapy and operation for invasive thymoma*. *J Thorac Cardiovasc Surg*, 106:546-49, 1993.
- 21) Park H.S., Shin D.M., Lee J.S., et al.: *Thymoma: a retrospective study of 87 cases*. *Cancer*, 73:2491-98, 1994.
- 22) Giaccone G., Ardizzoni A., Kirkpatrick A., et al.: *Cisplatin and etoposide combination chemotherapy for locally advanced or metastatic thymoma: a phase II study of the European Organization for Research and Treatment Lung Cancer Cooperative Group*. *J Clin Oncol*, 14:814-20, 1996.

Commento

Commentary

Prof. Ruggero BAZZOCCHI
 Ordinario di Chirurgia Generale
 Università di Bologna

Il lavoro presentato da Weissberg è un "case report" di due casi clinici di timoma con invasione di strutture vascolari mediastiniche (stadio III - IV A), corredato da alcune brevi considerazioni sulla terapia multimodale della patologia in questione.

Per quanto concerne i due casi clinici devo dire che l'ampio periodo che intercorre fra la gestione dei due casi (1979-1997) da un lato costituisce un elemento importante di confronto terapeutico diacronico della malattia; dall'altro, tuttavia, offre un panorama sicuramente datato e non recentissimo in un campo dove, sebbene i baluardi della terapia rimangono ancora quelli presentati dall'Autore, sono state introdotte nuove vie di approccio multimodale.

In conclusione ricordo che i timomi sono generalmente delle neoplasie a lenta crescita la cui prognosi dipende largamente dall'invasione macro e microscopica della capsula e dei tessuti vicini. La chirurgia è fuor di dubbio il gold standard terapeutico ed anche le resezioni palliative sembrano migliorare la sopravvivenza di tali pazienti; la radioterapia post operatoria è indicata in casi di invasione capsulare anche in caso di exeresi radicale poiché si è rilevato che migliora il controllo locale e le aspettative di vita. La chemioterapia neoadiuvante ed anche la radioterapia sono state utilizzate con buoni risultati in pz. con tumori non aggredibili in prima istanza con la chirurgia perché troppo estesi. Concludo ricordando l'esperienza di alcuni Autori dello stesso paese di Weissberg che hanno descritto l'uso della termochemioterapia perfusiva associata alla resezione con buoni risultati.

Weissberg's study is a case report about two thymomas with mediastinal blood vessels invasion (stage III-IV A), with brief considerations on multimodal therapy.

As far as the two cases are concerned, the long time elapsing between the two events (1979-1997), on one side might be an important element for a diachronic therapeutic comparison; on the other side it definitely shows a not-recent prospective in a field where, although the author's therapy-highlights are still valid, new multimodal approaches have already been introduced.

I would like to stress out how thymoma is usually a slow-growing neoplasm and the prognosis basically relies on the capsule and the nearby tissues micro and macro invasion.

Surgery is undoubtedly the therapeutic gold standard but palliative resections, also, might improve the overall survival. Post operative radiotherapy is indicated in case of capsule invasion even with radical exeresis, since it has been proved that it improves local control and life expectations. Both neoadjuvant chemotherapy and radiotherapy have been undertaken with appreciating results in patients whose neoplasm cannot be attacked with surgery in first instance, because of their wide extension.

Finally I would like to point out how some authors (Weissberg fellow-countrymen) described good results with perfusive thermochemiotherapy combined to resection.

Address for correspondence:

Dov WEISSBERG,
Department of Thoracic Surgery
E. Wolfson Medical Center
Holon 58100 - ISRAEL
Tel.: 972-8-946-6194
Fax: 972-3-503-6408
E-mail: dovww@ccsg.tau.ac.il

