

Combined brachial embolectomy and stent graft endovascular exclusion in the treatment of acute arm ischemia due to subclavian artery aneurysms thrombosis or distal embolization



Ann. Ital. Chir., 2016 87: 577-582

pii: S0003469X16025537

free reading: www.annitalchir.com

Andrea Siani*, Federico Accrocca*, Gennaro de Vivo* Luca Maria Siani**,
Federica Mounayergi*

*Unit of Vascular and Endovascular Surgery, "San Paolo" Hospital ASL RM4, Civitavecchia, Rome, Italy

**Department of Anesthesiology and Intensive care European Hospital, Rome, Italy

Combined brachial embolectomy and stent graft endovascular exclusion in the treatment of acute arm ischemia due to subclavian artery aneurysms thrombosis or distal embolization.

AIM: Purpose of this study is to report our results after simultaneous transbrachial embolectomy and endovascular aneurysm exclusion with stentgraft in the treatment of upper limb acute ischemia due to subclavian artery aneurysm thrombosis and embolization .

METHODS: From January 2010 to December 2015, seven consecutive patients (6 men; mean age 71.5, range 44-85) underwent to emergent revascularization for upper limb ischemia due to thrombosis/embolization of SAA by means of brachial embolectomy and endovascular exclusion. Demographics, clinical, surgical data, complications and survival were recorded. Univariate analysis by chi-square was carried out to evaluate the role of demographics data and risk factors variables on reconstruction patency rate. Primary, primary assisted and secondary patency and limb salvage were calculated using the Kaplan Meyer's life table method.

RESULTS: Successful treatment was achieved in all cases. No postoperative death or complications occurred. Primary and assisted primary patency rates at 1 and 3 years were respectively 85.7%, 71.4% and 100%. Secondary patency and limb salvage at 1 and 3 years was 100%. A fatal ischemic stroke occurred in 1 case at 6 months (14.2%). A redo PTA was carried out at 24 months. Univariate analysis showed as demographics data and risk factor variables did not influence the primary, assisted primary, secondary patency rate and limb salvage.

CONCLUSION: Endovascular repair is a less invasive alternative to open repair especially in high risk patients. long term results must still be confirmed in further studies.

KEY WORDS: Arm ischemia, Endovascular treatment, Subclavian aneurysm

Introduction

Upper limb ischemia due to thrombosis or distal embolization of subclavian artery aneurysm (SAA) is well reported emergency in literature. Open repair, by means

of aneurysm resection, insertion of prosthetic graft and distal thromboembolectomy still remains the best treatment, but is technically demanding and shows high morbidity and mortality rate, especially in high risk patients ¹⁻². Simultaneous brachial embolectomy and endovascular aneurysm exclusion with stent graft seems to be an interesting and less invasive approach in selected cases. We present our single experience with combined brachial embolectomy and endoluminal stenting in patients with upper limb ischemia due to SAA thrombosis or distal embolisation.

Pervenuto in Redazione Marzo 2016. Accettato per la pubblicazione Maggio 2016

Correspondence to: Andrea Siani, via Giacinto Carini 64a, 00152 Roma (e-mail: andrea.siani@aslrmf.it)

Materials and Methods

From January 2010 to December 2015, seven consecutive patients with acute upper limb ischemia due to SAA thrombosis or distal embolization submitted to combined brachial embolectomy and endovascular aneurysm exclusion were retrospectively analyzed.

Demographics, clinical and surgical data are recorded, prospectively entered into a database and analysed retrospectively (Table I). All the patients underwent to clinical assessment, Duplex scan examination and Angio CT scan to evaluate the vessel diameter and to assess the suitability for endovascular treatment. Inclusion criteria for endovascular approach was a proximal neck diameter < 12 mm with a length of 1 cm at least from the origin of vertebral artery. Mismatch diameter between the proximal and distal landing zone, a rich network of collateral arteries that arise from the sac and distal landing zone crossing the first rib were not considered as contraindication for endovascular approach. Exclusion criteria

were a proximal neck diameter > 12 mm with length < 1cm and vertebral artery origin from the sac. All the patients were operated under local anesthesia. After heparin administration (100 UI/Kg), trans-femoral angiography was routinely carried out (Fig. 1A). After brachial artery cut-down, fluoroscopically assisted thromboembolectomy with N° 5 / 6 Fogarty catheter was performed. To avoid embolic materials dislodgement in to the vertebral artery, a 3/4 mm in diameter x 2 cm in length balloon was previously placed through femoral approach into the proximal vertebral artery and ballooned upon the embolectomy and stent graft deployment (Fig. 1b). After inflow recovery, a 9 Fr sheath 10 cm in length was placed through the brachial artery. The aneurysm was crossed with 5 Fr Bern Catheter under 0,035 soft guide wire (TERUMO, Tokyo, Japan) and excluded with a VIABAHN® self-expanding stent-graft (W.L. Gore & Associates, Inc.; Flagstaff, AZ, USA). Stent graft was routinely ballooned with non compliant balloon (MUSTANG, Boston Scientific, Natick, MA, USA)

Table I - Patients demographics, clinical and surgical data

Pt	age	ET	sex	Co	IS	ASA	Onset	Procedure	Outcome	FU months
1	65	ATS	M	CAD, HYP, DM, COPD	II a	ASA III	>6h	Embolectomy VIABAHN 9x50 mm Vertebral balloon 4x2	Good	36
2	74	ATS	M	CAD, COPD, HYP, ESRD	II b	ASA IV	>8h	Embolectomy VIABAHN 8x50 mm Vertebral balloon 3x2	Good	PTA at 13 ok 30
3	85	ATS	M	CAD, COPD, HYP, ESRD DM	I a	ASA IV	>6h	Embolectomy VIABAHN 8x50 mm + VIABAHN 7x50 Vertebral balloon 4x2	Good	25
4	81	TOS	M	CAD, COPD Previous Rib resection	I a	ASA III	>7h	Embolectomy VIABAHN 9x50 mm Vertebral balloon 4x2	Good	9
5	68	TOS	M	CAD, COPD Previous Rib resection	II b	ASA II	>10h	Embolectomy VIABAHN 8x50 mm Vertebral balloon 4x2	Good	Fatal stroke 6
6	44	MS	F	Previous Arch Replacement	Ia	ASA II	>10h	Embolectomy VIABHAN 7x50 mm Vertebral balloon 3x2	Good	12
7	71	ATS	M	CAD, COPD, DM, ESRD	I a	ASA IV	>6h	Embolectomy VIABAHN 9x50 mm +VIABAHN 8x50 mm Vertebral balloon 4x2	Good	18

Legend: FU: Follow up; ATS: atherosclerosis, MF: Marfan syndrome, TOS: arterial complication of post-traumatic thoracic outlet syndrome, DM: diabetes mellitus; CAD: coronary artery disease; ESRD: end renal stage; HYP: hypertension; COPD: chronic obstructive pulmonary disease; ET: etiology, IS: ischemia stage according with Rutherford classification, CO: comorbidities.

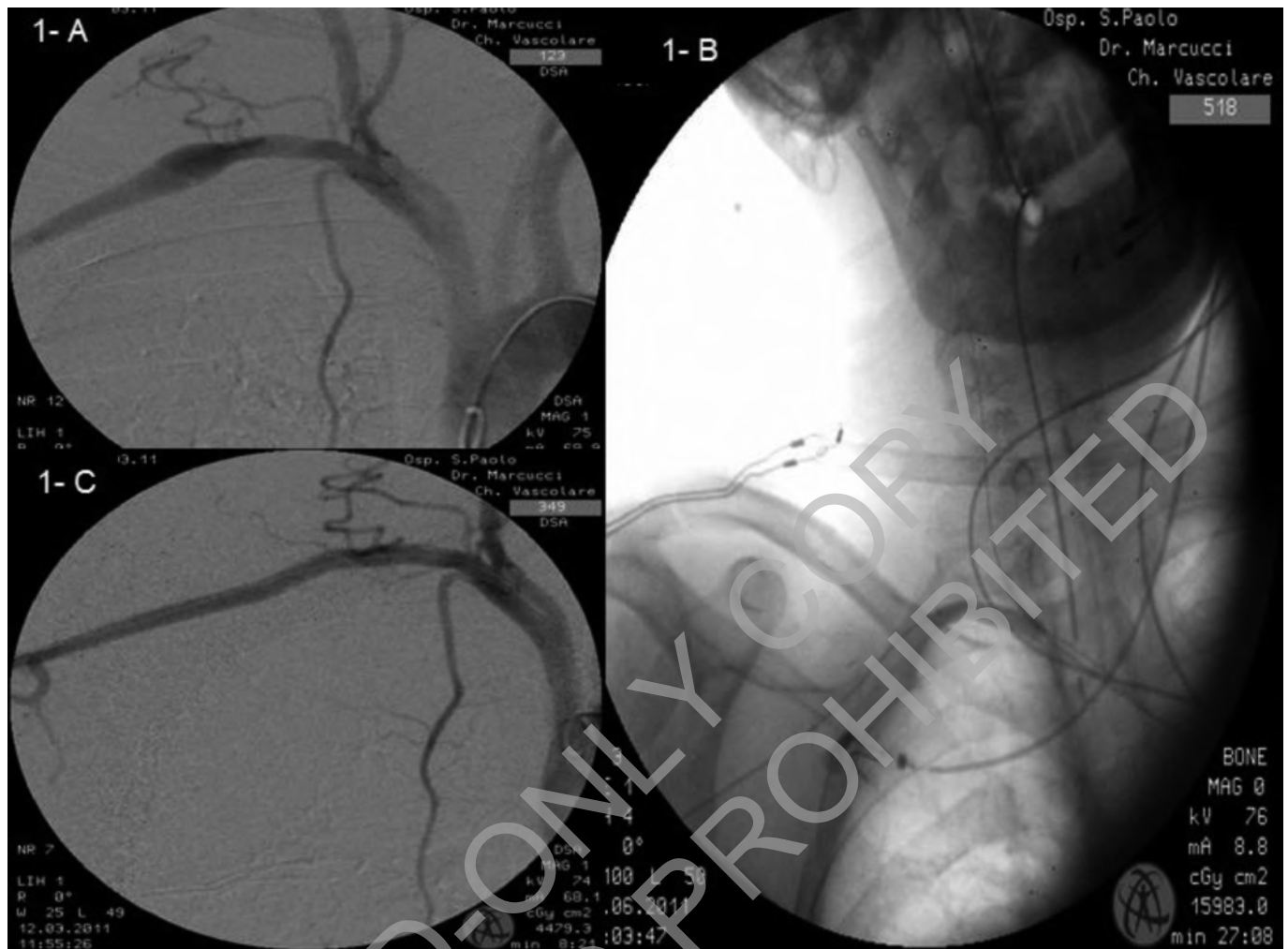


Fig. 1a-b-c: Intraoperative view of subclavian artery aneurysm (1-A). VIABAHN 8x5 mm was placed and ballooned. A 4-2 mm balloon was placed and ballooned at the vertebral origin according with landmark wire technique to avoid retrograde embolization (1-B). Control angiography shows an excellent exclusion of aneurysm, patent vertebral and mammary arteries (1-C).

(Fig. 1C). Distal embolectomy was carried out routinely at the end of endovascular procedure. Dynamic control angiography was performed at the end of procedure. No thrombolysis or secondary surgical procedure were performed.

Mortality, primary, assisted and secondary patency were defined according the SVS and the North American chapter of International Society for Cardiovascular Surgery reporting Standards. Univariate analysis by chi-square was carried out to evaluate the role of demographics data and risk factors variables on reconstruction patency rate. Primary, primary assisted and secondary patency and limb salvage were calculated using the Kaplan Meyer's life table method. The statistical analysis was performed with SPSS software (13.0 version, SPSS Inc., Chicago, USA). A P value <0.05 was considered statistically significant.

Results

Seven consecutive patients (6 men; mean age 71.8 years, range 44-85) underwent to emergent revascularization by means of brachial embolectomy and endovascular exclusion for upper limb acute ischemia due to SAA thrombosis or distal embolization. Comorbidities included: 6 patients (85.7%) with coronary artery diseases and chronic obstructive pulmonary disease, 3 patients (42.8%) with severe hypertension, end renal stage disease and diabetes mellitus type I. Four patients (57.1%) were class Ia, 2 class IIb (28.4%) and 1 class IIa (14.2%) (57.1%) according with Rutherford classification for acute limb ischemia. Degenerative aneurysms were found in 4 cases (57.1%). In two cases (28.4%), the SAA were associated with recurrent thoracic outlet syndrome and in 1 case with a Marfan syndrome. No iatrogenic or post-

Table II - Univariate analysis of risk factor associated with restenosis or occlusion

Risk Factor	Univariate analysis	
	HR (95%CI)	P value
Diabetes mellitus	0.15(0.04-0.56)	.089
ESRD	0.19(0.09-0.62)	.201
Onset >6 hours	0.12(0.14-0.26)	.077
Onset <6 hours	0.18(0.06-0.50)	.001
Class I	0.98(0.425-2.374)	.821
Class IIa	1.52(0.89-4.545)	.521
Class IIb	1.23(1.83-3.211)	.721

traumatic aneurysm were observed in these series. No other aneurysms were detected at level of popliteal arteries or abdominal aorta. Five patients (71.4%) were considered at high risk for open surgical repair due to severe comorbidity and age. In two cases (28.5%) a scalenectomy with first rib excision through supraclavicular approach were carried out 10 years ago. In 1 case (14.2%) a previous total arch replacement for chronic dissection in Marfan syndrome was reported.

In our series, aneurysms were located at extrathoracic subclavian portion in all the cases with mean diameter of 2.6 cm (range 2.4-3.4 cm) and mean length of 5.1 cm (4.3-8.1 cm). Proximal landing zone was at least 10 mm in length from the origin of vertebral artery in all cases with a mean diameter of 8 mm (7-10 mm). Distal landing zone was over the costo-clavicular space in two cases.

No patient died in the postoperative period and no complications occurred. No perioperative graft occlusion, misplacement, kinking and type I or II endoleak were recorded. Brachial embolectomy and endovascular stent graft treatment was successful in all patients. There were 9 Viabahn endoprosthesis. Two stent-graft was necessary for complete exclusion of the aneurysm in two patients. The overlapping between two stents was at least 3 cm. In no cases a main mismatch between proximal and distal landing zone was observed and in no cases a tapered iliac extension was deployed. No vertebral spasm due to balloon inflation were detected. Mean vertebral artery occlusion time due to ballooning was 3 minutes (1-5 minutes). In two cases recurrent thoracic outlet syndrome was detected. A Staged (<5 days) first rib resection through trans-axillary approach was carried out to prevent graft compression. All patients received Aspirin 100 mg/day and Clopidogrel 75 mg/day. A Duplex scan was carried out at 1, 3, 6 and 12 months and then yearly. At follow-up (3-36 months), no endoleaks were recorded. In one case an acute occlusion with retrograde vertebral embolization and fatal massive posterior cerebral infarct occurred at 9 months. In one case a redo PTA with Drug Coated Ballon (Bard Lutonix 8 x 8 mm) was

carried out 24 months later due to focal stenosis of Viabahn. The primary and assisted primary patency rates at 1 and 3 years were respectively 85.7% and 71.4% and 100%. The secondary patency and limb salvage at 12 and 36 months was 100% respectively. Univariate analysis showed as diabetes, ERSD, clinical stage according with Rutherford classification, onset < or > 6 hours did not influence the primary, assisted primary, secondary patency rate and limb salvage. (Table II)

Discussion

SAA account for 1% of all peripheral aneurysms and occur in different clinical settings as atherosclerosis, trauma, thoracic outlet syndrome, infection, arteritis or in cases of aberrant anatomy. Compared with abdominal aortic aneurysms, SAA are more likely to present with compression syndrome or upper limb ischemia due to thrombosis and peripheral embolization or cerebral ischemia due to retrograde embolization¹. Despite open surgical repair still remains the best treatment, considerable associated morbidity and mortality has been reported especially in high risk patients, in cases of intra-thoracic approach or in patients with connective disorders as Marfan Syndrome. Many reports in literature show excellent results of endovascular treatment, as in the case of aortic or visceral aneurysms, with successful technical rate of 100% and procedure related complications between 0% and 20%⁴⁻⁷. Nevertheless, although the endovascular treatment seems very satisfactory, some anatomical features of the subclavian artery would seem to limit its applicability to focal cases such trauma or pseudoaneurysm.

Subclavian artery is subjected to complex dynamic phenomena, with high incidence of stent kinking or fracture, show important vessels origin, with high incidence of Type II endoleak. Moreover it could be subjected to compression in the costo-clavicular space, especially in presence of thoracic outlet syndrome (TOS)⁸. Many solution to improve endovascular treatment has been suggested as stent graft deployment in the brachio-cephalic to common carotid artery and carotid-subclavian bypass in case of proximal subclavian artery aneurysm, vertebral transposition and carotid-subclavian bypass when the vertebral artery originate from the sac, routine first rib resection to prevent graft compression⁹⁻¹¹. These experience are limited and endovascular treatment seems to be appropriate in selective cases in high-surgical risk patients. We treated only high-risk patients and the endovascular approach was preferred on the basis of aneurysm morphology. In all cases aneurysm shows a good proximal neck, vertebral and mammary artery originates at least 10 mm proximally, without other branches that arise from the sac and aneurysms length was generally less of 6 cm. Indeed only in two post traumatic TOS cases, the distal landing zone was over the costo-

clavicular space. In these cases, in our opinion, the first rib resection is mandatory to avoid graft compression and it was performed after few days in elective condition after careful preoperative medical patient evaluation to reduce perioperative risk. We carried out a trans-axillary approach to avoid scar tissue due to previous supraclavicular approach and to perform a more radical first rib resection. Trans-brachial embolectomy with subclavian thrombosis show an important pitfall due to the possibility of dislodge embolic materials into vertebral artery by retrograde passage of the Fogarty catheter. Use of protection device placed in the vertebral artery according with landmark-wire technique seems to be an interesting approach to avoid this complication¹². Balloon in the vertebral artery seems to be more interesting in contrast with carotid filter. We believe that use of the balloon is preferable because it allows a better exclusion of the vertebral artery, affects less complications as spasm or dissection, as report in our series, and appears technically easier to perform even in complex anatomy. Another important issue is the use of fluoroscopically assisted thromboembolectomy that avoid dissection when repetitive attempts were requested to achieve a good inflow, avoiding balloon over inflation with vessel damage or retrograde embolization. Regarding the choice of materials no consensus was reported between self-expanding and balloon expanding covered stent for SAA exclusion. Despite balloon expanding covered stent shows high radial force, visibility and precise release, we prefer a self-expanding covered stent such as Viabahn due to flexibility, pull-out force and kinking resistance that lead to excellent conformability after deployment with optimal sealing and low incidence of shrinkage or dislocation. In cases of diameter mismatch between proximal and distal neck some authors suggest the use of tapered iliac extension. In our series the aneurysm length was < 6 cm and only one stent-graft was generally deployed. In cases where it was necessary the deployment of two stents, the second stent was generally chosen 1 cm less in diameter compared to the first stent to achieve a better seal in the distal subclavian artery and to prevent infolding and type IB endoleak. Despite some authors suggest oral anticoagulation, long term double antiplatelet therapy prevents in-stent restenosis and thrombosis, reducing platelet adhesion and risk of secondary embolization especially during graft neo-endothelialization. Primary patency after stent-graft repair of distal subclavian artery aneurysms is high, as reported in our series, ranging from 85.7 to 100% with technical success of 100% and related complications of 14%¹³. In 1 case a 6 months fatal stroke occurred due to stent graft occlusion because patient had discontinued double antiplatelet therapy. Despite our good results, we believe that this study showed many important statistical limitation because was retrospective. We assessed a few cohorts of patients limiting the powerful of our statistical analysis due to small sample that increase the possi-

bility of type II statistical error. Strict criteria inclusion for endovascular treatment limiting a complete evaluation of SAA disease. Moreover no control group to compare the results of hybrid approach with open repair were carried out suggesting only hypothetical advantages in these revascularization strategy. Given the sample size and total of number events, we did not make a multivariate analysis and so the results should only be consider hypothesis generating. More caution in the evaluation of our results is needed. Long term follow up will be necessary to evaluate the efficacy of this treatment, especially in patients who have a long life expectancy

Conclusion

Combined approach with brachial embolectomy and aneurysm exclusion with stent graft seems to be attractive treatment but should be considered only in selected patients at high-risk for open repair due to severe comorbidity, old age or previous chest surgery in presence of favourable anatomical features for endovascular treatment. In young patient or in low-risk patients, surgical approach seems to be still mandatory.

Riassunto

INTRODUZIONE: Lo scopo del nostro studio è quello di valutare i risultati del trattamento delle ischemie acute dell'arto superiore dovute alla trombosi o all'embolizzazione di un aneurisma succlavio mediante embolectomia omerale con simultanea esclusione endovascolare dell'aneurisma con stent ricoperto.

METODI: da gennaio 2010 a dicembre 2015 abbiamo sottoposto a rivascolarizzazione urgente combinata 7 pazienti (6 uomini, età media 71.5 anni, range da 44 a 85 anni) con ischemia acuta dell'arto superiore dovuta ad embolizzazione o trombosi di un aneurisma succlavio. I dati demografici, clinici ed operatori, le complicanze e la sopravvivenza sono stati raccolti in un database. È stata eseguita un'analisi univariata mediante test del Chi quadro per valutare l'impatto ed il ruolo delle singole variabili demografiche e dei fattori di rischio sulla pervietà delle ricostruzioni eseguite. La pervietà primaria, primaria assistita, secondaria E il salvataggio d'arto sono stati calcolati mediante curve di sopravvivenza

RISULTATI: Abbiamo ottenuto l'esclusione dell'aneurisma e la rivascolarizzazione dell'arto in tutti i casi. Non si sono verificate complicanze ne si è osservata una mortalità precoce. La pervietà primaria ed assistita a 1 e 3 anni è stata dell' 85.7%, 71.4% e 100%. La pervietà secondaria e il salvataggio d'arto a 1 e 3 anni sono stati del 100%. Si è verificato un ictus fatale a 9 mesi (14.2%) È stata eseguita una redo PTA a 24 mesi per una restenosi severa dello stentgraft. L'analisi univariata ha documentato come le variabili demografiche ed i fatto-

ri di rischio non sembrerebbero influenzare i risultati a distanza delle ricostruzioni stesse.

CONCLUSIONI: Il trattamento endovascolare sembra essere una alternativa efficace e meno invasiva della chirurgia tradizionale. Tuttavia è necessaria una valutazione dei risultati a lungo termine al fine di validare tale strategia di trattamento.

References

1. Resch T, Lyden S, Gavin T, Clair D: *Combined open and endovascular treatment of a right subclavian artery aneurysm: A case report.* J Vasc Surg, 2005; 42:1206-209.
2. Schoder M, Cejna M, Hölzenbein T, Bischof G, Lomoschitz F, Funovics M, et al.: *Elective and emergent endovascular treatment of subclavian artery aneurysms and injuries.* J Endovasc Ther, 2003; 10:58-65.
3. Nano G, Bianchi P, Stegher S, Malacrida G, Cazzaniga M, Trimarchi S, Rampoldi V, Tealdi DG: *Endovascular repair of aortic abdominal aneurysms in octagenarian patients: Early and midterm results.* Ann Ital Chir, 2008; 79(5):335-39.
4. Baiocchi GL, Piardi T, Cuomo R, Battaglia G, Ronconi M, Coniglio A, Maroldi R, Portolani N: *Endovascular treatment for bleeding gastroduodenal pseudoaneurysm after acute pancreatitis.* Ann Ital Chir, 2007; 78(2):145-48.
5. Impedovo G, Perilli F, Lillo A, Greco L, Martiradonna F, Angioletta D, Regina G: *Endovascular treatment of aneurysms in the elderly.* Ann Ital Chir, 2003; 74(3):289-93.
6. Meyer T, Merkel S, Lang W: *Combined operative and endovascular treatment of a post-traumatic embolizing aneurysm of the subclavian artery.* J Endovasc Surg, 1998; 5:52-5.
7. Chambers CM, Curci JA: *Treatment of nonaortic aneurysms in the endograft era: Aneurysms of the innominate and subclavian arteries.* Semin Vasc Surg, 2005; 18:184-90.
8. Urschel HC Jr, Patel AN: *Paget-Schroetter syndrome therapy: Failure of intravenous stents.* Ann Thorac Surg, 2003; 75:1693-696.
9. González JM, García BA, Lebrun JM, Docampo MM: *Combined surgery for the treatment of bilateral subclavian artery aneurysm in Marfan syndrome.* J Vasc Surg, 2007; 45:180-82.
10. Van Leemput A, Maleux G, Heye S, Nevelsteen A: *Combined open and endovascular repair of a true right subclavian artery aneurysm without proximal neck.* Interact Cardiovasc Thorac Surg, 2007; 6:406-8.
11. Bruen KJ, Feezor RJ, Lee WA: *Hybrid management of proximal right subclavian artery aneurysms.* J Vasc Surg, 2011; 53:528-30.
12. Park S, Kwak JH, Baek HJ, Park JW, Kim JS, Suh DC: *The Use of Protection Device in Landmark-wire Technique of Symptomatic Subclavian Artery Occlusion with Combined Approach via Trans-femoral vs. Trans-brachial Arteries: Technical note.* Neurointerventio, 2011; 6:89-94.
13. Hilfiker PR, Razavi MK, Kee ST, Sze DY, Semba CP, Dake MD: *Stent-graft therapy for subclavian artery aneurysms and fistulas: single-center mid-term results.* J Vasc Interv Radiol, 2000; 11:578-84.