

G. Illuminati, F.G. Calì, A. D'Urso,
P. Mancini, V. Papaspyropoulos, G. Ceccanei,
R. Lorusso, F. Vietri

Università degli Studi di Roma "La Sapienza"
Dipartimento di Scienze Chirurgiche e Tecnologie Mediche
Applicate
U.O. Chirurgia Generale e Toracica - IV Clinica Chirurgica
Azienda Policlinico Umberto I

Introduction

Surgery for ilio-femoral venous obstruction is not frequently performed (9). The relatively small number of operated patients and the short length of follow-up in individual series, hinder a complete standardization of surgical techniques and indications (17).

The results of surgery for treating ilio-femoral venous obstruction in 9 consecutive patients are reported herein, in order to further contribute to the choice of the most appropriate method of treatment, when dealing with this condition.

Material and methods

From October 1994 to April 2002, 9 patients were operated on for ilio-femoral venous obstruction. Five patients were females and 4 were males, of a mean age of 48 years (Extremes 24-73). Eight patients presented with clinical signs of chronic venous insufficiency, oedema and pain of the lower limb, chronic dermatitis, perimalleolar ulcer, and venous claudication. In 7 patients these symptoms were resistant to medical treatment for more than 12 months. Venous obstruction was related to iliac vein compression by retroperitoneal sarcoma in one case, compression by an inflammatory infrarenal aortic aneurysm in 2 cases, chronic venous thrombosis in 3, a May-

Riassunto

IL TRATTAMENTO CHIRURGICO DELL'OSTRUZIONE VENOSA ILIO-FEMORALE

Obiettivo: Valutazione retrospettiva del trattamento chirurgico dell'ostruzione venosa ilio-femorale.

Metodi: Revisione di 9 casi operati, dell'età media di 48 anni. La causa dell'ostruzione era rappresentata in 3 casi da una compressione estrinseca: un sarcoma retroperitoneale in un caso ed un aneurisma dell'aorta sottorenale in altri due. In 2 casi si trattava di una sindrome di Cockett, in 3 di una trombosi cronica ilio-femorale e di una stenosi segmentaria post-traumatica in un caso. Il trattamento chirurgico è consistito in una messa a piattolinnesto protesico aorto-biliaco nei due aneurismi dell'aorta sottorenale, in un ponte femoro-cavale in politetrafluoroetilene (PTFE) nell'ostruzione neoplastica, in una trasposizione dell'arteria iliaca comune destra nell'ipogastrica sinistra nelle 2 sindromi di Cockett, in 3 interventi di Palma nella trombosi cronica ed in una interposizione di vena giugulare interna nella stenosi segmentaria post-traumatica.

Risultati: Non si sono verificati decessi postoperatori né occlusioni precoci delle rivascolarizzazioni venose. Tutti i pazienti presentavano un sensibile miglioramento dei sintomi di insufficienza venosa durante tutto il "follow-up" la cui durata media è stata di 38 mesi.

Conclusioni: La natura dell'ostacolo al ritorno venoso e la presenza di sintomi ribelli al trattamento medico costituiscono le principali indicazioni alla rivascolarizzazione venosa ilio-femorale. La scelta dell'intervento più appropriato nelle diverse situazioni assicura l'ottenimento di buoni risultati.

Parole chiave: Ostruzione venosa ilio-femorale, trattamento chirurgico.

Abstract

Methods: A series of 9 patients of a mean age of 48 years, operated on for compression of the ilio-femoral venous axis is reported. The cause of obstruction was external compression in 3 cases, a retroperitoneal sarcoma in 1 case, and an infrarenal aortic aneurysm in 2. Two patients presented with a Cockett's syndrome, 3 with a chronic ilio-femoral thrombosis, and one with a post-traumatic segmentary stenosis. Treatment consisted in a resection/Dacron grafting of 2 infrarenal aortic aneurysms, one femoro-caval bypass graft, 2 transpositions of the right common iliac artery in the left hypo-

gastric artery for Cockett's syndrome, 3 Palma's operations for chronic thrombosis, and one internal jugular vein interposition for segmentary stenosis.

Results: There were no postoperative deaths and no early thromboses of venous reconstructions performed. All the patients were relieved of symptoms during the follow-up period, whose mean length was 38 months.

Conclusion: The cause of venous obstruction and the presence of symptoms which are resistant to medical treatment are the main indications to ilio-femoral venous revascularization. The choice of the optimal treatment in each single case yields satisfactory results.

Key words: Ilio-femoral venous obstruction, surgical treatment.

Turner-Cockett syndrome (4, 13) in 2, and traumatic segmentary stenosis of the external iliac vein due to bicycle accident in one. All the patients underwent Duplex ultrasound, abdominal CT scan, and ascending phlebocavography, as part of their preoperative work-up. In 7 patients, percutaneous measurement of femoral vein pres-

sure was also performed, which yielded a pressure gradient over 8 mmHg between the two veins in all the patients. The two patients bearing an abdominal aortic aneurysm were also evaluated by thoracoabdominal CT scan and arteriography.

The infrarenal inflammatory aortic aneurysms were treated by resection/aortoiliac grafting, which relieved compression and determined regression of symptoms.

Compression on the right ilio-caval axis by non resectable retroperitoneal sarcoma was treated by right femoral vein to inferior vena cava (IVC) bypass with a polytetrafluoroethylene (PTFE) 8 mm graft (W.L. Gore and ass., Flagstaff, Arizona, USA); an arterio-venous fistula (AVF) from the superficial femoral artery to the superficial femoral vein was associated (Fig. 1).

Two patients presenting with a right common iliac vein compression by the right common iliac artery (May-Thurner-Cockett syndrome), were treated by transposition of the right common iliac artery into the left hypogastric artery; in one case a venous angioplasty was associated (Fig. 2).

The segmentary stenosis of the left external iliac vein

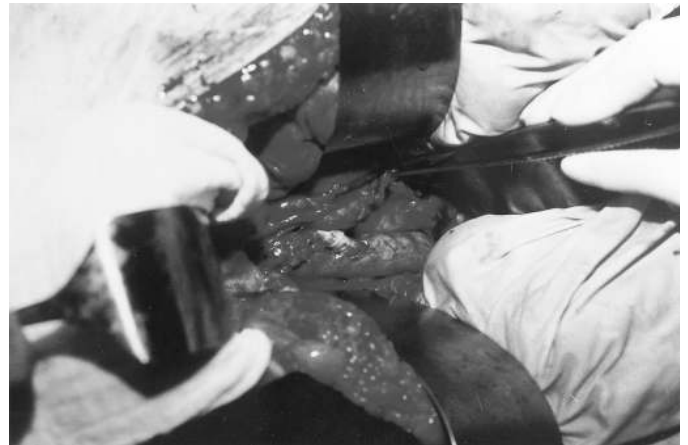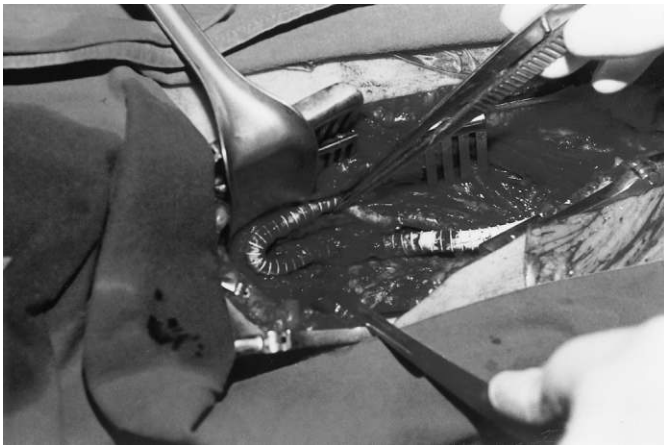


Fig. 1: Intraoperative picture. PTFE femoro-caval bypass: proximal anastomosis and AVF from superficial femoral artery and common femoral vein proximal to bypass (A); distal anastomosis (B).

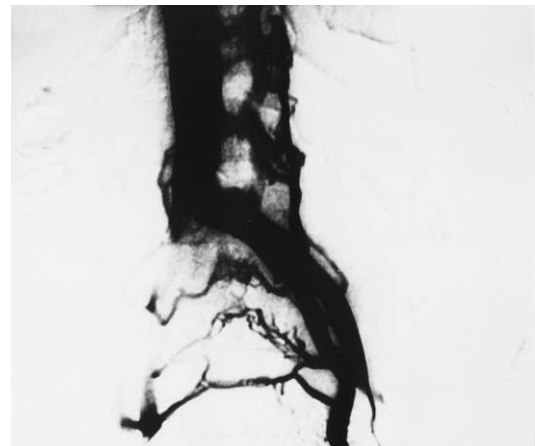
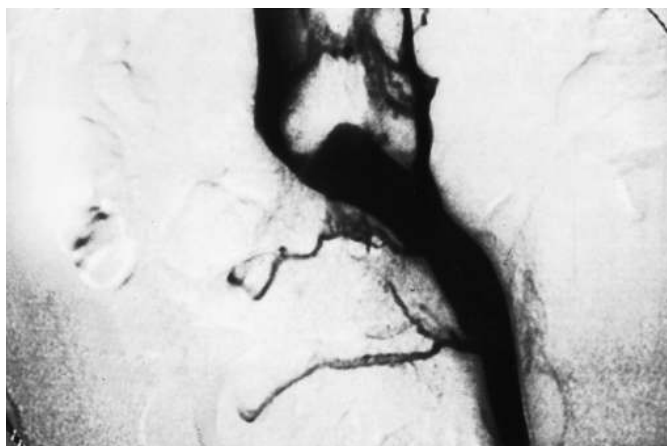


Fig. 2: Cockett's Syndrome. Pre and postoperative ascending phlebocavography: preoperative compression of the left ilio-caval junction (A); satisfactory patency after transposition of the right common iliac artery into the left hypogastric artery and venous angioplasty (B).

was treated by resection of the stenosed segment and interposition of a valvulated right jugular vein segment, harvested at the Pirogoff junction.

Three patients with a chronic ilio-femoral thrombosis, all exhibiting a pressure gradient over 8 mmHg, between the two femoral veins, were treated by a suprapubic femoro-femoral venous bypass (Palma's operation) (14). The conduit was the contralateral saphenous vein in two cases and an armed, 8 mm, stretch PTFE graft (W.L. Gore and ass., Flagstaff, Arizona, USA). In all the 3 patients an AVF was associated.

If compression by inflammatory aortic aneurysm is excluded, 7 patients underwent some form of direct venous reconstruction, in order to relieve obstruction of flow.

Postoperative medical treatment consisted in low molecular weight subcutaneous heparin for a month followed by oral Aspirin, 100 mg daily, in the 3 patients operated on for external compression (2 infrarenal aortic aneurysms, and 1 retroperitoneal sarcoma). All other patients were treated by intravenous heparin in the first postoperative days, and were subsequently put under Vitamin K inhibitors for a period ranging from 3 to 6 months.

Results

No patient died, and none of the venous revascularizations performed thrombosed in the postoperative period. A lymphocele of the Scarpa's triangle was observed, which was spontaneously resorbed within 3 months.

All the patients were relieved of the symptoms which indicated clinical work-up and operation. All the trophic lesions healed within 4 months which followed operation. All the patients were followed-up from 7 to 93 months (mean 33 months) after operation. Follow-up consisted in a clinical examination with Doppler Ultrasound study every six months in the first year, and every 12 months subsequently.

Of all the patients undergoing direct venous reconstruction, the patient with a retroperitoneal sarcoma died 21 months later of tumor progression, with a patent bypass and an asymptomatic leg.

The two patients operated on for a May-Thurner-Cockett syndrome were both asymptomatic, with patent arterial and venous reconstruction, respectively at 51 and 93 months from operation.

Out of 3 femoro-femoral grafts, one saphenous vein was patent at 34 months, whereas one PTFE and another vein were occluded, respectively at 7 and 19 months. The patients bore all a healed limb.

The internal jugular vein graft, interposed in the left external iliac vein, was patent at 30 months, and the patients was asymptomatic.

The two patients operated on for a compressing infrarenal inflammatory aortic aneurysm were asymptomatic, respectively at 29 and 41 months.

Overall, the mean patency of 7 direct venous reconstructions was 66% at 24 months.

The main clinical features of this series are resumed in table I (Tab. I).

Tab. I – CHARACTERISTICS OF PATIENTS OPERATED ON FOR ILIO-FEMORAL VENOUS OBSTRUCTION

Sex	Age	Pre-operative symptoms	Morphologic data	Treatment	Follow-up
M	73	Lumbar pain, lower left limb oedema	Inflammatory aneurysm of infra-renal aorta, compression of left common iliac vein	Aorto-biiliac graft	Asymptomatic, 41 months
M	71	Left iliac fossa pain, inferior left limb oedema	Aneurysm of infrarenal aorta, compression of left common iliac vein	Aorto-biiliac graft	Asymptomatic, 29 months
M	62	Right lower limb oedema	Retroperitoneal solid mass, compression of right common iliac vein	Femoro-caval by-pass/PTFE	Deceased at 21 months, patent by-pass
F	24	Left lower limb oedema, venous claudication	Compression of left ilio-caval confluent	Arterial trasposition	Asymptomatic, patent at 51 months
F	29	Left lower limb oedema	Compression of left ilio-caval confluent	Arterial trasposition, venous angioplasty	Asymptomatic, patent at 93 months
M	51	Left lower limb oedema, perimalleolar ulcer	Thrombosis of the left venous iliac axis	Palma's operation (saphenous vein)	Occluded at 7 months, healed
F	47	Left lower limb oedema, perimalleolar ulcer	Thrombosis of the left venous iliac axis	Palma's operation (PTFE)	Occluded at 19 months, healed
F	38	Oedema, ulcer of left leg	Thrombosis of the left venous iliac axis	Palma's operation (saphenous vein)	Patent at 34 months, healed
F	36	Oedema, venous claudication of left lower limb	Stenosis of left external iliac vein	Right jugular vein interposition	Asymptomatic, 30 months

Discussion

Surgical treatment of ilio-femoral venous obstruction is directly related to the nature of obstruction itself. Either neoplastic or non neoplastic compression of ilio-femoral axis or ilio-caval junction, is often the causative agent. Among tumors, retroperitoneal neoplasms are mostly involved in ilio-caval compression or infiltration. In this case the treatment of choice consists in "en bloc" resection of the tumor and the infiltrated venous segment, followed by autologous or prosthetic venous reconstruction. If the tumor is not resectable, as in the case of this series, a venous bypass is indicated, in order to relieve compressive symptoms and ameliorate the quality of patient's residual life. In this setting a prosthetic femoro-caval graft is the treatment of choice. A direct bypass from the femoral vein to the IVC distally to the tumor is to be preferred to a suprapubic crossover bypass, as tumor's growth may infiltrate bilaterally the ilio-caval junction, causing a failure of revascularization on both sides. As conduit material, armed PTFE is superior to the saphenous vein, as it is more resistant to tumor compression or infiltration.

Whenever compression is caused by an infrarenal aortic aneurysm, either inflammatory or chronically ruptured, standard treatment of aneurysm itself is usually sufficient to treat venous compression too.

Compression of the external iliac vein by post-traumatic hematomas and lymphoceles of the pelvis have also been reported: surgical or percutaneous evacuation of the collection represents an appropriate treatment (2).

A compression of the left common iliac vein by right common iliac artery, associated with intraluminal septi, may cause thrombosis of the vein itself. This condition has been described in autopsic (13) and clinical (3, 4) studies. Clinically, it consists of a post-phlebotic syndrome affecting young subjects, usually within 18 to 30 years of age, and is known as Cockett's syndrome. Usually it is characterized by an evolution on two stages. The first one is characterized by the acute onset of a painful edema of the left lower limb, whereas chronic edema, trophic ulcers, and venous claudication are the symptoms of the chronic stage (3, 4, 7, 15). The aim of surgical treatment is to remove the anatomical compression which causes clinical symptoms and associated phlebitis (1).

Several methods have been proposed to treat this condition, including mobilization of the iliac artery followed by interposition of a peritoneal sheet (3) or of fascia lata (16), venous angioplasty (6), and transposition of the right common iliac artery into the contralateral common iliac or hypogastric artery (5, 10). Transposition of the right common iliac artery into the left hypogastric artery yields good results in this set of young patients bearing healthy arteries. We performed it twice, associating a venous angioplasty in one case. Both patients are asymptomatic, respectively at 46 and 51 months. Venous angio-

plasties have also been performed by endovascular route, with good immediate results (12). If possible the operation should not be performed during the acute phase, since acute inflammatory adherences complicate surgical dissection, and significantly enhance the risk of vessels' injury and bleeding. Both cases of this series were operated on during the chronic phase and bore a recanalized iliac vein.

Suprapubic femoro-femoral venous bypass, i.e. Palma's operation, is the treatment of choice for chronic iliac thrombosis. This condition is frequently well controlled by medical treatment alone, whereas long term patency of venous bypasses is moderately satisfactory (11). For this reason, surgical treatment should be reserved to cases resistant to medical treatment over 12 months, with a patent profunda femoral vein on the affected side, and a pressure gradient over 10 mmHg between the two common femoral veins (18). The presence of an adequate pressure gradient is of paramount importance for indicating a bypass, since venous collaterals themselves already develop a spontaneous bypass, which would threaten the patency of surgical bypass, in the case that pressure gradient is insufficient. In this setting the saphenous vein is the material of choice for grafting, PTFE being an alternative to an unsuitable autogenous vein (19). The 3 patients of this series presented non healing ulcers of the lower limb for more than a year. The risk of evolution towards a spinocellular carcinoma in chronically non healing ulcers is a further argument for surgery, when medical treatment alone fails. It may be argued that only one graft remained patent for more than 2 years: nevertheless all of them were effective for healing ulcers, which remain healed even after graft thrombosis.

The interposition of a venous graft for the treatment of a segmentary stenosis has been performed only once, for a post-traumatic fibrotic stenosis of the external iliac vein. The graft material of choice, in this case, is a segment of right internal jugular vein, at the Pirogoff junction, as the diameter is almost superposable to that of the external iliac vein, and the presence of a continent valve, at this site, is almost constant. Patency and functional results of this operated case are satisfactory at 3 years. In direct venous reconstructions, the association of an AVF has been proposed, with the aim of ameliorating graft flow, and immediate patency (8). In this series, it has been associated to the femoro-caval and the 3 femoro-femoral bypasses. In no case it was necessary to perform surgical or endovascular occlusion of the AVF, since all of them spontaneously thrombosed after a delay of 2 to 8 months. Although a general consensus validating the association of AVF to venous bypasses is lacking, the present series supports the utility of such association, as it is likely that the absence of any postoperative bypass thrombosis is also due to the presence of AVF.

In conclusion, the role of surgery in the obstruction of ilio-femoral venous axis is limited by the disappointing

patency rate of direct venous reconstructions. Nevertheless, the present series supports the validity of surgical treatment specific for each individual condition, when symptoms are resistant to long term medical treatment.

Bibliografia

- 1) Becquemin J.P., Juillet Y., Mexme M., Fiessinger J.N., Cormier J.M., Housset E.: *Syndrome de Cockett: aspects cliniques*. Nouv Presse Med, 1981, 10:959-62.
- 2) Brown K.M., Borge M.A., Labropoulos N., Baker W.H.: *Pelvic lymphocele following motor vehicle collision*. Ann Vasc Surg, 2002, 16:121-5.
- 3) Cockett F.B., Lea Thomas M.: *The iliac compression syndrome*. Br J Surg, 1965, 52:816-21.
- 4) Cockett F.B., Lea Thomas M.: *Iliac vein compression. Its relation to iliofemoral thrombosis and the post-thrombotic syndrome*. Br Med J, 1967, 2:14-9.
- 5) Cormier J.M.: *Transposition de l'artère iliaque primitive sur l'hypogastrique contra-latérale*. Nouv Presse Med, 1980, 9:2015-7.
- 6) Dale W.A.: *Reconstructive venous surgery*. Arch Surg, 1979, 114:1312-8.
- 7) David M., Striffling V., Brenot R., Barault J.F., Trigalou D.: *Syndrome de Cockett acquis*. Ann Chir, 1981, 35:93-8.
- 8) Husni E.A.: *Reconstruction of veins: the need for objectivity*. J Cardiovasc Surg, 1983, 24:525-8.
- 9) Ijima H., Kodama M., Hori M.: *Temporary arteriovenous fistula for venous reconstruction using synthetic graft: a clinical and experimental investigation*. J Cardiovasc Surg, 1981, 26:131-6.
- 10) Jaszczak P., Mathiesen F.R.: *The iliac compression syndrome*. Acta Chir Scand, 1978, 144:133-6.
- 11) Lalka S., Lash J.M., Unthank J.L., Lalka V.K., Cicrit D.F., Sawchuk A.P., et al.: *Inadequacy of saphenous vein grafts for cross-femoral venous bypass*. J Vasc Surg, 1991, 13:622-30.
- 12) Lamont J.P., Pearl G.J., Patetsios P., Warner M.T., Gable D.R., Garrett W., et al.: *Prospective evaluation of endoluminal venous stents in the treatment of the May-Thurner syndrome*. Ann Vasc Surg, 2002, 16:61-4.
- 13) May R., Thurner J.: *The cause of predominantly sinistral occurrence of thrombosis of the pelvic veins*. Angiology, 1957, 8:419-27.
- 14) Palma E.C., Esperon R.: *Vein transplants and grafts in the surgical treatment of the post-phlebotic syndrome*. J Cardiovasc Surg, 1960, 1:94-6.
- 15) Pinsolle J., Videau J.: *Anomalies du carrefour ilio-cave*. Chirurgie, 1982, 108:451-8.
- 16) Rigas A., Vomvoyannis A., Tsardakas E.: *Iliac compression syndrome. Report of ten cases*. J Cardiovasc Surg, 1970, 11:389-94.
- 17) Verhaege R.: *Iliac vein compression as an anatomical cause of thrombophilia: Cockett's syndrome revisited*. Thromb Haemost, 1995, 6:1398-401.
- 18) Vollmar J.: *Reconstruction of the iliac veins and inferior vena cava*. In Hobbs J (Ed) *The treatment of venous disorders*. MTP Press, London 1977, pp. 320-5.
- 19) Yamamoto N., Takaba T., Hori G., Funami M., Yoshizawa T., Nomoto S., et al.: *Reconstruction with insertion of expanded polytetrafluoroethylene (EPTFE) for iliac venous obstruction*. J Cardiovasc Surg, 1986, 27:697-702.

Autore corrispondente:

Prof. Giulio ILLUMINATI
Via Vincenzo Bellini 14
00198 ROMA
Tel./Fax: 06-49970630
e-mail: giulio.illuminati@uniroma1.it

