

# A mesenteric window to approach a posterior side leak after laparoscopic assisted stapled strictureplasty for Crohn's disease



Ann. Ital. Chir., 2006; 77: 259-262

Irene Fiume, Vincenzo Napolitano, Gianmattia del Genio, Gianluca Rossetti, Alberto Del Genio

Seconda Università degli Studi di Napoli, I Divisione di Chirurgia Generale e Gastroenterologica.

**A mesenteric window to approach a posterior side leak after laparoscopic assisted stapled strictureplasty for Crohn's disease**

*Strictureplasty leak in patients with Crohn's disease increases considerably morbidity rate. Intra-operative evaluation of the integrity of suture line and proficient management of any leakage after strictureplasty is mandatory to prevent post-operative complications. When a leakage is detected at the posterior side, through intra-operative insufflation or methylene blue test, it may be difficult to repair as the suture line is completely covered up by mesentery.*

*The AA. describe the creation of a mesenteric window to reinforce the posterior side of a side-to-side stapled strictureplasty performed by laparoscopic assisted procedure. As far as we know, this new technical strategy may allow avoiding resection of small bowel.*

**KEY WORDS:** Mesenteric window, Posterior side leakage, Stapled strictureplasty, Surgical technique.

## Introduction

The rationale for strictureplasty is to avoid resection and preserve intestinal length and function of the small bowel. The two most widely used procedures are the Heineke-Mikulicz (85%) and Finney (13%) strictureplasties<sup>1</sup>. The use of stapled technique for strictureplasty was first described by Keighley in 1991<sup>3</sup>. It consisted of two small enterotomies in the bowel, 7 cm proximal and distal to the stenotic disease, approximating the loop of bowel above and below the stricture by stay suture and achieving enteroplasty by side-to-side stapling<sup>2-10</sup>. Stapled anastomosis appears to have certain advantages over conventional suture<sup>2-10</sup>. However, if more stapler loads must be fired for confectioning a long strictureplasty, the risk of leakage significantly increases. Patients who develop anastomotic leak have increased morbidity and mortality rates. Therefore, the intra-operative anastomotic testing plays

a fundamental role to evaluate the integrity of suture line especially in high-risk patient as in Crohn's disease. When the tract of intestine is folded back on itself for creation of a side-to-side strictureplasty and a leakage is detected at the anti-mesenteric border, it is possible easily to identify it by using air leakage test, thus it can be over-sewn. In contrast, when the leakage is at the mesenteric border, the surgeon may be not able to see it and reinforce the staple line. In particular, in case of long stenosis and when inflammation leads to a significant thickness of the mesentery, the posterior side of enteroplasty is not accessible with a manoeuvre of turnation. We describe a new strategy to facilitate the access to a disrupted posterior suture line, in a not-turnable long side-to-side strictureplasty, and reinforce the defect.

## Case report

A 64 year old man was admitted in our Department for obstructive symptoms as recurrent colic abdominal pain and enteric vomiting. Physical examination was remarkable for moderate tenderness over the lower right quadrant. He was investigated with abdominal ultrasonography and computerized tomography scans which

*Pervenuto in Redazione Dicembre 2005. Accettato per la pubblicazione Febbraio 2006.*

*For correspondence: Irene Fiume, MD, Via IV Novembre 1, 80055 Portici (Naples), Italy.*

demonstrated wall thickness of the terminal ileal loop in the right lower abdominal quadrant. Colonoscopy with retrograde ileoscopy showed a severe inflammation with stenosis of the terminal ileal loop. Histopathological examination confirmed the diagnosis of Crohn's disease confined to distal ileal region. The patient was referred to strictureplasty with minimally invasive access.

### *Surgical technique*

The patient was placed in supine position with the surgeon and the first assistant standing to the left side. Pneumoperitoneum was established at 12 mmHg pressure and a 5 mm trocar for the camera was inserted at the umbilicus. Two additional ports were placed under direct vision in correspondence of the left upper quadrant and left iliac fossa. The entire small intestine, up to the Treitz ligament, was examined using a "hand over hand" technique with two atraumatic bowel holding forceps. A severe thickening of the terminal ileal loop wall and mesentery was noted at this stage. The small bowel tract involved by the disease was about 60 cm long. Ileo-caecal mobilization was carried out by using radiofrequency (5 mm LigaSure®, Valleylab®, Boulder, USA). Right ureter and duodenum were clearly identified and preserved. Ileo-caecal segment was delivered through a 5 cm Mc-Burney incision and appendectomy was performed. A side-to-side stapled strictureplasty was performed extra-corporeally. The procedure started folding the strictured area over onto itself in a U shape, anchored with interrupted 3/0 sutures. Two small enterotomies were made at a distance of about 3 cm from the beginning and the end of the diseased loop. A 90 mm stapler (GIA 90 PREMIUM™, Auto Suture™) was inserted through the two enterotomies achieving a side-to-side strictureplasty (Fig. 1). Three consecutive fires were necessary to complete the 30 cm

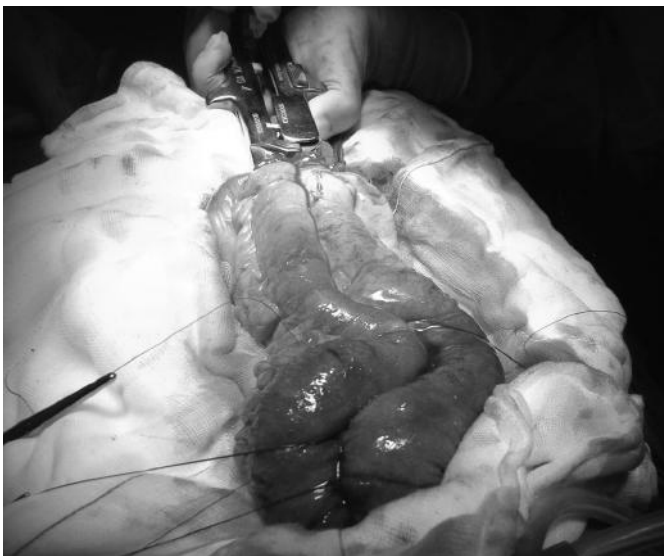

Fig. 1: Creation of a side-to-side enteroplasty by using a 90 mm stapler (GIA 90 PREMIUM™, Auto Suture™).

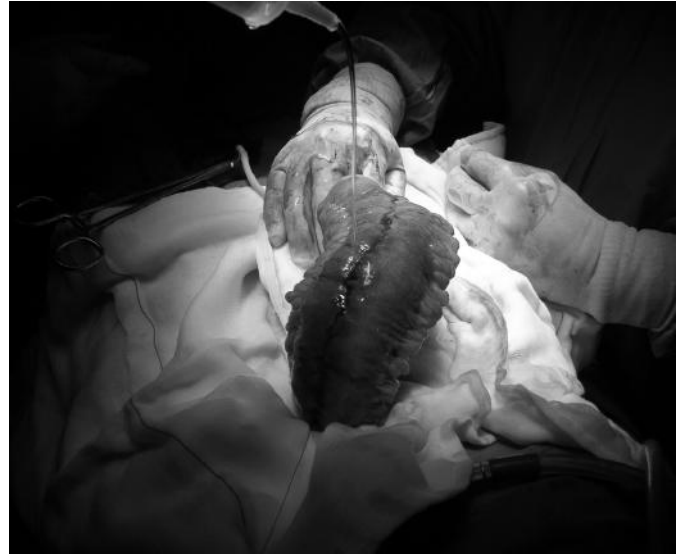


Fig. 2: Air leakage test to check the anterior aspect of the suture line.

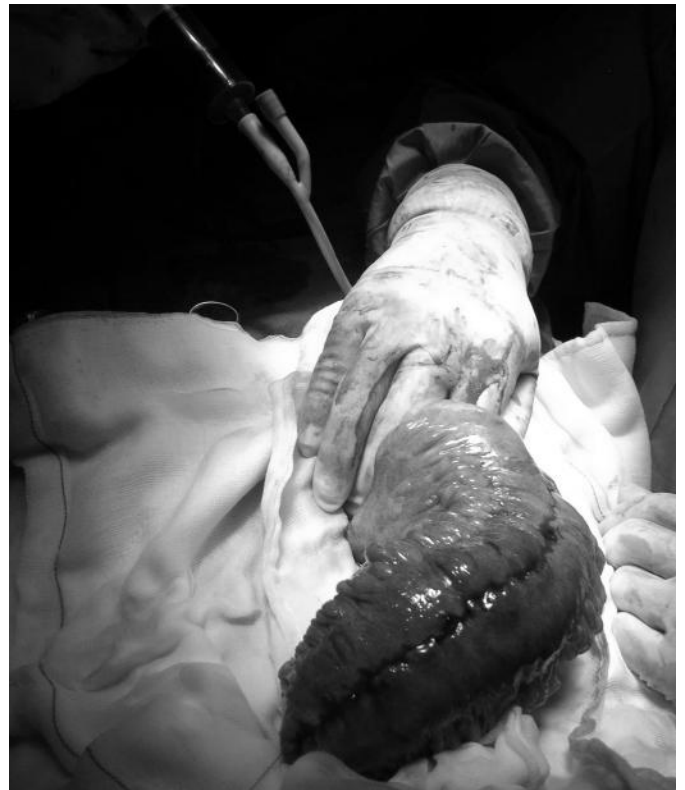

Fig. 3: Methylene blue infusion with a Foley catheter to test the posterior side of the suture line.

pouch. After firing, the anterior aspect of the staple line was carefully inspected and checked with air leakage test. Minor bleeding was controlled by electrocautery and reinforcement was achieved by siero-sierosal running suture (Fig. 2). Before closing the enterotomy a leakage test was performed using the infusion of methylene blue with a catheter (Fig. 3). A spilling of methylene blue was observed through the folded mesentery, detecting a posterior

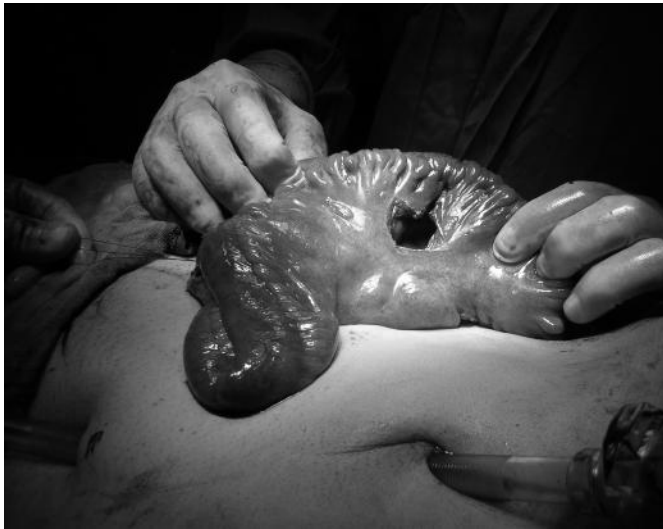

Fig. 4: Creation of a mesenteric window without compromising the vascular pedicles to the pouch limb.

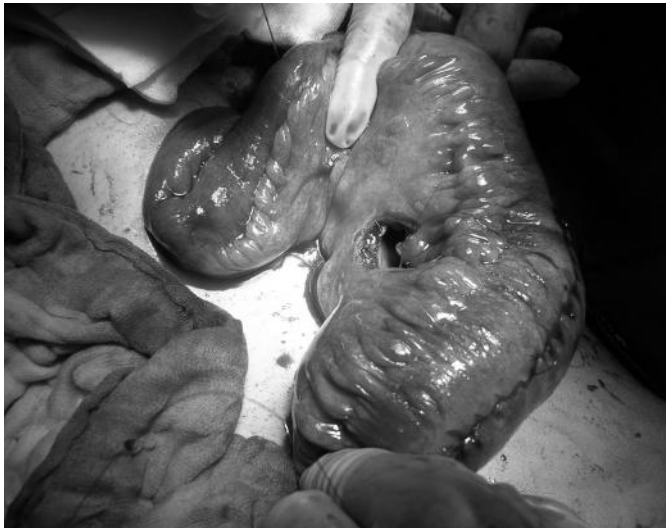


Fig. 5: Posterior side suture reinforcing through the mesenteric access.

side leak. The pouch was impossible to turn-over, so its repair was achieved by making a small section in the mesentery of about 3 cm of length and perpendicularly to the axis of the bowel (Fig. 4). The mesenteric opening, held divaricated by two small retractors, enabled the surgeon to see the defect that was reinforced with a continuous, inverting longitudinally suture (Fig. 5). A further leakage test was negative. The mesenteric defect was repaired and the strictureplasty was replaced in the abdominal cavity. The abdominal wound was then closed and the pneumoperitoneum re-established to inspect the operation field and check the haemostasis.

#### *Post-operative course*

The post-operative recovery was otherwise uneventful and the patient was discharged in good general condition on

the day four. At a recent follow-up visit, three months after the surgical procedure, the patient was symptom-free, not receiving any steroids, with no clinical or radiological evidence of recurrence of Crohn's disease.

#### **Discussion**

Anastomotic fashion is an important issue in the surgical management of Crohn's disease and the stapled side-to-side anastomosis is now gaining a great popularity<sup>1-7, 9, 10</sup>. The main advantage of this anastomosis is to provide a wide anastomotic lumen, with minimal contamination as well as it is easy and fast procedure. Side-to-side stapled anastomosis seems to substantially decrease anastomotic leak rates after ileo-caecal or ileo-colonic resection for Crohn's disease compared with hand-sewn end-to-end anastomosis<sup>6</sup>. Besides, according several Authors, the stapled side-to-side anastomosis is associated with a significantly lower incidence of post-operative complications, and early anastomotic recurrence is less common compared with conventional sutured end-to-end anastomosis<sup>2-10</sup>. This is probably related to a wider anastomosis that may delay the onset of symptomatic recurrence and may be associated with a lower early recurrence rate after ileo-colonic resection<sup>9,10</sup>. Concerning non-resective surgery, the most important prerogatives of the stapled side-to-side strictureplasty were described by Keighley in 1991: 1) the enterotomies are made at a site away from the ileal disease, 2) a wider enteroplasty is achieved, 3) the use of non absorbable material results in a lesser reaction in the tissues<sup>2</sup>. Prospective randomized trials would advocate to clearly prove the functional difference between the stapled and hand-sewn enteroplasty in the management of intestinal stricture caused by Crohn's disease.

The posterior side leak was successfully managed by the prompt identification and appropriate extracorporeal manoeuvres. The conversion to resection was carefully considered. However before starting with a resective act of about 30 cm of distal ileum we attempted an alternative method to repair the leakage and absolutely preserve this tract of bowel, as it has major implications for the absorption of bile salts and the fat-soluble vitamins A, D, E and K.

The creation of a mesenteric window was in our hands a good strategic tool to reach a difficult access place. It is mandatory to not damage the vascular pedicles to the pouch limb to avoid ischemia and, consequently, a forced resection.

#### **Riassunto**

La deiscenza anastomotica dopo confezionamento di stritturoplastica, in pazienti con morbo di Crohn può incrementare notevolmente la morbilità correlata all'inter-

vento chirurgico. La valutazione intra-operatoria dell'integrità della linea di sutura ed il trattamento adeguato di un'eventuale difetto sono d'importanza fondamentale per evitare complicanze nell'immediato post-operatorio. Una deiscenza della sutura, dopo esecuzione di una stritturoplastica latero-laterale con suturatrice meccanica, può essere identificata con il test dell'insufflazione o con blu di metilene. Quando il difetto è presente sul lato posteriore, può risultare molto difficile effettuare un'appropriata sutura riparatrice dato che il mesentere copre totalmente tale lato della sutura.

Abbiamo, pertanto, creato una finestra mesenterica, attraverso la quale è stato possibile riparare e rinforzare la linea di sutura in corrispondenza del margine posteriore, dopo stritturoplastica latero-laterale meccanica eseguita con modalità mini-invasiva. Grazie a questa strategia tecnica, è stato possibile evitare la resezione di un lungo tratto di ileo terminale.

## References

- 1) Hashemi M, Novell JR, Lewis AA: *Side-to-side stapled anastomosis may delay recurrence of Crohn's disease*. Dis Colon Rectum, 1998; 41(10):1293-296.
- 2) Keighley MR: *Stapled strictureplasty for Crohn's disease*. Dis Colon Rectum, 1991; 34:945-47.
- 3) Ikeuchi H, Kusunoki M, Yamamura T: *Long-term results of stapled and hand-sewn anastomosis in patients with Crohn's disease*. Dig Surg, 2000; 17(5):493-97.
- 4) Munoz-Juarez M, Yamamoto T, Wolff BG, Keighley MR: *Wide-lumen stapled anastomosis vs. conventional end-to-end anastomosis in the treatment of Crohn's disease*. Dis Colon Rectum, 2001; 44(1):20-26.
- 5) Resegotti A, Astegiano M, Farina EC, Ciccone G, Avagnina G, Giustetto A, Campa D, Fronda GR: *Side-to-side stapled anastomosis strongly reduces anastomotic leak rates in Crohn's disease surgery*. Dis Colon Rectum, 2005; 48(3):464-68.
- 6) Scarpa M, Angriman I, Barollo M, Polese L, Ruffolo C, Bertin M, D'Amico DF: *Role of stapled and hand-sewn anastomoses in recurrence of Crohn's disease*. Hepatogastroenterology, 2004; 51(58):1053-57.
- 7) Tersigni R, Alessandrini L, Barreca M, Piovanello P, Prantera C: *Does stapled functional end-to-end anastomosis affect recurrence of Crohn's disease after ileocolonic resection?* Hepatogastroenterology, 2003; 50(53):1422-425.
- 8) Tichansky D, Cagir B, Yoo E, Marcus SM, Fry RD: *Strictureplasty for Crohn's disease: meta-analysis*. Dis Colon Rectum, 2000; 43:911-19.
- 9) Yamamoto T, Bain IM, Mylonakis E, Allan RN, Keighley MR: *Stapled functional end-to-end anastomosis versus sutured end-to-end anastomosis after ileocolonic resection in Crohn's disease*. Scand J Gastroenterol, 1999; 34(7):708-13.
- 10) Yamamoto T, Allan RN, Keighley RM: *Strategy for surgical management of ileocolonic anastomotic recurrence in Crohn's disease*. World J Surg, 1999; 23:1055-61.