

Laparoscopic and mini-invasive surgery



Ann. Ital. Chir., 2012 83: 192-198

Raffaele Pugliese*, Dario Maggioni**, Andrea Costanzi**, Giovanni Ferrari*,
Monica Gualtierotti*

*Chirurgia Generale Oncologica e Mininvasiva, Ospedale Niguarda, Cà Granda, Milano, Italy

**Chirurgia Generale, Ospedale di Desio, Milano, Italy

Laparoscopic and mini-invasive surgery

BACKGROUND: *JGCA Gastric Cancer Treatment Guidelines (2004) include Laparoscopic Assisted Distal Gastrectomy (LADG) within the chapter of modified surgery. A metanalysis published in 2010 shows that LADG is significantly superior to Open Distal Gastrectomy (ODG) if comparing short term outcomes. Oncologic results prove to be comparable to ODG by one RCT and 2 retrospective studies. Little evidence is available on Laparoscopic Total Gastrectomy and concerns are raised about long-term oncologic outcomes.*

MATERIALS AND METHODS: *Laparoscopic Subtotal Gastrectomy is carried out with 4 to 5 ports in the periumbilical region (Hasson trocar for laparoscope) and upper quadrants. After exploration of the abdominal cavity surgical steps include coloepiploic detachment, omentectomy, dissection of the gastrocolic ligament, division of the left gastroepiploic vessels, division of right gastroepiploic vessels, division of pyloric vessels. The duodenum is transected with a linear stapler. Incision of the lesser omentum and dissection of the hepatoduodenal ligament allows completion of D2 lymphadenectomy. The 4/5ths of the stomach are transected starting from the greater curve at the junction of left and right gastroepiploic arcades by linear stapler. Roux-en-Y loop reconstruction is performed through a stapled side-to-side gastro-jejunal anastomosis and a side-to-side jejuno-jejunal anastomosis. Reconstruction after Laparoscopic Total Gastrectomy is performed preferably by a side-to-side esophago-jejunal anastomosis according to Orringer.*

DISCUSSION AND CONCLUSION: *A robotic assisted approach adds precision on lymphadenectomy and reconstructive techniques.*

KEY WORDS: Gastric cancer, Laparoscopic Total Gastrectomy, Robotics

History of laparoscopic gastric surgery and literature review

The official history of laparoscopic gastric surgery begins in 1991 with the first Laparoscopic-Assisted Distal Gastrectomy (LADG) according to Billroth I for Early Gastric Cancer (EGC) carried out by Kitano ¹. In 1992,

Goh in Singapore, reported the first entirely laparoscopic Billroth II distal gastrectomy on a patient affected by chronic gastric ulcer unresponsive to medical treatment ². In 1999 Azagra in Belgium performed the first Laparoscopic-Assisted Total Gastrectomy (LATG) for EGC ³. Simultaneously Uyama reported the first LATG with D2 lymphadenectomy in 2 cases of Advanced Gastric Cancer (AGC) ⁴. In Japan and Korea thanks to the modern diagnostic techniques, the incidence of EGC has increased up to 50% of the total incidence of gastric cancer ⁵. The goal of tumor treatment is no longer its radicality of cure only, but also minimally invasiveness. In 2007 according to the Japan Society for Endoscopic Surgery, in Japan 4.000 LADG have been carried out. Only in 20% of these procedures a D2 lymphadenectomy has been performed ⁶. Patients affected by EGC would mostly benefit of the minimally-invasive

Correspondence to: Andrea Costanzi, AIMS Academy faculty member, Ospedale Niguarda - Cà Granda, 20100 Milano (e-mail:Andrea.Costanzi@OspedaleNiguarda.it)

approach. LADG is considered acceptable for EGC stage Ia and Ib (respectively T1mN0 and T1smN0) but also for AGC T2N0 within the frame of approved clinical studies⁷.

According to the American National Comprehensive Cancer Network Guidelines of 2010 “the role of laparoscopic resection in gastric cancer requires further investigation in large randomised clinical trials”⁸.

Several studies reported that LADG is a safe minimally invasive procedure offering a more prompt recovery as compared to “open” surgery, less blood loss, shorter hospital stay, less pain, and lower risk of complications⁹⁻¹². Some RCTs already proved its feasibility.

The most recent meta-analysis published by Kodera in 2010 has confronted the only 6 RCTs published from 2000 on, for a total of 343 laparoscopic cases and 323 “open” cases. The main contribution to meta-analysis by Kodera has been offered by the KLASS RCT published by Korean surgeon Kim in 2010 (176 LADG versus 162 ODG). The meta-analysis is able to confront blood loss and complications, significantly in favour of laparoscopy, length of the procedure and removed lymphnodes, significantly in favour of the “open procedure”. Mortality at 30 days from surgery (3 deaths in the laparoscopic group versus 2 deaths in the “open” group) does not show any statistical difference⁹.

There was no significant difference in the 5-year survival rate between LADG and ODG in one RCT¹⁷ and two retrospective studies [18,19] showing similar oncologic outcomes, as we await for the Japanese and Korean results. Our retrospective experience also compares with available data for open surgery²⁰.

Reconstruction after LADG for EGC is open to different solutions including Billroth I and II often preferred, in the large case series published in Japan and Korea, to the Roux-en-Y gastro-jejunal anastomosis²¹⁻²⁴.

A minilaparotomy of 5 cm is described for the fashioning of extra-corporeal anastomosis²⁴. Today, the concept of Totally Laparoscopic Gastrectomy without a minilaparotomy is becoming popular. The anastomosis can be fashioned intracorporeally and the specimen extraction is obtained through a U-shaped enlargement of the periumbelical incision^{25,26}.

A different concern has to be expressed about Laparoscopic-Assisted Total Gastrectomy (LATG). Few studies are available on the outcomes of LATG with D2 lymphadenectomy for gastric cancer because of technical difficulty in completing the procedures and concerns about long-term oncologic outcomes. However a number of small series advocating LATG for gastric cancer have appeared in the literature^{27,28}. In a retrospective multicenter study by Kitano including 1294 patients with EGC, 55 LATG with D1-D2 lymphadenectomy were performed with good short-and long-term outcomes.

Our technique for laparoscopic total gastrectomy complies with the previously described indications for EGC

of the proximal or middle portion of the stomach and a modified D2 lymphnode dissection (Tiers n. 7, 8a and 9, 11, 12a in cancer of the middle third).

According to Pigazzi the OrVIL system and bariatric experience have simplified the performance of a gastro-jejunal anastomosis. In a series of 16 patients he reported 0 conversions, 0 fistulae and 3 anastomotic stenosis²⁹. In a series by Uyama published in 2009, he describes 55 LATG with D2 lymphadenectomy²⁷. In 24 cases staged T1 or T2 without the involvement of the greater curvature, the splenic hilum lymphadenectomy is not described. In 31 cases staged T2,T3,T4 a splenectomy was performed, in 3 cases together with a distal pancreatectomy. According to the author the 0 mortality and low morbidity make LATG with D2 lymphadenectomy a safe procedure in expert hands. However the issue of splenic hilum lymphadenectomy is not resolved.

The application of LATG with D2 lymphadenectomy for gastric cancer raises 2 problems: whether to perform a concomitant splenectomy to completely retrieve station 10 lymph nodes and how to achieve an intracorporeal anastomosis, the former still being a matter of debate for open surgery, the latter being open to different solutions and yet no standardization^{3,4,18-20}.

Although the intracorporeal esophago-jejunal anastomosis, being still difficult to standardize and the object of different solutions, is the main obstacle to the diffusion of the procedure, the feasibility of LATG has been proven and short term outcomes are good^{3,4,30,31}.

Personal experience

From June 2000 to December 2010, 76 patients affected by gastric Adenocarcinoma (39 EGC, 37 AGC) of the inferior 1/3rd of the stomach and 7 patients with EGC of the superior and middle 1/3rd of the stomach underwent gastric laparoscopic surgery in 56 cases, robot-assisted in 27 cases for a total of 76 LADG and 7 LATG. The procedure requires a subtotal gastrectomy with D2 lymphadenectomy in the case of tumors of the distal 1/3rd of the stomach and a total gastrectomy with D1+, lymphadenectomy for EGC of the superior and middle 1/3 rd of the stomach.

Surgical technique: Sub-Total Gastrectomy and D2 lymphadenectomy

The patient is placed under G.A. in lithotomy position with 20° head-up tilt (reverse Trendelenburg's position), legs parted, left arm abducted.

A central venous line, a nasogastric tube and a urinary catheter are inserted.

The operating surgeon fits between the patient's legs, the camera holder surgeon stands at the operating surgeon's

left side and a second assistant at his right side. The monitor is placed at the right of the patient's head, a second monitor is useful on the left side.

CO₂ pneumoperitoneum is induced at 12 mm Hg through a 12-mm right peri-umbilical port for open laparoscopy (T1 in Fig. 1). Three more 10-12 mm trocars are then inserted in a semicircular shape, in the left (T2) and right (T3) upper quadrants on the midclavicular line 3 cm above the transumbilical line and in the right subcostal space (T4) for liver retraction through a fan-type foldable retractor. One optional 5 mm trocar for retraction is inserted in the left hypocondrium (T5). A 30° HD laparoscope is used through the umbilical port.

All dissecting maneuvers are conducted by ultrasonic scalpel with a 5 mm shaft (Harmonic Ace, Ethicon Endo-Surgery, Cincinnati, OH).

Organ retraction is carried out by means of 10 mm shaft

Babcock forceps and 5 mm-shaft Johann forceps.

A liver retractor is inserted through the right hypocondrium port (fan-type foldable retractor).

Additional laparoscopic instruments required are bipolar forceps, needle-holders, suction-irrigation cannula, endoscopic linear stapler and clip applicator.

The procedure begins with an exploration of the abdominal cavity: once it has been found free of metastatic disease, the first surgical steps are coloepiploic detachment and omentectomy, followed by dissection of the gastrocolic ligament. The left gastroepiploic vessels are divided. All these maneuvers are performed by means of ultrasonic shears.

Entering the lesser sac allows sectioning of adhesions between the pancreas and the posterior wall of the stomach.

After lowering the right colonic flexure and exposing the anterior surface of the duodenum and of the pancreat-

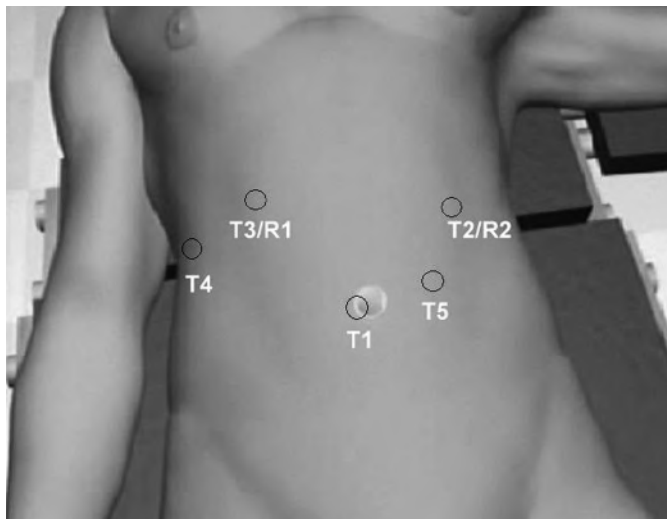


Fig. 1: Trocar placement. In red laparoscopic trocars (T1 to T4, T5 optional). In robotic surgery, besides T1, T2 and T3, 2 robotic trocars are placed above (R1, R2).

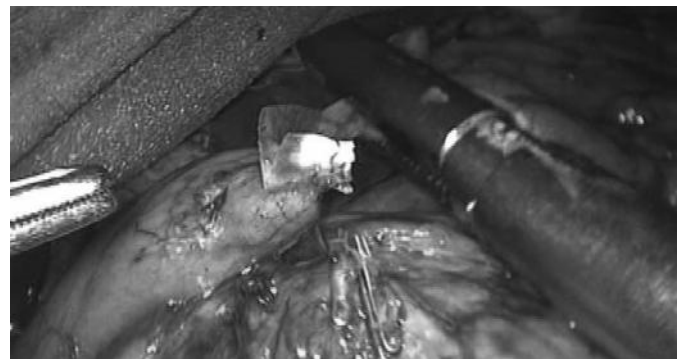

Fig. 3: Duodenal section with endoliner stapler 45 mm.

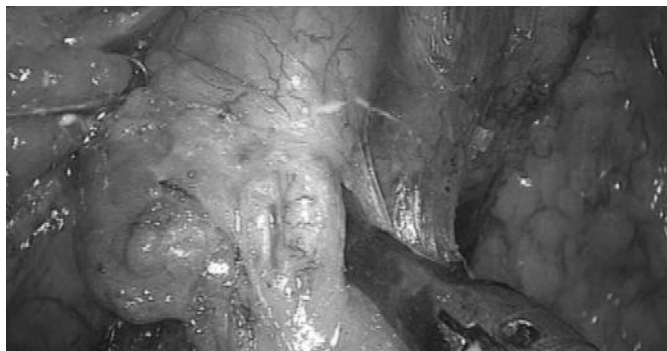

Fig. 2: Isolation of gastro-epiploic artery.

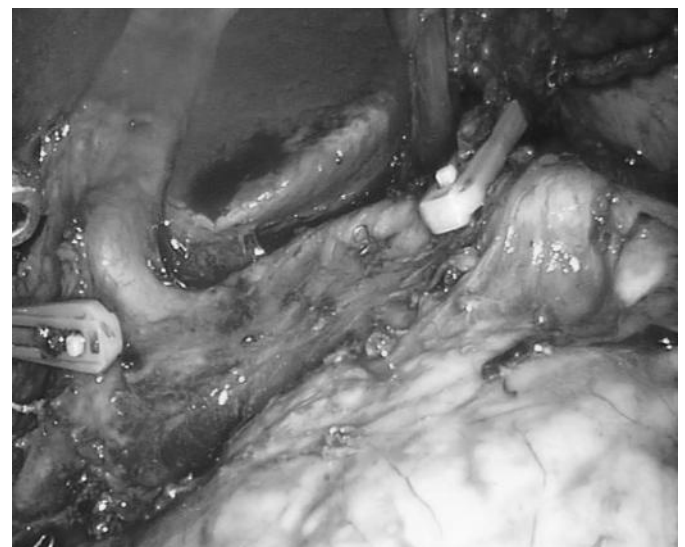


Fig. 4: The coeliac region after lymphadenectomy of tiers n. 7,8,9 and section of Right and Left Gastric Arteries (clips).

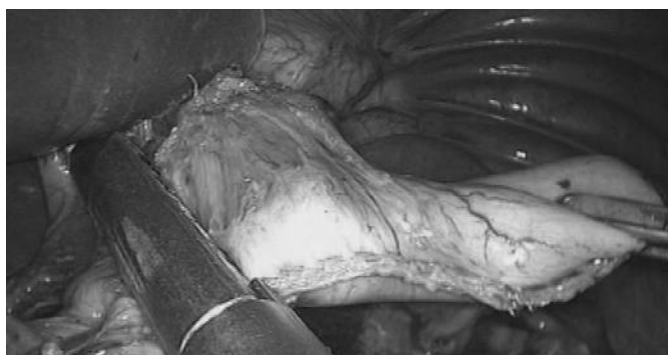

Fig. 5: Subtotal resection of the 4/5ths of the stomach.



Fig. 6: Side-to-side Gastro-jejunal stapled anastomosis.

ic head, the Henle trunk is identified and the affluent right gastroepiploic vessels are isolated (Fig. 2) and divided separately between absorbable clips. This allows to clear tiers n.6 and 14v.

The right gastroepiploic artery is sectioned at its origin from the gastroduodenal artery, just above the pancreatic head.

By following the hepatic artery and the gastro-duodenal artery the right gastric arcade is identified and divided. The pyloric vessels are sectioned, the pylorus is freed, and tier 5 is resected.

The duodenum is transected (Fig. 3) with a 45-mm cartridge linear stapler (blue reloads, with triple-staggered rows of staples reinforced by a bioabsorbable polycarbonate membrane (Seamguard, W. L. Gore & Associates); as an alternative it is advisable to oversee the staple line ³².

The stomach can now be lifted in the left hypocondrium and the patient is rotated on his left side in order to facilitate lymphadenectomy.

The lesser omentum is incised, the hepatoduodenal ligament is cleared from tier n.12a, followed by ablation of tiers n. 8, common hepatic artery, n. 9, celiac axis, and n. 11p, proximal splenic artery (Fig. 4). The left gastric artery is sectioned by linear endostapler or between clips with removal of tier n. 7 (left gastric artery). Lifting of the gastric remnant allows excision of perigastric lymphnodes along the lesser curvature (tier n. 3) up to the esophago-gastric region (tier n. 1) and completion of lymphadenectomy.

The 4/5ths of the stomach are transected (Fig. 5) starting from the greater curve at the junction of left and right gastro-epiploic arcades (Van Goethem's point) by a 45-mm linear stapler (3 to 5 blue reloads). The specimen is collected into an endo bag, and temporarily left on the liver surface.

The second jejunal loop is chosen to prepare a 70 cm Roux-en-Y transmesocolic loop. The gastric remnant is set close to the jejunal loop and two openings are created through which a 45-mm cartridge stapler is inserted to fashion a side-to-side gastro-jejunal anastomosis

(Fig. 6). Suture of the openings by running suture closes the access to the gastric stump and jejunal limb. The side-to-side jejunojejunal anastomosis at the foot of the Roux-en-Y loop is created with a 45-mm endostapler. The endobag containing the specimen is retrieved through the umbilical port. Minimal enlargement of the incision (3 to 4 cm) may be necessary in some instances. A drain, inserted through the right trocar, is placed near the duodenal stump. Closure of port incisions ends the procedure.

Laparoscopic-assisted total gastrectomy (LATG)

Patient's placement and first steps of gastric dissection and closure of the duodenal stump are carried out as described in LSG. The extent of lymphadenectomy for proximal tumors corresponds to a D2 clearance including the anterior aspect of the splenic hylum. Dissection of the gastrocolic ligament is wider than in LSG. Short gastric vessels are divided with the ultrasound scalpel, and dissection proceeds to the diaphragmatic crus, dividing the phreno-esophageal membrane and vagal nerves. Group 2 (left paracardial) is resected. The esophagus is transected by an EndoGIA 45 linear stapler, blue reload, and the whole stomach is inserted into an endobag and temporarily left on the liver surface.

Reconstruction of digestive continuity is carried out by means of a side-to-side esophago-jejunal anastomosis according to Orringer on a Roux-en-Y transmesocolic loop ²².

The second jejunal loop is transected with linear stapler (white vascular cartridge).

An opening in the transverse mesocolon is created by harmonic scalpel.

The second jejunal loop and the esophageal stump are prepared and opened on the antimesenteric side of the jejunal loop at about 5 cm from its distal margin and on the esophageal posterior wall. The 45 mm linear stapler is introduced through the left trocar usually loaded with a blue cartridge and inserted first into the

jejunal opening and secondly in the esophageal one. No suspension sutures are used between the esophagus and the jejunum in order to gain freedom of movements. A side-to-side esophagojejunal anastomosis according to Orringer is then created by firing the linear stapler and its patency is verified. A naso-jejunal tube is delicately passed through the anastomosis. The opening is closed by a double layer of 3/0 running suture.

The jejuno-jejunal side-to-side stapled anastomosis at the foot (70 cm) of the anastomotic loop as previously described accomplishes the Roux-en-Y restoration of the digestive tract. Minimal enlargement of the umbilical incision is needed to withdraw the bag containing the specimen. A drain is placed in Morrison's pouch near the duodenal stump. Closure of the port incisions ends the operation.

Anastomotic options

In 1999 Azagra described a conventional anastomosis by circular stapler³. A large umbilical port (33 mm) is placed to allow the passage of the 25 mm anvil. An incision is made in the anterior wall of the distal esophagus, a purse string suture is performed and the anvil is slipped through it into the esophageal lumen with the aid of Babcock grasping forceps prior to esophageal distal transection. The shaft of the circular stapler is then introduced into the afferent jejunal loop by its antimesenteric border through an enlargement of the left upper quadrant port by placing a wound protector or into the 33-mm trocar cannula. The shaft is clinched to the anvil, the stapler is fired, and an end-to-side esophago-jejunal anastomosis is created. The jejunal stump is closed by a 45-mm endoscopic linear stapler, and the anastomosis is checked with methylene blue instilled through the nasogastric tube. Hand-Assisted Laparoscopic Total Gastrectomy simplifies the technique by performing the anastomosis through a *hand port*.^{23,24}

The OrVil™ system (Covidien Surgical) is a ready-to-use anvil delivery device, which is designed to transorally insert the anvil into the abdominal esophagus, similar to inserting the orogastric tube through the mouth. In the OrVil system, the orogastric tube is connected to the center rod of the anvil, so that the anvil is transorally delivered into the esophagus, guided by the orogastric tube. The orogastric tube is easily removed from the anvil by cutting the connecting thread. The tilted anvil head of the OrVil™ system facilitates the passage of the anvil through the mouth and upper esophagus, and automatically untilts for parallel closure when combined with a stapler. Intracorporeal laparoscopic double-stapling esophago-jejunostomy is performed using a 25 mm circular stapler, which can be combined with the OrVil™ system²⁵.

Robotic-Assisted minimally invasive gastric cancer surgery

Even if widely accepted laparoscopic surgery is associated to several limitations and disadvantages such as limited range of instrument movement, amplification of hand tremor, two-dimensional imaging, and unnatural positions for the surgeons. Robotic surgery performed through a remote console controlling a robotic cart (Robotic Surgical System, da Vinci® Intuitive Surgical, Mountain View, CA, USA) is superior to conventional laparoscopic surgery according to several investigators in that, it has a tremor filter, can scale motions, has three-dimensional imaging, and offers a stable operative platform and improved dexterity with an internal articulated EndoWrist® that allows seven degrees of freedom. These characteristics are especially important when precise lymph node dissection is required for gastric cancer³⁷⁻³⁹. Nevertheless, robotic gastrectomy has some disadvantages including a smaller field of view compared with the laparoscopic view, longer operative times and higher costs.

Robotic Set Up

Robot and optic system are setup by the first assistant, who works between the patient's lower limbs. Electric cables connect the robotic system to the surgeon's console. After a self-test the arms of the EndoWrist® are wrapped with covers and fixed by supports. A 3D high-resolution image is selected and a 12 mm cannula is inserted in the periumbelical trocar for open laparoscopy and optic binocular endoscope.

The pneumoperitoneum is instituted at 12 mm Hg (T1 in Fig. 1). Two robotic trocars of 7/8 mm are inserted bilaterally in the subcostal space on the anterior axillary line (R1 and R2). Then, two trocars of 10/12 mm are inserted in the upper quadrants, below the robotic ports, the right one at the midclavicular line for liver retraction and the left one between the camera port and the left robotic port for additional retraction and insertion of endostaplers or clip applicators (T2 and T3). This additional port must be placed at least 3 cm away from the robotic port to avoid fighting. After port placement, the robotic cart is installed from the patient's head.

Robot-Assisted LADG

The first steps are carried out under conventional laparoscopy: omentectomy, coloepiploic detachment, opening of the lesser sac, gastroduodenal dissection and ablation of inphrapyloric nodes (tiers 4 and 6).

Then, the second jejunal loop is prepared to fashion a side-to-side stapled anastomosis at the foot of the Roux en-Y loop.

At this point the robotic system is installed and lymphadenectomy begins on the anterior aspect of the hepatoduodenal ligament (tier n. 12a). Once the Right Gastric Artery is divided, the suprapyloric nodes are removed (tier n. 5). The assistant retracts the stomach, applies clips and operates the stapler to transect the duodenum.

Lymphadenectomy is completed by ablation of tiers n. 8, 9, 11p followed by division of the Left Gastric Artery with removal of tiers n. 7 and tiers n. 1, 3 and 5 along the lesser curvature. The stomach is transected by linear stapler to obtain a 4/5th gastrectomy leaving temporarily the specimen on the liver surface. A 70 cm Roux-en-Y jejunal limb is chosen for restoration of the digestive tract. A transmesocolic gastro-jejunal anastomosis is fashioned with a linear cutting stapler on the posterior wall of the gastric stump. The access openings are closed by robotic running suture.

Robot-assisted LTG

In case of robot-assisted LTG the dissection approaches the diaphragmatic crus with division of the phrenoesophageal membrane, resection of tiers n. 1, 2 and division of vagal nerves. Thanks to robotic dexterity as an alternative to Orringer's anastomosis it is possible to perform an hand-sewn purse string suture on the esophagus and complete an end-to-side oesophago-jejunal anastomosis with the circular stapler as previously described.

Riassunto

Le linee guida della Japanese Gastric Cancer Association (JGCA) del 2004 sul trattamento del cancro gastrico fanno rientrare la gastrectomia distale laparoscopica (LADG) nel capitolo della chirurgia modificata. Una metanalisi pubblicata nel 2010 dimostra che la LADG è significativamente superiore alla Gastrectomia distale "open" (ODG) se si confrontano i risultati a breve termine. Uno studio randomizzato e due studi retrospettivi riportano risultati oncologici paragonabili tra LADG e ODG. Pochi dati sono disponibili sulla Gastrectomia totale laparoscopica e le preoccupazioni sono sollevate in merito ai risultati oncologici a lungo termine.

La LADG viene eseguita mediante 4 o 5 trocar nella regione periombelica (tre quarti Hasson per il laparoscopia) e nei quadranti superiori. Dopo l'esplorazione della cavità addominale le fasi chirurgiche includono lo scollamento coloepiploico, la omentectomia, la dissezione del legamento gastrocolico, la sezione dei vasi gastroepiploici di sinistra e di destra, la sezione dei vasi pilorici. Il duodeno è sezionato con una suturatrice lineare. L'incisione del piccolo omento e la dissezione del legamento epatoduodenale consente il completamento della linfadenectomia D2. I 4/5 dello stomaco sono sezionati

a partire dalla grande curva a livello della giunzione tra i vasi gastroepiploici di destra e sinistra mediante suturatrice lineare. La ricostruzione Roux-en-Y viene eseguita mediante un'anastomosi gastro-digiunale latero-laterale ed un'anastomosi digiuno-digiunale latero-laterale. La ricostruzione dopo Gastrectomia totale laparoscopica è seguita preferibilmente da una anastomosi esofago-digiunale latero-laterale secondo Orringer.

Un approccio robotico aggiunge precisione alla linfadenectomia ed alle tecniche ricostruttive.

References

1. Kitano S, Iso Y, Moriyama M, Sugimachi K: *Laparoscopy-assisted Billroth I gastrectomy*. Surg Laparosc Endosc, 1994; 4:146-48.
2. Goh PMY, Tekant Y, Kum CK, et al.: *Totally intra-abdominal laparoscopic Billroth II gastrectomy*. Surg Endosc, 1992; 6:160.
3. Azagra JS, Goergen M, De Simone P, Ibañez-Aguirre: *Minimally invasive surgery for gastric cancer*. Surg Endosc, 1999; 13:351-57.
4. Uyama I, Sugioka A, Fujita J, et al.: *Laparoscopic total gastrectomy with distal pancreatectomy and D2 lymphadenectomy for advanced gastric cancer*. Gastric Cancer, 1999; 2:230-34.
5. Kim H, Hyung W, Cho G, et al.: *Morbidity and mortality of laparoscopic gastrectomy versus open gastrectomy for gastric cancer: An interim report. A phase III multicenter, prospective, randomized trial (KLASS Trial)*. Ann Surg, 2010; 251:41-20.
6. Kodera Y, Fujiwara M, Ohashi N, Nakayama G, Koike, M, Morita S, Nakao A: *Laparoscopic Surgery for Gastric Cancer: A Collective Review with Meta-Analysis of Randomized Trials*. J Am Coll Surg, 2010; 211(5):677-86.
7. Japanese Gastric Cancer Society: *Guidelines for Diagnosis and Treatment of Carcinoma of the Stomach*. April 2004 edition. http://www.jgca.jp/PDFfiles/Guidelines2004_eng.pdf. J Robotic Surg, 2008; 2:217-22.
8. National Comprehensive Cancer Network: *Clinical Practice Guidelines in Oncology. Gastric Cancer*. V. 2. 2010. http://www.nccn.org/professionals/physician_gls/PDF/gastric.pdf.
9. Goh PM, Khan AZ, So JB, et al.: *Early experience with laparoscopic radical gastrectomy for advanced gastric cancer*. Surg Laparosc Endosc Percutan Tech, 2001; 11:83.
10. Adachi Y, Suematsu T, Shiraishi N, et al.: *Quality of life after laparoscopy-assisted Billroth I gastrectomy*. Ann Surg, 1999; 229:49.
11. Kitano S, Adachi Y, Shiraishi N, et al.: *Laparoscopic-assisted proximal gastrectomy for early gastric carcinomas*. Surg Today 1999; 29:389.
12. Dulucq JL, Wintringer P, Stabilini C, et al.: *Laparoscopic and open gastric resections for malignant lesions: A prospective comparative study*. Surg Endosc, 2005; 19:933.
13. Ohtani H, Tamamori Y, Noguchi K, Azuma T, Fujimoto S, Oba H, Aoki T, Minami M, Hirakawa K: *Meta-Analysis of laparoscopy-assisted and open distal gastrectomy for gastric cancer*. J Surg Res, 2010.
14. Kitano S, Shiraishi N, Uyama I, Sugihara K, Tanigawa N: *Japanese Laparoscopic Surgery Study Group: A multicenter study on*

- oncologic outcome of laparoscopic gastrectomy for early cancer in Japan. *Ann Surg*, 2007; 245(1):68-72.
15. Fujiwara M, Kodera Y, Kasai Y, et al.: *Laparoscopy-assisted distal gastrectomy with systemic lymph node dissection for early gastric carcinoma: A review of 43 cases*. *J Am Coll Surg*, 2003; 196:75.
16. Kurokawa Y, Katai H, Fukuda H, et al.: *Gastric Cancer Surgical Study Group of the Japan Clinical Oncology Group. Phase II study of laparoscopy-assisted distal gastrectomy with nodal dissection for clinical stage I gastric cancer: Japan Clinical Oncology Group Study JCOG0703*. *Jpn J Clin Oncol*, 2008; 38:501.
17. Huscher CG, Mingoli A, Sgarzini G, et al.: *Laparoscopic versus open subtotal gastrectomy for distal gastric cancer: Five-year results of a randomized prospective trial*. *Ann Surg*, 2005; 241:232.
18. Mochiki E, Kamiyama Y, Aihara R, et al.: *Laparoscopic assisted distal gastrectomy for early gastric cancer: Five years' experience*. *Surgery*, 2005; 137:317.
19. Lee JH, Yom CK, Han HS: *Comparison of long-term outcomes of laparoscopy-assisted and open distal gastrectomy for early gastric cancer*. *Surg Endosc*, 2009; 23:1759.
20. Pugliese R, Maggioni D, Sansonna F, Costanzi A, et al.: *Subtotal gastrectomy with D2 dissection by minimally invasive surgery for distal adenocarcinoma of the stomach: Results and 5-year survival*. *Surg Endosc*, 2010; 24(10):2594-602.
21. Tanimura S, Higashino M, Fukunaga Y, et al.: *Laparoscopic gastrectomy for gastric cancer: Experience with more than 600 cases*. *Surg Endosc*, 2008; 22:1161-164.
22. Adachi Y, Shiraishi N, Shiromizu A, Bandoh T, Aramaki M, Kitano S: *Laparoscopy-assisted Billroth I gastrectomy compared with conventional open gastrectomy*. *Arch Surg*, 2000; 135:806-10.
23. Hyung WJ, Song C, Cheong JH, Choi SH, Noh SH: *Factors influencing operation time of laparoscopy-assisted distal subtotal gastrectomy: Analysis of consecutive 100 initial cases*. *Eur J Surg*, 2007; *Oncol* 33(3):314-19.
24. Ikeda O, Sakaguchi Y, Aoki Y, et al.: *Advantages of totally laparoscopic distal gastrectomy over laparoscopically assisted distal gastrectomy for gastric cancer*. *Surg Endosc*, 2009; 23:2374-379.
25. Takiguchi S, Sekimoto M, Miyake Y, et al.: *Totally laparoscopic distal gastrectomy using the hand-sewn Billroth-I anastomotic technique: Report of a case*. *Surg Today*, 2003; 33:371-74.
26. Kim J, Song K, Chin H, et al.: *Totally laparoscopic gastrectomy with various types of intracorporeal anastomosis using laparoscopic linear staplers: preliminary experience*. *Surg Endosc*, 2008; 22:436-42.
27. Shinoara T, Kanaya S, Taniguchi K, Fujita T, Yanaga K, Uyama I: *Laparoscopic total gastrectomy with D2 lymph node dissection for gastric cancer*. *Arch Surg*, 2009; 144(12):1138-142.
28. Sakuramoto S, Kikuchi S, Futawatari N, Katada N, Moriya H, Hirai K, Yamashita K, Watanabe M: *Laparoscopy-assisted pancreas- and spleen-preserving total gastrectomy for gastric cancer as compared with open total gastrectomy*. *Surg Endosc*, 2009; 23:2416-423.
29. Kachikwu EL, Trisal V, Kim J, Pigazzi A, Ellenhorn JDI: *Minimally Invasive Total Gastrectomy for Gastric Cancer: A Pilot Series*. *J Gastrointest Surg*, 2011; 15:81-86.
30. Okabe H, Obama K, Tanaka E: *Intracorporeal esophagojejunal anastomosis after laparoscopic total gastrectomy for patients with gastric cancer*. *Surg Endosc*, 2009; 23:2167-171.
31. Kim SG, Lee YJ, Ha WS, Jung EJ, Ju YT, Jeong CY, Hong SC, Choi SK, Park ST, Bae K: *LATG with extracorporeal esophagojejunostomy: is this minimal invasive surgery for gastric cancer?* *J Laparoendosc Adv Surg Tech A*, 2008; 18(4):572-78.
32. Pugliese R, Maggioni D, Sansonna F, Ferrari GC, Di Lernia S, Forgione A, Magistro C: *Efficacy and effectiveness of suture bolster with Seamguard*. *Surg Endosc*, 2009; 23(6):1415-416.
33. Orringer MB, Marshall B, Iannettoni MD: *Eliminating the cervical esophagogastric anastomotic leak with a side-to-side stapled anastomosis*. *J Thorac Cardiovasc Surg*, 2000; 119:277-88.
34. Chau CH, Siu WT, Li MK: *Hand-assisted D2 subtotal gastrectomy for carcinoma of stomach*. *Surg Laparosc Endosc Percutan Tech*, 2002; 12:268-72.
35. Usui S, Ito K, Hiranuma S, Takiguchi N, Matsumoto A, Iwai T: *Hand-assisted laparoscopic esophagojejunostomy using newly developed purse-string suture instrument "Endo-PSI"*. *Surg Laparosc Endosc Percutan Tech*, 2007; 17:107-10.
36. Jeong O, Park YK: *Intracorporeal circular stapling esophagojejunostomy using the transorally inserted anvil (OrViI) after laparoscopic total gastrectomy*. *Surg Endosc*, 2009; 23(11):2624-630.
37. Kim MC, Heo GU, Jung GJ: *Robotic gastrectomy for gastric cancer: Surgical techniques and clinical merits*. *Surg Endosc*, 2010; 24(3):610-15.
38. Song J, Oh SJ, Kang WH, Hyung WJ, Choi SH, Noh SH: *Robot-assisted gastrectomy with lymph node dissection for gastric cancer: Lessons learned from an initial 100 consecutive procedures*. *Ann Surg*, 2009; 249(6):927-32.
39. Pugliese R, Maggioni D, Sansonna F, Ferrari GC, Di Lernia S, Magistro C, Pauna I, Forgione A, Costanzi A, Pugliese F: *Robot-assisted laparoscopic gastrectomy with D2 dissection for adenocarcinoma: Initial experience with 17 patients*. *J Robotic Surg*, 2008; 2:217-22.