

# Unusual location of hydatid cyst: the posterior leaflet of tricuspid valve



*Ann. Ital. Chir.*, 2010; 81: 211-214

Adnan Taner Kurdal, Nail Kahraman, Ihsan Iskesen, Bekir Hayrettin Sirin

*Department of Cardiovascular Surgery  
Celal Bayar Univ. School of Medicine, Manisa Turkey*

## Unusual location of hydatid cyst: the posterior leaflet of tricuspid valve

*Hydatid Cyst disease involves the heart in 0.02-2% of the cases. It can appear with symptoms very similar to coronary artery disease, cardiac valvular disease and pericarditis.*

*We present a case of hydatid cyst that was located on the posterior tricuspid leaflet and that caused tricuspid regurgitation in 37 year old female patient who has gone through hydatid cyst excision from the bilateral lungs with median sternotomy 2 years ago. In addition to the right atrial and ventricular dilatation, second degree tricuspid regurgitation and significant pulmonary hypertension was found. The 2x2 cm smooth surfaced mass was resected from the posterior leaflet of the tricuspid valve and the defect was closed with suture with the aid of cardiopulmonary bypass. The patient followed with long term albendazole treatment.*

*Cardiac echinococcosis should be kept in mind in some patients throughout their life with a history of previous hydatid cyst disease. Surgical excision without rupture is the treatment of choice for cardiac hydatid cyst, with following medical therapy in order to prevent recurrence.*

KEY WORDS: Cardiac Hydatid Cyst, Tricuspid valve.

## Introduction

Hydatid Cyst disease is an endemic disease seen in Southern Europa, South America, Africa and Turkey. It mostly involves liver (55-70%) and lungs (18-35%). The involvement of the both organs is seen in %5-13 of the cases and the involvement of the heart is rare (0.02-2%). The cyst can grow into the myocardium very slowly and may remain asymptomatic for a long time. The early diagnosis of cardiac hydatid cyst is difficult because of

the long time between the initial infection and the appearance of cardiac symptoms<sup>1-4</sup>. This case is presented because of unusual localization and rapid development of symptoms.

## Case report

37 year old female patient applied to our hospital with symptoms of increasing dyspnea, weakness, tachycardia, fatigue and palpitation for the last 2 weeks with sudden onset. There was a significant history of a bilateral cystectomy for hydatid cyst disease of the lungs performed with median sternotomy 2 years ago. Physical examination showed that median sternotomy scar related to the previous surgery, bilateral pretibial oedema and hepatomegaly. 3/6 holosystolic murmur was heard at the inferior sternal region and the patient was considered as

*Pervenuto in Redazione Aprile 2010. Accettato per la pubblicazione Maggio 2010.*

*For correspondence: Dr. Ihsan Iskesen Celal Bayar Universitesi Tip Fakultesi Kalp Damar Cerrahisi ABD. Manisa Turkey (e-mail:iskesen@yahoo.com).*

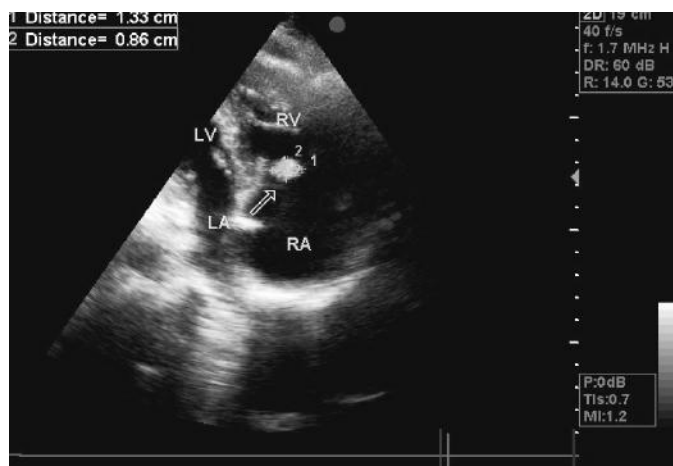


Fig. 1: Ecocardiographic view of the mass on the tricuspid valve.

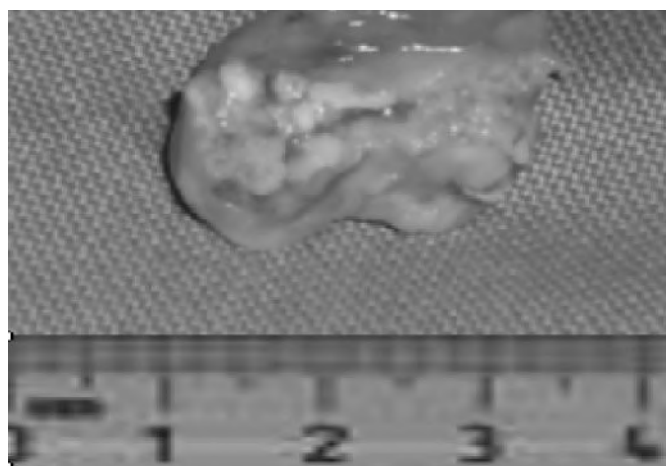


Fig. 3: Resected mass.

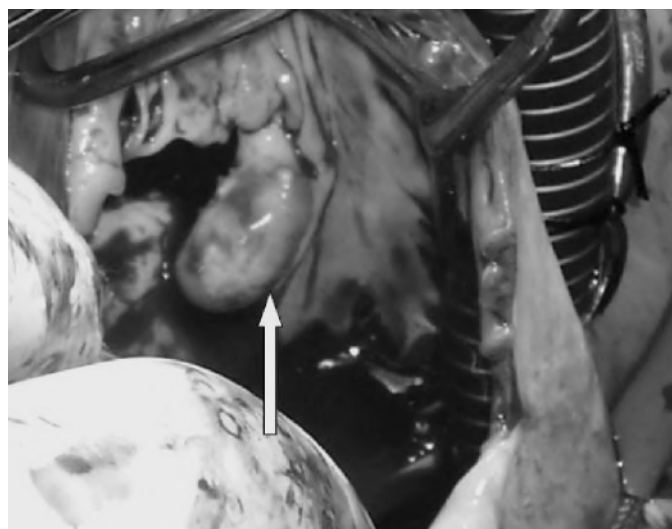


Fig. 2: Intraoperative view of the mass.

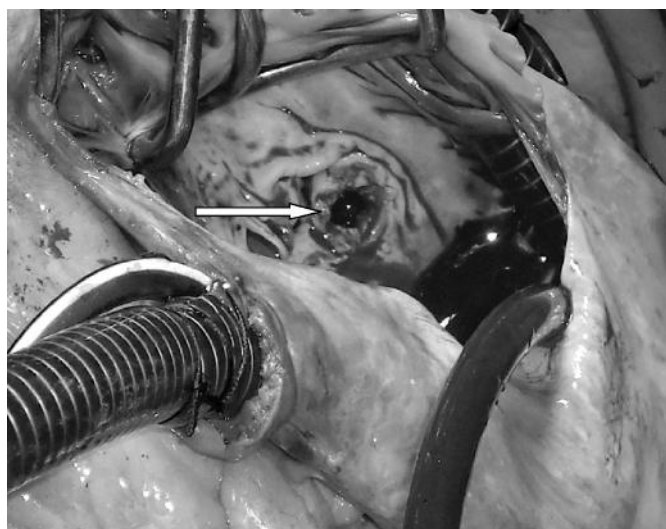


Fig. 4: Defect on the tricuspid valve after resection.

NYHA II. Supraventricular tachycardia (120/min) was found in Electrocardiogram. Blood analysis was normal besides eosinophilia (5%). Transthoracic echocardiography showed dilated right atrium (46 mm) and ventricle (37 mm) and a 1,5x1 cm heterogen mass located on the posterior leaflet of the tricuspid valve causing serious tricuspid regurgitation (Fig. 1). The patient was taken to surgery immediately with these findings.

After median sternotomy cardiopulmonary bypass was initiated with aortobicaval cannulation. Intermediate hypothermia (30 °C) and antegrade isothermic cardioplegia method were used. Vertical right atrial incision was made on the right atrial appendix extending to the inferior vena cava. A 2x2 cm calcific, fine regular surfaced, immobile mass located on the posterior leaflet of the tricuspid valve was seen. The calcification of this mass was extending to the interventricular septum through corda tendinea. This mass was resected intact with the attached valve tissue (Figs. 2, 3) including the calcified corda tendinea. Resection area was flushed with hypertonic saline

solution (3 NaCl%). Remaining defect (Fig. 4) was repaired by using Kay annuloplasty (bicuspidization of the valve technique) with 3/0 pledgetted-prolen suture material. CPB was terminated without any complications. After the operation Albendazole treatment was started (2x400 mg/day) with an ampicic base of the preoperative diagnosis of cardiac hydatid cyst and it was confirmed by histologic examination with an image of membranes and characteristic Echinococcus granulosus scoleces. The patient was discharged on the 6<sup>th</sup> post operative day. On 6<sup>th</sup> months follow up Albendazole treatment was stopped and transthoracic echocardiography revealed normal tricuspid valve function. The patient was NYHA I.

## Discussion

Hydatid cyst infection is an illness that can be found as endemic in cattle and sheep breeders where Echinococcus granulosus is agent. Generally cyst is located in liver and

lungs. Also brain, heart, kidney, urethra, spleen, uterus, fallopian tube, mesentery, pancreas, diaphragm and muscle localizations are seen. Embryos of parasite arrive to heart via pulmonary artery and/or coronary artery. Distribution of the cyst within the heart depends on the amount of blood coming to that area. Hydatid cyst disease involves the myocardium in most cases and endocardial involvement is rarely seen. Cardiac hydatid cysts are seen in left ventricle 55-75%, right ventricle 15-18%, interventricular septum 5-9%, right atrium 3-4% and interatrial septum 2%. In our case a very rare localization of tricuspid valve posterior leaflet is presented. According to our knowledge this is the second report with similar localization of this disease <sup>10</sup>.

Cardiac hydatid cyst symptoms are variable; cardiac arrhythmias, left and right ventricle outflow tract obstruction symptoms, angina pectoris, pericardial reaction, pulmonary and systemic emboli, pulmonary hypertension, anaphylactic reactions may occur depending on the localization of the cyst. If the cyst it is located on the interventricular septum the cyst can widen to right ventricle inflow tract and cause tricuspid stenosis or it can widen to the left ventricular inflow tract and cause mitral stenosis.

Clinical findings occur depending upon the size, calcification grade, localization and possible complications of the cyst. Generally there is a long asymptomatic phase. It is reported that in a series of 7 cases with nonspecific symptoms, dyspnea is the most frequent nonspecific symptom<sup>5</sup>. Because its symptoms are nonspecific, cases living in endemic regions and have hydatid cyst history, should be examined also for cardiac hydatid cyst <sup>6</sup>. Our patient had sudden onset of dyspnea, weakness, tachycardia, malaise and palpitation. In our case, decompensated right ventricle failure was responsible for the symptoms.

Although eosinophilia is frequently seen in paracitic infections in a study of 7 patients there were only 2 who had eosinophilia <sup>7</sup>. In our case WBC count was 9800 and eosinophilia was present (5%).

Radiographic imaging of the disease may vary depending on the effected area, life cycle of the parasite, body's reaction to the parasite and degeneration of the cyst. Normally cysts are homogeneous; it may also show heterogeneity when there are female vesicles and septation inside the cyst. If there are several cyst located in the heart the views may mimic cardiac tumors.

Echocardiography is the most frequently used imaging technique for cardiac hydatid cyst disease. Lesion is usually a membrane filled with septations or baby cysts in echocardiography. If the cyst is calcified it can be confused with intracardiac mass like tumor or foreign body <sup>8</sup>. In our case calcific mass was seen in echocardiography and definitive diagnosis was made by intraoperative view and histopathologic examination. Some authors support that performing routine echocardiography in patients with pulmonary and hepatic cyst hydatid disease <sup>9</sup>. Our case also favors this idea.

The best treatment for cardiac hydatid cyst disease is surgical removal. Surgical mortality is reported to be as 0.29% - 0.6 <sup>1-4</sup>. CPB and myocardial arrest is a safe method <sup>12</sup>. Before opening the female cysts surrounding area should be covered with sponges soaked with a hypertonic saline solution after that the cyst can be aspirated with fine needle. Inside of the cyst can be sterilized by infusion of either hypertonic saline, 2% formol, 1% iodine or 0.5% silver nitrate solutions without any agreement which of them is useful. Once the cyst is opened the germinative membrane is removed from inside and the remaining cavity is filled with hypertonic saline solution. One of the most important subject is that removing the cyst without perforation. The surgical approach depends on the surgeon since cardiac cyst hydatid disease is rarely seen. Less complex and safer approaches can be chosen in recurring cases <sup>5</sup>. We resected the mass with the attached valve tissue including the calcified tricuspidal corda tendinea. Resection area was flushed with hypertonic saline solution (3% NaCl) and remaning defect was repaired.

Following surgery albendazole, mebendazole or albendazole and praziquantel combination should be used for at least 6 months. It must be kept in mind that long term medical treatment does not prevent regeneration of the cyst from the possible remnants fertile elements after surgery <sup>5</sup>.

## Conclusion

Patients with a history of hydatid cyst disease should be followed for cardiac involvement. Any sign of dyspnea, tachycardia or other non-specific symptoms during follow up must remind cardiac involvement to physician. Surgical treatment of cardiac hydatid cyst disease with tricuspid valve involment include removal of the cyst, irrigation of the area, treatment of the insufficiency and adjuvant oral albendazole therapy in order to prevent recurrence.

## Riassunto

La malattia cistica idatidea coinvolge il cuore nel 0,02-2% dei casi. Essa si può presentare clinicamente con sintomi analoghi a quelli di una malattia coronarica, ad una valvulopatia cardiaca e ad una pericardite. Presentiamo il caso di una cisti idatidea localizzata nel lembo posteriore della valvola tricuspide, provocando rigurgito ventricolo-atriale in una donna che era stata sottoposta due anni prima ad una escissione di cisti idatidee da entrambi i polmoni mediante una stereotomia mediana.

Oltre alla dilatazione dell'atrio e dei ventricolo di destra, vennero rilevati un rigorgito tricuspide di secondo grado ed una significativa ipertensione polmonare. La mas-

sa a superficie liscia di 2 x 2 cm fu resecata dal lembo tricuspide posteriore ed il difetto venne chiuso per sutura in condizioni di by-pass cardio-polmonare. Fece seguito un trattamento a lungo termine con albendazolo. L'echinococcosi cardiaca va tenuta a mente in alcuni pazienti per tutta la loro vita se hanno una storia pregressa di idatidosi polmonare. L'escissione chirurgica senza rottura della cisti rappresenta il trattamento di scelta per le cisti idatidee a localizzazione cardiaca, con un seguito di trattamento medico per prevenire la recidiva.

## References

- 1) Kaplan M, Demirtas M, Çimen S, Özler A: *Cardiac hydatid cysts with intracavitary expansion*. Ann Thorac Surg, 2001; 71:1587-90.
- 2) Abu-Eshy SA: *Case report. Some rare presentations of hydatid cyst (Echinococcus granulosus)*. JR Coll Surg Edinb, 1998; 43:347-52.
- 3) Goel MC, Agarwal MR, Misra A: *Percutaneous drainage of renal hydatid cyst: Early results and follow-up*. Br J Urol, 1995; 75:724-28.
- 4) Brown RA, Millar AIW, Steiner Z, Krige JEJ, Burkimsher D, Cywes S: *Hydatid cyst of the pancreas: A case report in a child*. Eur J Pediatr Surg, 1995; 5:121-24.
- 5) Yalınz H, Tokcan A, Salih O.K, Ulus T: *Surgical Treatment of Cardiac Hydatid. Disease A Report of 7 Cases*. Tex Heart Inst J. 2006; 33(3):333-39.
- 6) Drissa H, Zayani Z, Boussaada R, Zaouali RM: *Cardiac hydatid cyst (report of 8 cases)*. Tunis Med, 2001; 79(11):633-37.
- 7) Abu-Eshy SA: *Case report. Some rare presentations of hydatid cyst (Echinococcus granulosus)*. JR Coll Surg Edinb, 1998; 43:347-52.
- 8) Çubuk M, Çeken K, Arslan G, Lüleci E: *Cardiac hydatid cyst*. Turk J Diagn Intervent Radiol, 2001; 7:125-27.
- 9) Bashour TT, Alali AR, Mason DT, Saalouke M: *Echinococcosis of the heart: Clinical and echocardiographic features in 19 patients*. Am Heart J, 1996; 132:1028-30.
- 10) Gholam Reza R, Amir A: *Endocardial hydatid cyst: A rare presentation of echinococcal infection*. European Journal of Echocardiography, 2008, 9:342-43.
- 11) Tetik O, Lafç B, Ozdemir T, Gürbüz A: *Hydatid cyst Located In Right Ventricular Wall*. T Klin Kalp Damar Cerrahisi, 2003; 4:171-73.
- 12) Uysalel A, Yazicioglu L, Aral A, Akalin H: *A multivesicular cardiac hydatid cyst with hepatic involvement*. European Journal of Cardio-thoracic Surgery, 1998; 14:335-37.