

# Reconstruction of post-traumatic losses of substance of the scalp

## Our experience



Ann. Ital. Chir., 2013 84: 299-303

pii: S0003469X13018393

[www.annitalchir.com](http://www.annitalchir.com)

Stefano Chiummariello, Matteo Angelisanti, Chiara Calzoni, Davide Francioso, Carmine Alfano

*Chair of Plastic and Reconstructive Surgery, University of Perugia, Italy*

### Reconstruction of post-traumatic losses of substance of the scalp. Our experience

**AIM:** *The reconstruction of post-traumatic losses of substance of the scalp is very difficult due to the unique characteristics of the scalp. The purpose of this paper is to evaluate the results obtained with several techniques in order to identify the most appropriate.*

**METHODS:** *We treated 19 patients, 11 men and 8 women aged between 19 and 81 years, with post-traumatic loss of substance of the scalp from January 2006 to June 2011. The chosen treatments were the direct closure and the use of local flaps, the latter combined or not with the graft of the donor area and the post-operative correction of alopecic area with tissue expansion.*

**RESULTS:** *None of the patients developed severe complications and all flaps were viable. The aesthetic results were variable, between good and satisfactory according to the technique used.*

**CONCLUSION:** *The local flaps represent a good choice for the treatment of post-traumatic losses of substance of the scalp, restricting the use of direct suture and the use of skin grafting only in selected cases. Tissue expansion is a good choice for the revision of alopecic and cicatricial areas.*

**KEY WORDS:** Local flaps, Scalp, Tissue expansion

### Introduction

The objectives of the reconstruction of full thickness losses of substance of the scalp are the protection of the underlying skull and recovery the aesthetic appearance of the scalp. The principle of the reconstruction of a tissue with similar tissues ("like tissue with like tissue") is particularly valid for the scalp because of its unique

features, such as the presence of hair. The repair of these lesions depends much from their location and their extent.

Various techniques have been proposed for the reconstruction: from partial-thickness skin grafts, to local flaps in variously prepared and free flaps, until tissue expansion, especially good for the revision of the defect in a second operating time.

Among all, the local flaps were most frequently used and there are a number of local flap techniques: single or multiple, and with or without skin grafting to close the donor defects. Single flaps in turn comprise advancement, rotation, transpositioning, VY advancement etc. Multiple flaps in turn include the triple-flap technique described by Orticochea, double rotation flap, V-Y-S scalp plasty technique, etc.<sup>1,2</sup>

In this paper we report our experience in treating post-traumatic loss of substance of the scalp with the use of different techniques.

*Pervenuto in Redazione Febbraio 2012. Accettato per la pubblicazione Maggio 2012*

*Correspondence to: Stefano Chiummariello, MD, Cattedra di Chirurgia Plastica Ricostruttiva, Università degli Studi di Perugia, Sant'Andrea Delle Fratte, 06156 Perugia (E-mail: stefanochiummariello@gmail.com)*

## Materials and Methods

We evaluated the outcome in the treatment of 19 patients with complex post-traumatic loss of substance of the scalp treated at the Department of Plastic and Reconstructive Surgery, University of Perugia, from January 2006 June 2011. The patients were 11 men and 8 women (58% and 42% respectively) aged between 19 and 81 years (mean 46.3 years). All patients had a complex loss of substance of the scalp, extended until the galea, ranging in size from a few centimeters to include large areas of the scalp.

Different treatments were used: from the direct closure to the use of local flaps, isolated or associated with partial thickness skin graft to close the donor area, until the use of tissue expanders. The treatments have been variously used: both singly and in varies association between them, both in a single step and in different operative times.

The direct suture was used in two patients (10.5%) with very little loss of substance; in the remaining 17 patients (89.5%) were used local flaps of scalp (advancement, rotation and transposition flaps). In six patients the donor area of the flap was closed with partial-thickness skin graft taken from the anterolateral surface of the thigh by electrical dermatome, because it was not possible its direct suture (Fig. 1).

Subsequently at four of these patients the alopecic area due to the scar and grafting has been revised: we proceeded to its correction with the expansion of the scalp. We have positioned one or two expanders (depending on the size of the defect) that have been inflated progressively in the following weeks. Obtained an adequate expansion expanders were removed and the alopecic-cicatricial area has been corrected with skin flaps (Fig. 2). The duration of follow-up was between 60 months and 3 months, with an average of 26 months.

## Results

During follow-up complications not occurred in the two patients treated with direct closure.

In the remaining patients all flaps were viable and survived completely. Two patients experienced small dehiscence of margins of the flap that have been treated with medications in the following weeks obtaining the recovery.

The grafts used to cover the withdrawal areas have completely taken in 5 patients; only in one patient there was a small necrosis of the graft that was successfully treated conservatively with success in the following weeks.

In patients treated with tissue expansion, expansion was achieved on average 10 weeks after placement of the

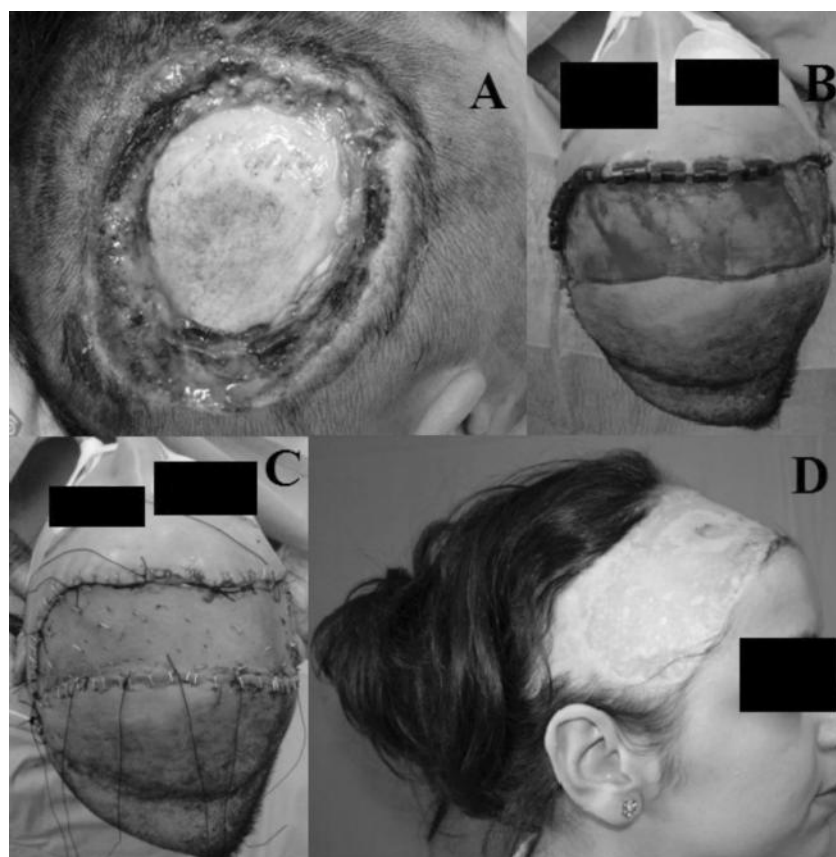


Fig. 1: Post-traumatic loss of substance in the occipital-parietal region. A: Preoperative appearance. B: Intra-operative view of the rotation occipital pedicle flap. C: Coverage of the donor area with skin graft. D: Outcome at 3 months.

expander. The flaps obtained with the expansion allowed the correction of the cicatricial-alopecic areas without the appearance of significant complications.

The aesthetic results were variable according to the treatment performed. Good results were obtained in patients undergoing revision of cicatricial-alopecic areas with tissue expansion (4 patients), in patients treated with flaps that not have necessitated of graft (11 patients) and patients treated with direct closure (2 patients).

Satisfactory results in the remaining patients (2 patients).

## Discussion

An ideal repair of the scalp is the reconstruction that close the defect completely and immediately, using skin close that does not develop alopecia, which heals quickly and present few complications. The main problem in the reconstruction of the scalp is due to its low elastic nature, especially at the vertex, where the galea is thicker and consequently less distensible. Incisions of the galea (galeotomy) have been proposed to reduce the tension of the defect at the time of closing, but require a high level of experience and there is a risk of damaging the neurovascular structures located in the galea itself or on its surface. This limits the direct closure of the loss of substance of the scalp to small wounds, forcing to use

more complex techniques for lesions exceeding 2-3 centimeters in width <sup>3</sup>.

Skin grafts are little used as the single treatment because of the lack of hair in the skin grafted, leads to the formation of an alopecic area which tends to ulcerate even after a small traumas. Moreover, their use requires a underground well vascularized which is provided by the subcutaneous tissue, the galea or the periosteum: the presence of one of these three structures can guarantee the survival of the graft. In the absence of periosteum, if the graft appears to be the only possible choice, the multiple perforations of the outer layer of the skull may promote the formation of granulation tissue able to promote the subsequent engraftment of the graft <sup>2,4</sup>.

The flaps appear to be the most utilized technique for the reconstruction of the scalp: among those local flaps are the most used.

The transposition flaps have historically been used for the repair of extensive loss of substance of the scalp. This technique is particularly useful for repair of defects involving the hairline, but requires the dissection of a significant portion of the scalp<sup>3</sup>. Among the disadvantages of these flaps there are the formation of unaesthetic "dog ears" or the need to graft the donor area <sup>5,6</sup>. In case of formation of "dog ears" should be avoided their removal during the first surgery since it leads to a higher tension on the wound edges; also, in many cas-

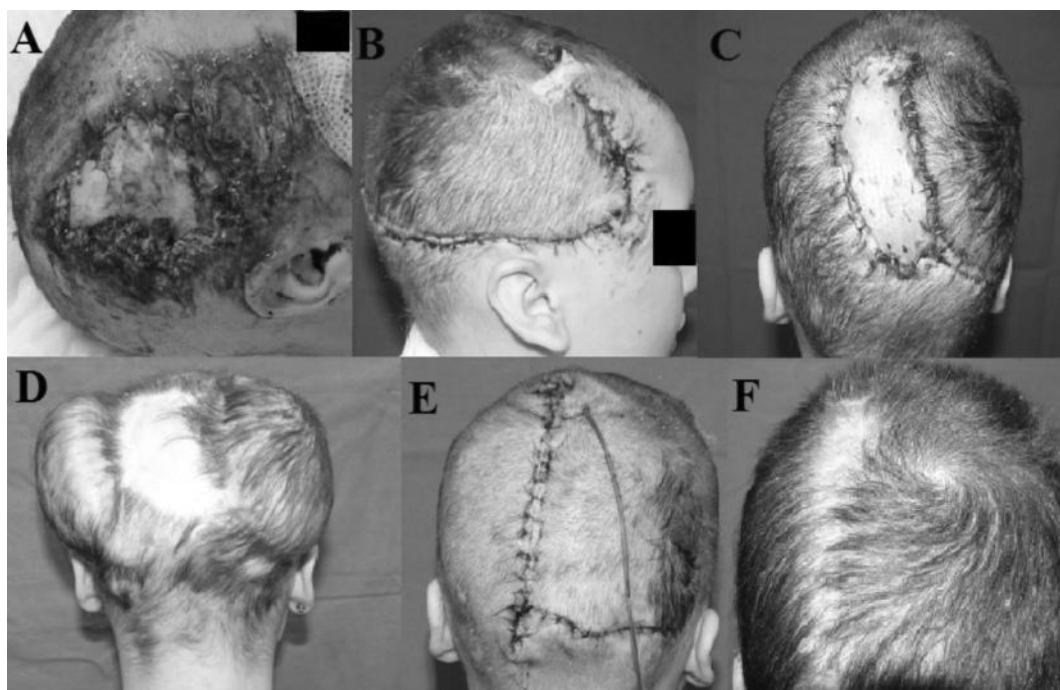


Fig. 2: Post-traumatic loss of substance of the parietal region. A: Preoperative appearance. B: Post-operative appearance, lateral view. C: Post-operative appearance, rear view. D: Appearance at the end of the inflation of the expanders. E: Post-operative appearance after removal of the expanders and correction of alopecic area. F: Final outcome at 3 months.

es, especially if these folds are small, may disappear with time<sup>1,5</sup>. Recently, Fincher et al. have reported the use of a double transposition flap for the coverage of a large defect of the scalp subsequent to the removal of a tumor, suggesting an additional option for the repair of large defects<sup>7</sup>.

The rotation flaps have the vantage to recruit tissue laxity from multiple directions, as well as from distant sites. Furthermore, the convexity of the scalp is ideal for the curvilinear design of these flaps (Fig. 1). The disadvantage is that the rotation flaps on the scalp require a disproportionately large incision relative to the defect size to be covered<sup>3</sup>. In our experience both of these types of flaps have proven effective in ensuring a good coverage of the loss of substance, guaranteeing good aesthetic results.

Also the advancement flaps are very useful in the repair of loss of substance<sup>5</sup>. Ibrahim et al. demonstrated the possibility to cover defects of moderate size with a bilateral advancement flap with the absence of significant complications<sup>3</sup>.

Regarding the aesthetic results, these can be further improved by the use of tissue expansion. This may be obtained by the progressive filling of the expanders positioned between the galea and the periosteum: the expanded skin maintains all its qualities in spite of greater thinness. The decreased density of hair is little visible<sup>8-10</sup> (Fig. 2). Some authors are proposing the expansion not through the traditional expanders, which require inflation with saline, but with osmotic expanders. These expanders have the advantage of they can be positioned more easily, with a smaller incision and a smallest pocket, making possible the positioning even under local anesthesia. The gradual expansion is well tolerated by patients and complications reported are very low<sup>8,11</sup>. Many authors in the literature have used the free flaps for covering large loss of substance<sup>12</sup>. These flaps have been reserved to cases where the local flaps were not indicated, as in the lesions with a traumatized periosteum or in poorly vascularized lesions (eg lesions on a tissue previously irradiated)<sup>1,6,12</sup>. Their advantage derives from the possible repair in one surgical step, with a highly vascularized tissue<sup>1,2</sup>. We believe that the use of these flaps has to be reserved to cases where it is not possible the use of local flaps, grafts or healing by secondary intention.

## Conclusions

The local flaps represent a valid choice in the repair of post-traumatic lesions of the scalp of various sizes. The direct closure and the graft represent two choices to restrict to specific cases: the first in small lesions (less than 3 centimeters) and the latter to emergency cases where a flap is not applicable.

Tissue expansion applied in a second step has proved a

good solution to solve the problems related to the presence of unaesthetic scars or alopecic areas related to the use of grafts, allowing the coverage of these areas with hairy skin, ensuring good aesthetic results.

## Riassunto

**SCOPO:** La ricostruzione delle perdite di sostanza post-traumatiche del cuoio capelluto sono particolarmente complesse date le peculiari caratteristiche che il cuoio capelluto possiede. Lo scopo di questo articolo è valutare i risultati ottenuti con diverse metodiche allo scopo di identificare la più appropriata.

**METODO:** Sono state trattati 19 pazienti, 11 uomini e 8 donne di età compresa tra i 19 e gli 81 anni, con perdita post traumatica del cuoio capelluto dal gennaio 2006 al giugno 2011. I trattamenti effettuati sono stati la chiusura diretta e l'uso di lembi locali, questi ultimi associati o meno all'innesto dell'area donatrice o alla revisione post-operatoria della zona alopecica con espansione tissutale.

**RISULTATI:** In nessun paziente si sono verificate severe complicanze; tutti i lembi sono risultati vitali. I risultati estetici sono stati variabili, tra buoni e soddisfacenti a seconda della tecnica utilizzata.

**CONCLUSIONE:** I lembi locali rappresentano una valida scelta per il trattamento delle perdite di sostanza post-traumatiche del cuoio capelluto, limitando il ricorso alla sutura diretta o all'uso del solo innesto cutaneo a casi selezionati. L'espansione tissutale rappresenta una valida scelta per la revisione delle aree alopeciche e cicatriziali.

## References

1. García del Campo JA, García de Marcos JA, del Castillo Pardo de Vera JL, García de Marcos MJ: *Local flap reconstruction of large scalp defects*. Med Oral Patol Oral Cir Bucal, 2008; 13(10):E666-70.
2. Frodel JL Jr, Ahlstrom K: *Reconstruction of complex scalp defects: the "Banana Peel" revisited*. Arch Facial Plast Surg, 2004;6(1):54-60.
3. Ibrahim OA, Jih MH, Aluma-Tenorio MS, Goldberg LH, Kimyai-Asadi A: *Repair of scalp defects using an H-plasty type of bilateral advancement flap*. Dermatol Surg, 2010; 36(12):1993-997.
4. Newman MI, Hanasono MM, Disa JJ, Cordeiro PG, Mehrara BJ: *Scalp reconstruction: a 15-year experience*. Ann Plast Surg, 2004; 52(5):501-06.
5. Sharma RK, Tuli P: *Occipital artery island V-Y advancement flap for reconstruction of posterior scalp defects*. J Plast Reconstr Aesthet Surg, 2010; 63(3):410-15.
6. Leedy JE, Janis JE, Rohrich RJ: *Reconstruction of acquired scalp defects: An algorithmic approach*. Plast Reconstr Surg, 2005; 116(4):54e-72e.
7. Fincher EF, Gladstone HB: *Dual transposition flaps for the recon-*

- struction of large scalp defects. J Am Acad Dermatol, 2009; 60(6):985-89.
8. Sharony Z, Rissin Y, Ullmann Y: *Postburn scalp reconstruction using a self-filling osmotic tissue expander*. J Burn Care Res, 2009; 30(4):744-46.
9. Gil T, Metanes I, Aman B, Taran A, Mayblum S, Izhak T, Har-Shai Y: *Six tissue expansion sessions of the scalp for reconstruction of post-burn alopecia*. J Burn Care Res., 2008; 29(2):390-94.
10. Hoffmann JF: *Tissue expansion in the head and neck*. Facial Plast Surg Clin North Am, 2005; 13(2):315-24.
11. Wollina U, Bayyoud Y: *Reconstruction of a large scalp defect by the sequential use of dermal substitute, self-filling osmotic tissue expander and rotational flap*. J Cutan Aesthet Surg, 2010; 3(2):106-10.
12. Calikapan GT, Yildirim S, Aköz T: *One-stage reconstruction of large scalp defects: Anterolateral thigh flap*. Microsurgery, 2006; 26(3):155-59.

