

Megacolon for a giant faecaloma with unlucky outcome

Case report and review of the literature



Ann. Ital. Chir., 2013 84: 319-322

Published online 30 May 2012

pii: S0003469X12018611

www.annitalchir.com

Paolo Caiazzo*, Ciro De Martino*, Giovanni Del Vecchio*, Pierpaolo Di Lascio*,
Massimiliano Marasco*, Fabia Laviani**, Pio Rocco Tramutoli*

A.O.R. "S. Carlo", Potenza, Italy

*U.O.C. di Chirurgia d'Urgenza

**U.O. di Radiologia d'Urgenza

Lethal giant fecaloma with megacolon. Report of a case and review of the literature.

We herein report a case of megacolon with fecaloma in an 83-year-old man who presented with constipation, no intestinal occlusion, and a left hydroureteronephrosis, with A.S.A. 4. The patient asymptomatic, was treated Primarily with laxatives. During the conservative therapy the patient presented an abrupt abdominal distension with a bowel obstruction and abdominal compartment syndrome. After the laparotomy and a Hartmann left colon resection the patient died for cardiovascular and metabolic complications. The aim of this report is to give a brief review of this entity and discuss the treatment options for these cases.

KEY WORDS: Bowel obstruction, Fecaloma, Megacolon

Background

The fecaloma is a condition frequently found, especially in the geriatric patient, but rarely can become, for the size and consistence that reaches, an emergency surgical or at least a disease with a complex management, due to anatomical and physiological alterations that causes on the intestine. The authors describe the unusual case of a giant fecaloma who occupied the lumen of the

transverse colon, descending, sigmoid and rectum, megaliths, in an asymptomatic patient, referral to the E.R. on the advice of the treating physician for the presence of an abnormal mass deformed profile of the abdomen. The course of the disease, not acute, apparently initially managed with conservative therapy, had a sudden and ominous conclusion, which led the authors to review the literature on the best strategy for this unusual disease.

Case report

A man of 83 years, G.A., was conducted in the emergency department of his doctor's advice, for the relief of a massive abdominal swelling, interpreted as "suspected cancer". The patient, already subject thirty years before of a gastric resection for complicated peptic ulcer disease, was suffering from ischemic heart disease and hypertension, abdominal aortic aneurysm, diabetes mellitus type II and pulmonary emphysema, and did not report any symptom relief, but chronic constipation; he refer-

Pervenuto in Redazione Dicembre 2011. Accettato per la pubblicazione Gennaio 2012

Correspondence to: Paolo Caiazzo, MD, "A.O.R." S. Carlo, U.O.C. Chirurgia d'Urgenza, 85100 Potenza, Italy (e-mail: paolo-caiaa@virgilio.it)

ring one bowel movements every five-six day with hard stools. The patient's vital signs were within normal limits as well as blood tests, except for an elevation of serum creatinine (3.2 mg / dL) and urea (71 mg / dL). On physical examination showed a swelling, which is deformed profile of the abdomen at the level of epimesogastrium, left hypochondrium and part of right hypochondrium, about the size of 20x10 cm (Fig. 1). This swelling did not appear, on palpation, pertaining to the abdominal wall, was smooth in contour, hard-wood consistence, slightly mobile and nontender. Rectal exploration is appreciated a fecaloma in rectal ampulla, with hard consistency, non-fragmented, accompanied by little runny stools, normocolic, in the absence of traces of blood. The sonographic examination of the abdomen showed, at the level of swelling clinically evident, the presence of abnormally stretched colonic loop, containing a solid mass with complex echostructure, with echogenicity in part with calcific-like, not completely obstructing the lumen of the bowel; was also reported a moderate left hydronephrosis. The abdominal x-ray confirmed the presence of considerable distension of the transverse colon and left colon, partly contained by air and partly occupied by the giant fecal. Was therefore carried out a study of the colon with barium with iodinated contrast medium, which showed the passage of the same contrast around the fecal mass, with no evidence of complete obstruction of the bowels. The imaging was completed with a CT scan of the abdomen which offered striking iconography of the rare pathology (Fig. 2), and that it also allowed to demonstrate that the left hydronephrosis was due to compression by the fecaloma on the urinary tract. Non signs of distended small bowel was reported. It therefore decided, in light of the patient's clinical status, for multiple chronic diseases which are affected, to start a conserva-

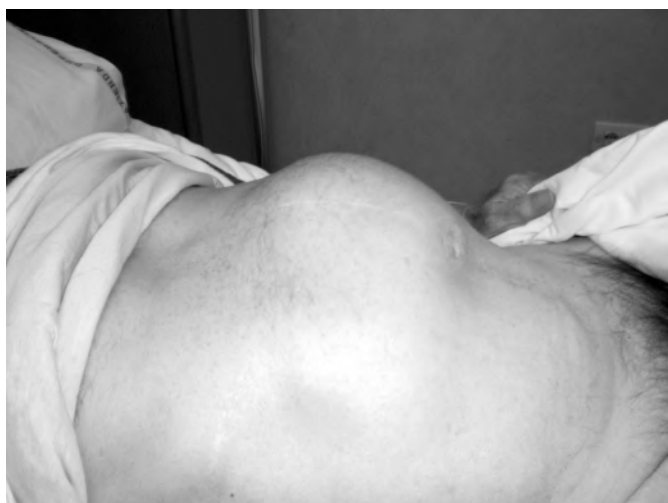

Fig. 1: Appearance of the abdomen of the patient at the physical examination.

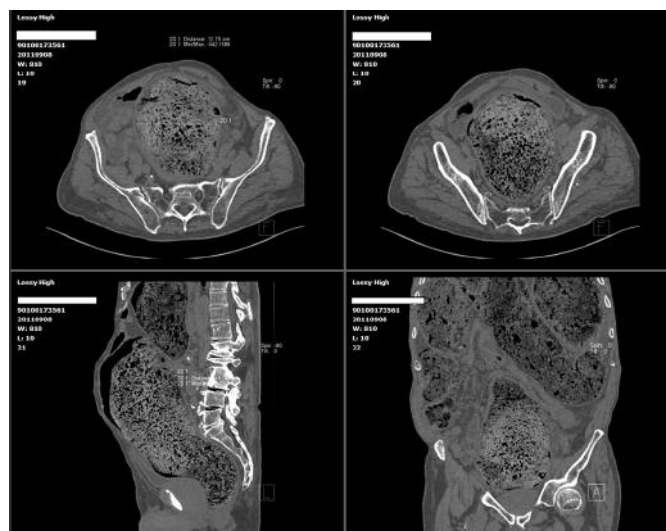


Fig. 2: images CT of the megacolon containing the giant fecaloma.

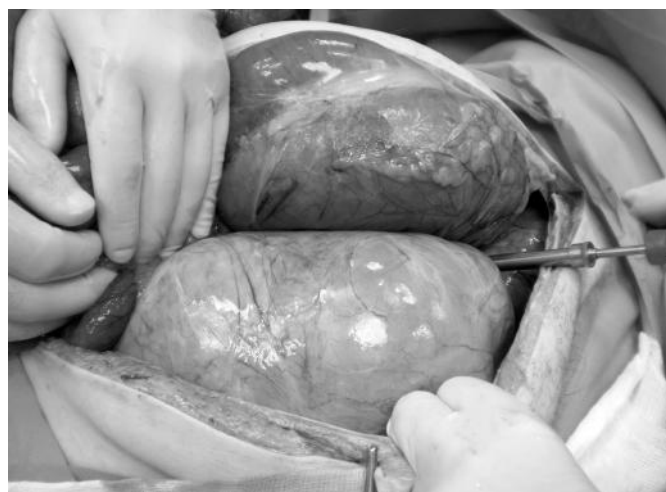

Fig. 3: Intraoperative view of megacolon during emergency laparotomy.

tive treatment in an attempt to soften the fecaloma, with repeated enemas and laxatives; the patient was placed in parenteral nutrition. After 72 hours the patient performing first very soft stools and after little hard stools; after five days the palpable mass on the abdomen was less tense on palpation, blood urea nitrogen and creatinine normalized, and the abdominal ultrasonography showed a discrete reduction of the left hydronephrosis. After seven days the patient suddenly had an acute abdomen, as mechanical bowel obstruction, with vomit and rapid deterioration of general conditions. The surgery was performed in emergency laparotomy, which was used to detect the complete obstruction of the intestinal lumen by the massive fecal impaction, probably moved by treatment with emollient laxatives and enemas (Fig. 3), and abdominal compart-

ment syndrome, with moderate suffering of the small bowel. The intervention was carried out with a Hartmann-left hemicolectomy. In the second post-operative day occurred the exitus of the patient due to metabolic and cardiovascular complications.

Discussion

The "fecaloma" is constituted by a mass of feces, collected more often in the sigmoid and rectum, hard or rubbery consistency, which makes it difficult peristalsis, triggering a chain of events that cause the accumulation of further upstream feces. This clinical condition is often found in the elderly, chronically constipated, often affected by a dolichomegacolon. The hard fecal mass can sometimes take on the appearance and consistence of a heteroplasia, posing problems of differential diagnosis¹⁻³. Here are also complex diseases that may favor the formation of fecaloma, often more difficult to resolve, such as Hirschsprung's disease, Chagas disease, colic stenosing disease due to chronic inflammation or neoplasms⁴⁻⁶. The symptoms and clinical signs of fecaloma are often nonspecific, with alternating diarrhea and constipation, weight loss and vague postprandial abdominal pain symptoms. Constipation is one of the signs most frequently reported in these cases, and is the primary cause of use the medical examinations by patients. The composition of a fecaloma is rather inconstant, but most often consisting of a mixture of feces and debris of the intestinal wall. Often, more consistency is caused by deposits of calcium soaps stratified bulk. The distal colon and rectum are the most frequent site of fecaloma. Common complications are represented by pseudobstruction, perforation, ulceration of the colonic mucosa with bleeding⁷⁻⁹. Here are reports of single or bilateral hydronephrosis ab-extrinsic compression¹⁰. In most cases these conditions are resolved to the patient's home or into the hospital with digital-fragmentation of the fecaloma, enemas and laxatives¹¹. Very rarely is required laparotomy for removal of feces, and this happens for the diagnosis of the described complications or for the detection of diseases predisposing colic already mentioned. Cases are reported in the literature of success after endoscopic approach for removal of fecaloma with the mechanical fragmentation¹². Knobel B. et al describe a case of a massive faecaloma in a patient of 81 years, which caused severe constipation and bilateral hydronephrosis from compression, solved with simultaneous intestinal washings with enemas, and manual fragmentation¹³. Garisto et al described the rare case of fecaloma in a 12 years-old patient, treated surgically after failed attempts with laxatives and endoscopic fragmentation, with elective laparotomy, sigmoid resection and colo-rectal anastomosis¹⁴. In the case described, the decision to approach the disease with conservative treatment is certainly born from chronic conditions that had arisen in colon, and

a high risk for surgery and anesthesia, which appeared in this case the patient recruited. The first few days of therapy had been successful with the initial partial detention of the colon and the resolution of the left hydronephrosis. Unexpected and rapid change has been the acute complication, probably caused by the displacement of huge fecal mass, softened in part, that led to the inevitable in emergency laparotomy, not decisive for the survival of the patient.

Conclusions

The clinical case described, very singular for the size and consistence of the fecaloma, give rise to serious reflection on the difficulty in planning the diagnostic strategy of a chronic and progressive disease, which may involve more often the elderly patient, already weakened by pre-existing chronic diseases. The emergency laparotomy with resection of a bowel megaliths and unprepared, on a patient at high risk for surgery and anesthesia, for a disease which begins in the absence of acute complications, or groped in the conservative medical therapy in an attempt to partially solve the syndrome and then operate in election? The scientific literature does not express a unanimous consensus on this topic. The decision shall be assigned from time to time to good clinical sense, the collaboration of a multidisciplinary team to evaluate each case the most appropriate therapeutic strategy, which in our opinion in such cases can not be standardized because of the complexity of such medical and surgical patients.

Riassunto

Gli Autori descrivono il caso clinico di un paziente di 83 anni con un megacolon da fecaloma gigante, giunto alla osservazione in Pronto Soccorso asintomatico, in assenza di franca occlusione intestinale, con un'idroureteronefrosi sinistra da compressione ab-estrinseco, che lamentava stipsi ostinata. Il paziente per le patologie concomitanti preesistenti presentava un A.S.A. Score di 4. Si decideva pertanto di trattare il paziente con terapia medica, lassativi e clisteri ripetuti. Dopo alcuni giorni, a causa della probabile parziale mobilizzazione del fecaloma all'interno del lume colico, il paziente presentava un improvviso aggravamento delle condizioni generali con segni clinici di occlusione intestinale e sindrome compartimentale addominale. La laparotomia urgente prevedeva una resezione del colon traverso e del colon sinistro secondo Hartmann, seguita dopo poche ore dall'exitus del paziente. Tale infausto caso clinico induce, attraverso una revisione della letteratura, a formulare delle riflessioni su quale possa essere la migliore strategia terapeutica per tali pazienti; si conclude che non esistendo un protocollo standardizzato per la rarità del riscontro e per la complessità

clinica che spesso rappresentano i pazienti geriatrici portatori di fecalomi, la decisione sul trattamento va decisa caso per caso, con una vigile osservazione per le precarie e instabili condizioni anatomopatologiche di un intestino megacolonico, a pareti assottigliate ed ipoperistaltico.

References

1. Sonnenberg A, Koch TR: *Physician visits in the United States for constipation*. 1958-1986. *Dig Dis Sci*, 1989; 34:606.
2. Fischer JE, Bland KI: *Mastery of Surgery*. 4th Edition. Vol adelpia. Lippincott Williams Wilkins. 2001; 1636-37.
3. Childress MH, Martel W: *Fecaloma simulating colonic neoplasm*. *Surg Gynecol Obstet*, 1976; 142:664-66.
4. Altomare DF, Rinaldi M, Sallustio PL, Armenise N: *Giant fecaloma in an adult with severe anal striature caused by anal imperforation treated by proctocolectomy and ileostomy: Report of a case*. *Dis Colon Rectum*, 2009; 52:534-37.
5. Campbell JB, Robinson AE: *Hirschprung's disease presenting a calcified fecaloma*. *Pediatr Radiol*, 1973; 1(3):161-63.
6. Araki T, Miki C, Yoshiyama S, Toiyama Y, Sakamoto N, Kusunoki M: *Total proctocolectomy and ileal J-pouch anal anastomosis for chagasic megacolon with fecaloma: Report of a case*. *Surg Today*, 2006; 36(3):277-79.
7. Kaufman SA, Karlin H: *Fecaloma of the sigmoid flexure*. *Dis Colon Rectum*, 1966; 9:133-36.
8. Rajagopal A, Martin J: *Giant fecaloma with idiopathic sigmoid megacolon: Report of a case and review of the literature*. *Dis Colon Rectum*, 2002; 45:833-35.
9. Maull KJ, Kinning WK, Kay S: *Stercoral ulceration*. *Am Surg*, 1982; 48:20-24.
10. Yuan R, Zhao G, Papez S, Cleary J, Heliotis A: *Urethral obstruction and bilateral hydronephrosis secondary to fecal impaction*. *J Clin Gastroenterol*, 2000; 30:314-16.
11. Segall H: *Obstruction of large bowel due to fecaloma. Successful medical treatment in two cases. Titolo rivista e dati bibliografici*.
12. Sakai E, Inokuchi Y, Inamori M, Uchiyama T, Iida H, Takahashi H, Akiyama T, Akimoto K, Sakamoto Y, Fujita K, Yoneda M, Abe Y, Kobayashi N, Kubota K, Saito S, Nakaijma A: *Rectal fecaloma: Successful treatment using endoscopic removal*. *Digestion*, 007; 75:198.
13. Knobel B, Rosman P, Gewurtz G: *Bilateral hydronephrosis due to fecaloma in an elderly woman*. *J Clin Gastroenterol*. 2000; 30(3):311-13.
14. Garisto JD, Campillo L, Edwards E, Harbour M, Ermocilla R: *Giant fecaloma in a 12-year-old-boy: A case report*. *Cases J*, 2009; 2:127.