

# Pelvic pain and Papillary Thyroid carcinoma

## Case report



Ann. Ital. Chir., 2013 84: 347-350

pii: S0003469X12019720

[www.annitalchir.com](http://www.annitalchir.com)

Paolo Del Rio\*, Belinda De Simone\*, Giuseppe Robuschi\*\*, Mario Sianesi\*

\*Unit of General Surgery and Organ Transplantation, University Hospital of Parma, Department of Surgical Science, Parma, Italy

\*\*Unit of Endocrinology, University Hospital of Parma

### Pelvic pain and Papillary Thyroid carcinoma. Case report

*Usually differentiated thyroid cancer has a good prognosis and only rarely shows distant metastasis at diagnosis above all the papillary carcinoma.*

*We present the case of a female patient of 66 years old affected by a papillary thyroid carcinoma with a bone metastasis as initial presenting symptom; she was hospitalized for pelvic pain and motor weakness and treated for severe osteoporosis. The patient was submitted to pelvis X-Ray that showed an area of bone loss and cortical irregularities of the right acetabulum, which was compatible with secondary neoplastic lesion but no primary tumor was found.*

*The bone biopsy showed "papillary thyroid carcinoma, follicular variant", so the patient was candidated to a total thyroidectomy.*

KEY WORDS: Differentiated thyroid cancer, Papillary thyroid cancer, Thyroid bone metastases, Thyroidectomy, Thyroglobulin.

### Introduction

Distant metastasis in papillary thyroid cancer is rare above all at diagnosis but we can find it with a frequency of 1.4%-7%<sup>1</sup>; the patients are often over 45 and above all female.

Usually the first manifestation of papillary thyroid cancer is a thyroid nodule or a neck mass and less frequently metastases in regional lymph nodes. Distant metastases are rare as initial presenting diagnosis and usually occur in advanced stages of the disease, especially in

lungs, bones and toracic lymph nodes. Distant metastases increase the mortality up to 50% in 1 year<sup>2</sup>, in fact for metastatic disease from well-differentiated thyroid cancer, a 10 year survival was reported as 13% to as high as 61%<sup>1</sup>.

We report the case of a 66 years old female patient, affected by papillary thyroid cancer with symptomatic bone metastases as first manifestation of the disease.

The authors have obtained the patient's informed written consent for print and electronic publication of the case report.

### Case report

A female patient of 66 years old, was admitted in our department of General Surgery and Organ Transplantation to be submitted to total thyroidectomy and selective lymphadenectomy (VI level) for papillary thyroid cancer.

She was apparent well-being and her vital parameters were normal. She complained about pelvic pain.

*Pervenuto in Redazione Maggio 2012. Accettato per la pubblicazione Agosto 2012*

*Correspondence to: Del Rio Paolo, Unit of General Surgery and Organ Transplantation, University Hospital of Parma, Department of Surgical Science/ Parma-Italy, Via Gramsci 14, 43100 Parma, Italy (E-mail: [paolo.delrio@unipr.it](mailto:paolo.delrio@unipr.it))*

The patient had no family history of thyroid neoplastic diseases; she denied heart and / or pulmonary diseases. She told that her problems began when, because of the emergence of basin/pelvic pain and motor weakness, she was hospitalized in rheumatology division.

At the entrance the patient was affected by severe osteoporosis with multiple vertebral collapses. Because of this, she was submitted to pelvis X-Ray that showed an area of bone loss and cortical irregularities of the right acetabulum, which was compatible with secondary neoplastic lesion (Fig. 1).

To investigate the nature of the lesion, the patient underwent to a pelvis Computed Tomography (CT) (Fig. 2) that highlighted a lytic structural bone alteration, with a partial disruption and thinning of the cortical layer of the anterior column of the right acetabular roof; the radiologists advised to investigate the origin of the lesion by the bone scan and the Positron Emission Tomography (PET) total body.

The total body bone scan confirmed an increased osteoblastic activity localized at the coxal-femoral right articulation and at the right ilio-pubic branch of the basin.

Also the PET showed an area of glucose hypermetabolism at the right acetabulum.

Consequently the rheumatologists, in attempt to find the primitive neoplastic lesion, decided to submit the patient to an abdominal ultrasound that was negative for neoplastic lesions of the abdominal organs and to an ultrasound examination of the thyroid that highlighted a normal volume thyroid gland with an widely inhomogeneous echotexture, prob-

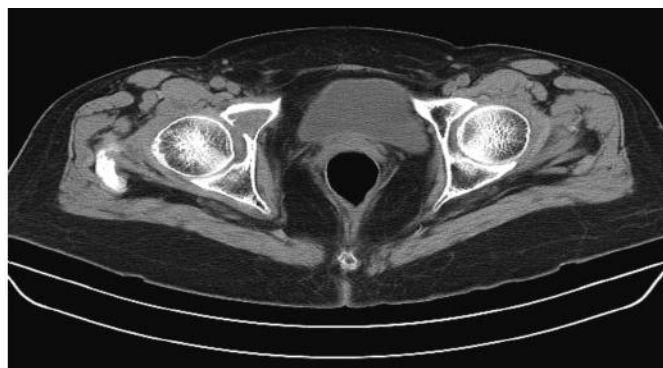


Fig. 2: Pelvis CT.

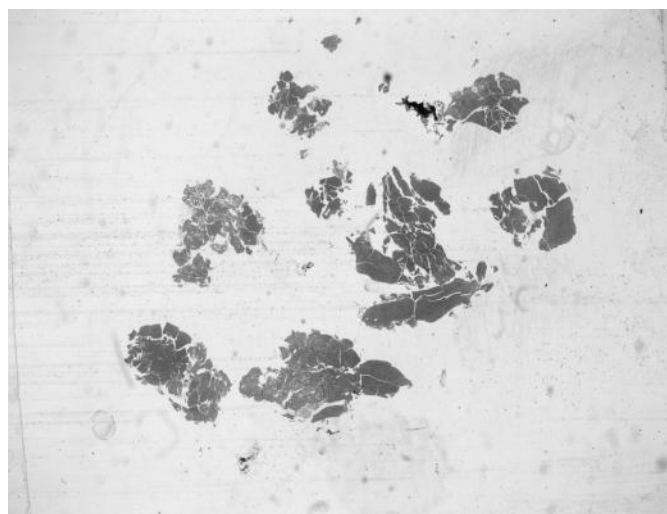


Fig. 3: Bone metastasis from papillary thyroid carcinoma, follicular variant.

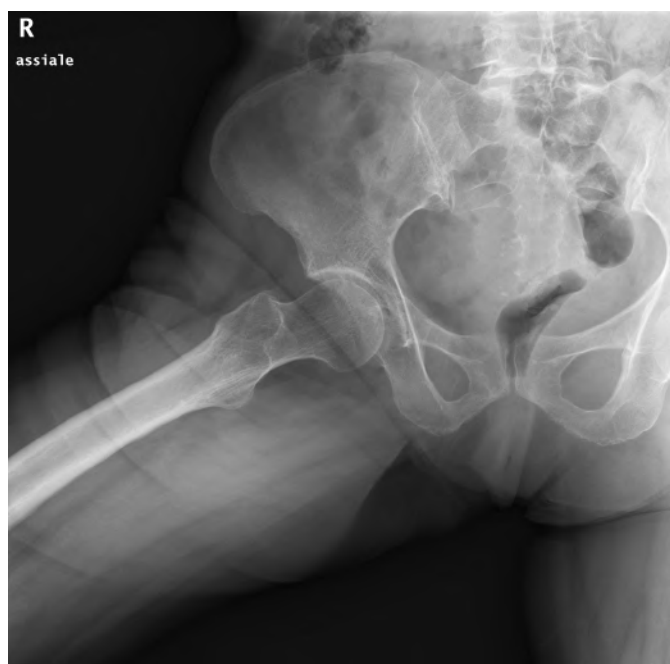

Fig. 1: Pelvic X-Ray.

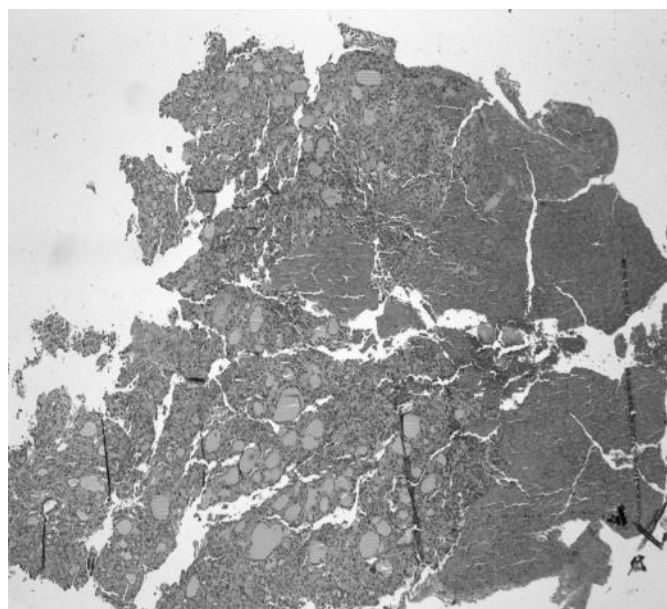


Fig. 4: Intra-thyroid papillary carcinoma, follicular variant, of the right lobe.

able outcomes of chronic thyroiditis and, at the right lobe, the presence of a suspicious nodule with sonographic features of benign lesion; no latero-cervical enlarged lymph nodes bilaterally were found.

The cytological examination of the thyroid nodule by fine needle aspiration was negative for the presence of neoplastic cells.

Finally, the rheumatologists, in agreement with the endocrinologists, decided to submit the patient to a bone biopsy. The histologic examination of the bone sampled showed "papillary thyroid carcinoma, follicular variant" (Fig. 3). With this clinical documentation, the patient was admitted to our surgery division.

Laboratory tests showed values of Hb at 11,6 g/dL; normal values of TSH, fT3, fT4 and calcitonin; thyroglobulin at 246,37 ng/mL.

At the preoperative anesthesia evaluation, the patient was considered an American Society of Anesthesiologist physical (ASA) status score 2.

The patient had a palpable thyroid gland; no other masses, no palpable lymphadenopathy and no neurological deficit were present. She presented pain to passive movement of the right leg on the basin.

On the day of admission, the patient was undergone intervention. A total thyroidectomy was performed; the mobilization of the right lobe was difficult for the presence of the nodule and the adhesions; two parathyroid glands were preserved.

No complications occurs in the early postoperative period and the patient was discharged on the second postoperative day with levothyroxine therapy. The histological examination of thyroid removed, revealed "intra-thyroid papillary carcinoma, follicular variant, of the right lobe, diffusely calcified (2.2 x 1.4 x 1.2cm) with follicular adenomatous hyperplasia; no lymph-node metastases" (Fig. 4).

At one year after surgery, the patient is making a visit to an endocrinologist with an ultrasound evaluation of the neck every month and a Positron Emission Tomography (PET) every three months (a second metastatic lesion was found, localized at the second-third lumbar vertebra).

She is performing the L-thyroxine therapy (125 micrograms and 100 micrograms on alternate days) and the medical treatment for osteoporosis. She was subjected to two sessions of Radioactive Iodine therapy (RAI).

Ten months after surgery, the patient was submitted to surgical remove of the vertebral metastasis; the acetabulum lesion will be removed shortly.

The last Thyroglobulin dosage (after the first session of RAI therapy and the surgical removing of the vertebral metastasis) was 83.05 ng/ml

## Discussion and Conclusions

Distant metastasis in thyroid cancer develops in 7-23% of patients with differentiated thyroid cancer. The inci-

dence of bone metastasis varies along with the degree of differentiation and histologic subtypes of thyroid cancer. Papillary thyroid cancer has been identified as the least likely subtype to cause bone metastases with incidences ranging from 1,4% to 7% in many reports.

The incidence of synchronous metastasis is 11% in follicular thyroid and 2% in papillary thyroid cancer and metastases are often solitary and not multiple <sup>1</sup>.

Most patients with bone metastases is often symptomatic and biopsy of the bone lesion shows us the primary tumor.

Unlike the good prognosis of papillary cancer confined to the thyroid gland or cervical lymph nodes, distant metastases increase the mortality up to 50% in 1 year <sup>2</sup>.

The treatment approach for differentiated thyroid cancer presenting with distant metastases is usually individualized, with a preference to performing a total thyroidectomy so as to facilitate RAI therapy, followed by L- thyroxine therapy to suppress the thyroid-stimulating hormone (TSH).

The serum dosage of thyroglobulin (Tg) is useful to measure the response of the patient to the RAI therapy and to find other metastases; in fact finding of undetectable Tg levels during TSH stimulation is highly correlated with clinical remission; Tg level > 1-2 ng/ml can indicate a recurrence/persistence of the disease <sup>3,4</sup>.

Our patient levels of Tg was 246,37 ng/ml before surgery; after the first RAI therapy and after the surgical removing of the vertebral metastasis was 83,05 ng/ml. Surgical excision of a solitary metastasis may benefit the patient in enhancing local control of disease and also improved quality of life <sup>5-9</sup>.

Early detection could initiate prompt therapy and improve survival.

Active treatment for metastatic disease improved survival. The major factors determining prognosis, the age at presentation, the site of metastasis, histologic subtype and iodine avidity, are confirmed to be important in patients with metastasis at presentation.

In according to the literature, patients presenting with metastatic disease have to be managed aggressively with total thyroidectomy followed by radioactive iodine. Young patients with papillary histology and iodine-avid tumors have the best prognosis.

In our clinical case the diagnosis was delayed because of the patient was suffering from severe osteoporosis that had masked the clinical symptoms of the bone metastases.

## Riassunto

I carcinomi differenziati della tiroide presentano una buona prognosi e raramente evidenziano come prima manifestazione clinica una metastasi a distanza. Presentiamo il caso di una donna di 66 anni affetta da carcinoma papillare della tiroide con metastasi ossee come sintomo

iniziale; essa era stata ricoverata per dolore irradiato alla pelvi e difficoltà alla deambulazione e trattata per osteoporosi severa. Una radiografia della pelvi dimostrò un'area di perdita di tessuto osseo ed irregolarità della corticale dell'acetabolo destro, che era compatibile con lesione neoplastica secondaria. La stadiazione non dimostrò alcuna macroscopica sede di lesione neoplastica primitiva. La biopsia ossea evidenziò la presenza di carcinoma papillare della tiroide, variante follicolare; la paziente fu sottoposta ad intervento di tiroidectomia.

## References

1. Do MY, Rhee Y, Kim DJ, Kim CS, Nam KH, Ahn CW, Cha BS, Kim KR, Lee HC, Park CS, Lim SK: *Clinical features of bone metastases resulting from thyroid cancer: A review of 28 patients over a 20-year period*. *Endocr J*, 2005; 52(6):701-7.
2. Angeles-Angeles A, Chable-Montero F, Martinez-Benitez B, Albores-Saavedra J: *Unusual metastases of papillary thyroid carcinoma: report of 2 cases*. *Ann Diagn Pathol*, 2009; 13(3):189-96. Epub 2008 Jun 26.
3. Colombo P, Locatelli F, Travaglini P: *Useful and limits of the biochemical markers for the diagnosis of thyroid carcinoma*. *Ann Ital Chir*, 2006; 77(3):209-14. Review. Italian.
4. Azim MA, Salam KS, Khan MK, Khan JA, Hussain MA, Kundu SC, Mostafa MG: *Metastasis in differentiated thyroid carcinoma*. *Mymensingh Med J*, 2010; 19(4):497-503.
5. Lawrence E, Lord ST, Leon Y, McIntyre PJ, Penix J, Grebenev D, Vesely DL: *Tall cell papillary thyroid carcinoma metastatic to femur: Evidence for thyroid hormone synthesis within the femur*. *Am J Med Sci*, 2001; 322(2):103-8. Review.
6. Ferrer García JC, Merino Torres JF, Ponce Marco JL, Piñón Sellés F: *Unusual metastasis of differentiated thyroid carcinoma*. *An Med Interna*, 2002; 19(11):579-82. Spanish.
7. Lin JD, Huang MJ, Juang JH, Chao TC, Huang BY, Chen KW, Chen JY, Li KL, Chen JF, Ho YS: *Factors related to the survival of papillary and follicular thyroid carcinoma patients with distant metastases*. *Thyroid*, 1999; 9(12):1227-235.
8. Genton CY, Dutoit M, Portmann L, Gillet M, Guillou L: *Pathologic fracture of the femur neck as first manifestation of a minute columnar cell carcinoma of the thyroid gland*. *Pathol Res Pract*, 1998; 194(12):861-3; discussion 865-6.
9. Sampson E, Brierley JD, Le LW, Rotstein L, Tsang RW: *Clinical management and outcome of papillary and follicular (differentiated) thyroid cancer presenting with distant metastasis at diagnosis*. *Cancer*, 2007; 110(7):1451-456.