

# Bile leaks after videolaparoscopic cholecystectomy: duct of Luschka.

## Endoscopic treatment in a single Centre and brief literature review on current management



Ann. Ital. Chir., 2012 83: 303-312

Chiara Lo Nigro, Girolamo Geraci, Antonio Sciuto, Francesco Li Volsi, Carmelo Sciumè, Giuseppe Modica

University of Palermo, Palermo, Italy

Section of General and Thoracic Surgery (Chief: Modica Giuseppe, MD, PhD)

Service of Surgical Endoscopy (Chief: Carmelo Sciumè, MD, PhD)

**Bile leaks after videolaparoscopic cholecystectomy: duct of Luschka. Endoscopic treatment in a single Centre and review of the literature**

**BACKGROUND:** *Laparoscopic cholecystectomy (LC) for gallstone disease is the most common surgical procedures performed in Western countries and bile leaks remain a significant cause of morbidity (0.2–2%). The bile ducts of Luschka (DL) are small ducts which originate from the right hepatic lobe, course along the gallbladder bed, and usually drain in the extrahepatic bile ducts. Injuries to these ducts are the second most frequent cause of bile leaks after cholecystectomy. Aim of our study is build a literature review starting from our experience.*

**PERSONAL EXPERIENCE:** *Fortyfour patients with abdominal bile collections post-cholecystectomy by suspected bile leak underwent endoscopic retrograde cholangio-pancreatography (ERCP). A complete cholangiogram was obtained in 42 patients (95.5%). In according to the magnitude of bile leak daily, we subdivided the patients in two groups: a) < 180 ml/daily, and b) > 180 ml/daily. The most common site of the leak was the cystic duct stump (94.5%), followed by DL (2 patient = 5.5%). 10 Fr stent insertion after endoscopic sphincterotomy (ES) was the most common intervention. In 6 patients (14%) a 7 Fr naso-biliary drainage was inserted. On an intention-to-treat basis, endoscopic intervention at ERCP had 100% success rate for resolution of the leak. The median time for resolution of the leak was 8 and 12 days in the first and second group respectively. No mortality ERCP-related were recorded. Early minor complications occurred in 7/42 (16.5%) patients.*

**METHODS:** *A literature search using MEDLINE's Medical Subject Heading terms was used to identify recent articles. Cross-references from these articles were also used.*

**RESULTS:** *ERCP is the most common diagnostic and therapeutic method used in bile leaks post-cholecystectomy. Most patients with DL leaks are symptomatic, and most leaks are detected postoperatively during the first postoperative week. Reduction of intra-ductal pressure with ES and stent or naso-biliary tube insertion will lead to preferential flow of bile through the papilla, thus permitting DL injuries to heal. This is the most common treatment modality used. In a minority of patients, re-laparoscopy is performed. In such cases, the leaking DL is visualized directly, and ligation usually is sufficient treatment. Simple drainage is adequate treatment for a small number of asymptomatic patients with low-volume leaks.*

**CONCLUSIONS:** *DL leaks occur after cholecystectomy regardless of gallbladder pathology or urgency of operation. They have been encountered more frequently in the era of LC. Intraoperative cholangiography does not detect all such leaks. ERCP with ES and stent placement are the most common effective diagnostic and therapeutic methods used. Intraoperative and perioperative adjunctive measures, such as fibrin glue instillation and pharmacologic relaxation of the sphincter of Oddi, can potentially be used in lowering the incidence and in the treatment of DL leaks.*

**KEY WORDS:** Bile leak ERCP, Laparoscopic cholecystectomy, Luschka duct, Subvesical duct

*Pervenuto in Redazione Aprile 2010. Accettato per pubblicazione  
Luglio 2011*

*Correspondence to: Girolamo Geraci, MD, Via Francesco Vermiglio 5,  
90129 Palermo, Italy (e-mail: geraci@unipa.it)*

## Introduction

Laparoscopic cholecystectomy (LC) is associated with an increased frequency of bile duct injury<sup>1</sup>. A significant postoperative bile leak occurs in approximately 0.8% to 1.1% of patients<sup>2-4</sup>. Elective LC presents fewer technical difficulties for dissection of the gallbladder pedicle or gallbladder bed than the procedure for acute cholecystitis<sup>1</sup>. Complications produced by the sectioning of a non-visualized duct of Luschka (DL) are uncommon during LC. Therefore, the diagnosis of this complication must be done as early as possible so it can be treated with non-invasive procedures<sup>1</sup>. A variety of percutaneous, endoscopic, and surgical treatments have been proposed in the treatment of DL leaks<sup>5</sup>. This review summarizes clinical manifestations of these ducts, as well as the methods used to diagnose and treat DL injuries. Possible adjunctive measures for prevention and treatment of these injuries will also be discussed.

## Anatomy

The duct of Luschka, first described in 1863, is a small bile duct (1-2 mm in diameter)<sup>6</sup>. It usually originates in the right hepatic lobe. DL is located very close to the gallbladder bed and has a variable drainage into the biliary tree. Most commonly it drains into the right or common hepatic duct<sup>6</sup>. It occurs in 20–50% of the population<sup>7,8</sup>. Embryologically, the DL arises from anomalous and autonomic proliferation of the most distal biliary ducts formed from the pars hepatica as it develops in the septum transversum. These biliary ducts may persist in certain zones where the liver parenchyma should regress secondarily during development<sup>9</sup>. It should not be confused with the hepatocystic duct, which is considered a variation of the biliary tree (an aberrant duct) in which one or more segments of the liver drain into the gallbladder or cystic duct<sup>10</sup>.

## Etiology

DL injuries occur during dissection of gallbladder elements: division and ligation of the cystic artery and cystic duct, and the dissection of the gallbladder from its bed in the liver<sup>11,12</sup>. There are several risk factors for DL injuries during cholecystectomy: (1) excessively deep plane dissection, (2) anatomical localization of DL, (3) anatomic anomalies of the biliary tree (18-39%), (4) difficult dissection from the gallbladder bed or Calot's triangle due to acute inflammatory reaction, (5) technical difficulties (i.e.: bleeding, previous surgery) during the identification of the gallbladder pedicle, (6) anatomical distortion of the biliary pedicle due to chronic inflammation (i.e: scleroatrophic reaction), (7)

injudicious use of cautery, or (8) inexperience on the surgeon's behalf<sup>1,11-15</sup>. Distal obstruction of the common bile duct from choledocholithiasis or sphincter of Oddi spasm may pose an additional problem and perpetuate a DL leak<sup>8</sup>.

## Clinical manifestations and diagnosis

Clinical symptoms are scarce after DL leak. Factors associated with clinical manifestations include the volume and distribution of bile in the peritoneal cavity, presence of sterile vs infected bile, and presence or absence of a drain<sup>11</sup>. Numerous diagnostic methods have been used to detect these injuries<sup>12</sup>. Nevertheless, careful clinical examination is still of the utmost importance. Three clinical patterns of presentation exist: (1) abdominal pain with fever and symptoms of local or general sepsis, or both, (2) external bile fistula, and (3) mild non-specific symptoms<sup>12</sup>. Very elevated bilirubin levels are uncommon in these patients<sup>12</sup>. In half of patients, symptoms appeared after the 5th postoperative day<sup>1</sup>. Tachycardia, ileus, fever, and shock were observed in these patients, along with diffuse bile peritonitis associated with a delayed diagnosis. Jaundice is a rare and later finding<sup>1</sup>. Therefore, the prognosis is uncertain when other symptoms, such as fever, ileus, jaundice, or shock, a bile peritonitis or infected collection has already been established<sup>1</sup>. Delayed diagnosis of a biliary leak depends that the majority of surgeons do not routinely drain the gallbladder bed after surgery<sup>11</sup>.

## Therapy

The treatment of DL leaks depends on the time of diagnosis: intraoperative or postoperative. Intraoperative visualization of injured DL, confirmed at cholangiography, could be treated with suture ligation or clip application. The simple ligation is adequate in treating DL leaks because these do not drain a significant amount of liver parenchyma<sup>16,17</sup>. Application of fibrin glue to the gallbladder fossa is an alternative, and in theory it may seal DL leaks<sup>18</sup>. In case of postoperative detection of DL leaks noninvasive treatments are usually effective. ERCP is the treatment of choice. ERCP with endoscopic sphincterotomy (ES), nasobiliary or stent insertion with or without percutaneous drainage of the bile collection (biloma) is usually effective<sup>4,8</sup>. In patients who present with acute abdomen or who are not cured by noninvasive treatments, exploratory laparotomy is the best approach (successful rate of 30% to 56% of cases)<sup>19</sup>. The surgical treatment consists of a lavage of the abdominal cavity, detection and closure of the duct of Luschka, and intraoperative cholangiography to that confirm the biliary tree is intact<sup>12</sup>.

## Materials and methods

Between January 2003 and January 2010 we performed 6840 ERCP, 267 LC and 47 open cholecistectomy (OC). Fourty-four patients referred for ERCP because of suspected bile leak (5%). A lot of these patients (31/44 =75%) coming from peripheral hospital centres. Three patients underwent to LC (1%) by our equipe of surgeons. A transparietal drainage was present in 37 (84%) patients. In 32 cases (86.5%) the biliary drainage was < 140 ml/daily (100-170 ml/daily). In the remnant 5 cases it was 220 ml/daily (180 –310 ml/daily). The patients without drainage showed a subhepatic bile collection (biloma), radiologically (ultrasound) confirmed. All the seven patients (16%) with biloma underwent to positioning a percutaneous drainage. Three of these patients (43%) showed a biliary drainage > 180 ml/daily. We considered a biliary drainage upper of 180 ml/daily as cut off between minor and major leaks (Tables .I and II). Median time from surgery to ERCP was 3.5 (range 2-6) and 6.4 (3-10) days in patients with drainage and without drainage, respectively ( $p < 0.001$ ). We divided the patients in two groups: a) patients with major leak (8 cases) and b) with minor leak (36 cases). All the patients underwent to ERCP. A complete cholangiogram was obtained in 42 patients (95.5%). Two patients

(4.5%) with a major leak had a complete transection of the right hepatic duct (major bile leak). They were referred to surgery, and excluded from the study. At the end six patients (14%) presented a major bile leak, and in all the cases were cystic duct stump. The most common site of minor leak was the cystic duct stump (34/36 patients = 94.5%), and the Luschka duct in 2 patients (5.5%).

## Results

ERCP with ES and 10 French straight stent insertion was employed in the patients with minor leak due to cystic duct stump. The proximal end of the stent was always positioned above the insertion sight of the cystic duct to the common hepatic duct. We used 10 French stent plastic (Amsterdam type, Olympus®, 7,9,12 cm) (Table III). No complication were observed (i.e.: clogging on migration). A 7 Fr naso-biliary tube (NBT) was inserted in the patients with major leak due to cystic duct leakage and in the patients with Luschka duct leaks (Fig. 1) The NBT was always positioned in the right hepatic duct. We used NBT with “pig-tail” end to reduce the risk of displacement (Fig. 2). No mortality ERCP related was recorded. Early minor complications occurred

TABLE I - Clinical manifestation in patients with post-cholecystectomy leak

	Patients with drainage	Patients without drainage	P
Total patients	37 (84)	7 (16)	
Abdominal pain, n. (%)	12 (32.5)	7 (100)	0.098
Fever, n. (%)	16 (43)	6 (85)	0.031
Jaundice, n. (%)	2 (5.5)	3 (43)	0.051
Ileus, n. (%)	–	2 (28.5)	0.035
Peritonitis, n. (%)	3 (8)	5 (71.5)	0.011
General sepsis, n. (%)	1 (2.5)	3 (43)	0.025

TABLE II - Demographic data from patients undergoing treatment for post-cholecystectomy leak

Presentation at admission (n.)		With drainage (37)	Without drainage (7)
Patients (M/F)		17/20	5/2
Age, median (range)		54 (32-76)	46 (37-56)
Type of surgery (emergency, %)	LC	27 (16 = 60%)	7
	OC	7 (5 = 71%)	–
	LC → OC	3 (2 = 66%)	–
Time to ERCP, median (range of days)°		3.5 (2-6)	6.4 (3-10)
Site of bile leak	Cystic duct stump	33	7
	Duct of Luschka	2	–
	Right hepatic duct	2	–
Severity of bile leak*	Low grade	30	6
	High grade	7§	1

LC, laparoscopic cholecystectomy; OC, open cholecystectomy; LC→OC, laparoscopic cholecystectomy converted to open cholecystectomy; ° $p < 0.001$ ; \* > or < 180 ml/daily; § 2 right hepatic ducts.

TABLE III

Stent group	10 French, 7 cm	10 French, 9 cm	10 French, 12 cm
N. patients (%)	19 (56)	11 (32)	4 (12)

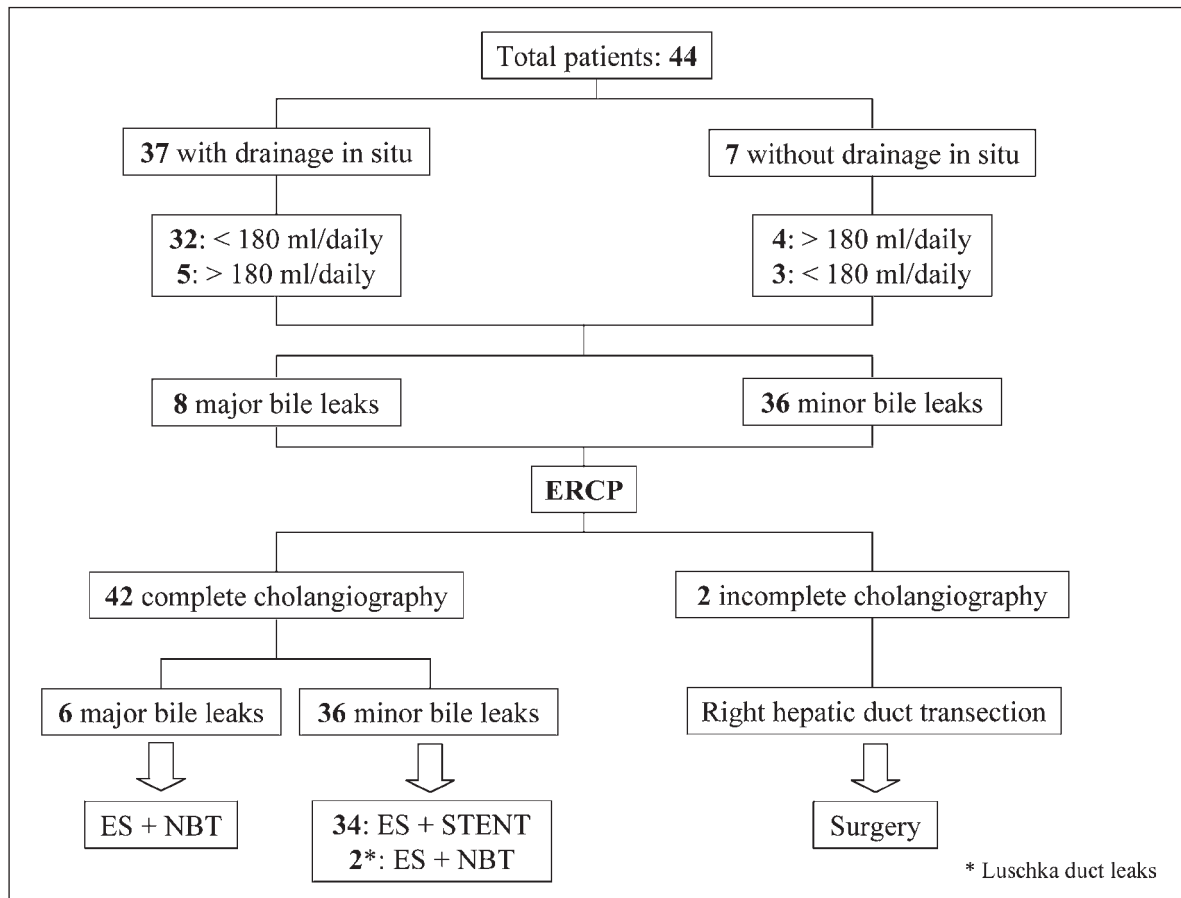


Fig. 1

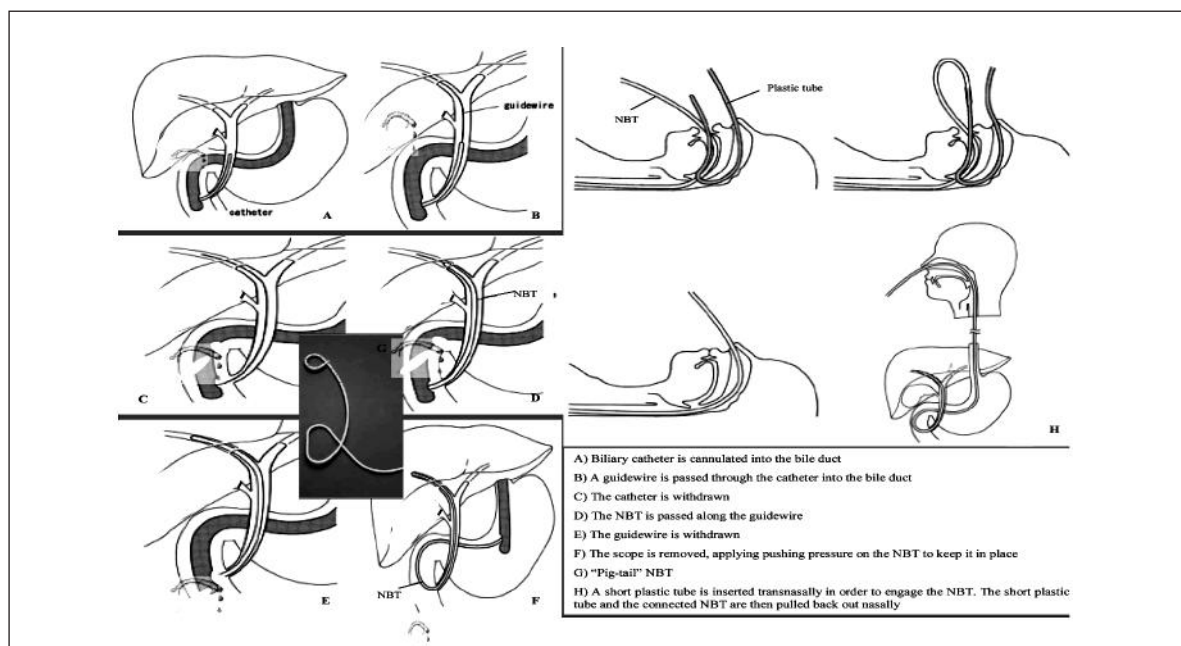


Fig. 2

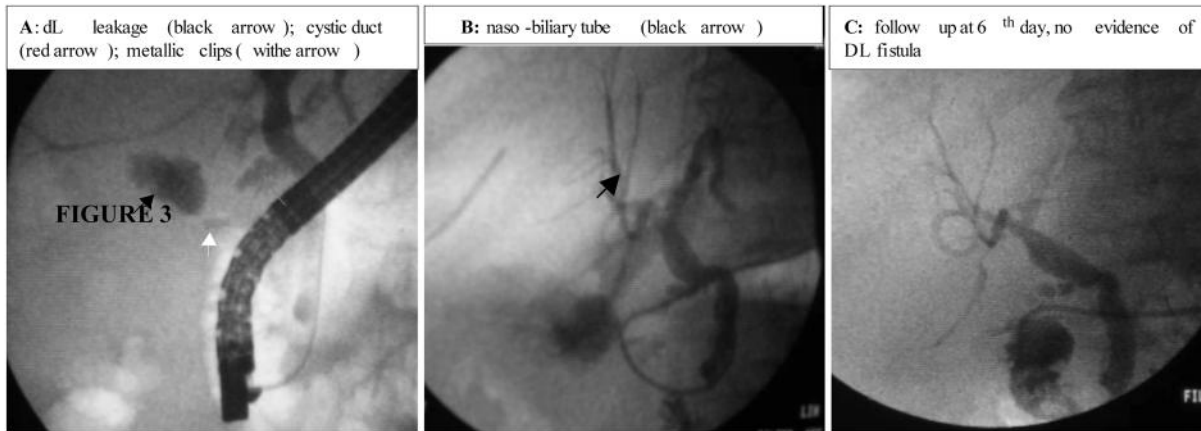


Fig. 3

in 7/42 (16.5%) patients: 3 cases of bleeding post-ES, 2 cases of cholangitis, and 2 cases of pancreatitis. All the complications were treated conservatively. The resolution of biliary leak was demonstrated by the ending of the percutaneous biliary drainage (fistula). It was achieved in all the patients endoscopically managed. Particularly, stent group achieved it after the 7<sup>th</sup> day (range 5-12), and the NBT group after the 12<sup>th</sup> day (range 5-14) ( $p < 0.001$ ). We removed the stent 48-hours after the ending of biliary fistula, and the NBT 48 hours after a negative trans-NBT cholangiography (Fig. 3 a,b,c). The percutaneous drainage was removed 24-hour later.

## Discussion

LC has become the gold standard treatment for patients with symptomatic gallstones. However, since LC replaced open surgery, there was a slight increase in the frequency of intra-operative complications, specially during the learning curve phase<sup>12,20</sup>. Bile duct injury identified during or after surgery as a bile leak occurs in 0.2% to 2% of cases; however, the frequency in large series after LC is less than 2%. With increasing experience, the rate of bile duct injury during LC had declined<sup>4,21-27</sup>. The main causes of bile ducts injuries are two: (1) anatomic alterations (i.e.: acute cholecystitis, previous surgery), and (2)

mechanical difficulty (i.e.: electrosurgical injury, harmonic scalpel, misplacement or displacement of the surgical clip(s) intended originally for the cystic-duct stump, or by disruption of the blood supply with consequent ischemic injury)<sup>1,22,28-30</sup>. However, it is possible to individualize risk factors patient and surgeon related (Table IV), and what a surgeon must to do to avoid the leak. The surgeon must remind: (1) good visualization, (2) minimal diathermy, (3) complete demonstration of anatomy, (4) early experienced help/conversion, (5) intra-operative cholangiography (IOC) when in doubt, (6) fundal traction, (7) lateral traction on Hartmanns pouch, (8) dissect posterolateral aspect of gallbladder, and (9) keep close to gallbladder wall. Leaks arise most commonly from the cystic duct stump. The next most common site of leak is a branch of the right hepatic duct (duct of Luschka). "Luschka leak" is the term used for an injury to this peripheral radical that occurs during dissection of a gallbladder from the liver<sup>28,31,32</sup>. For patients with persistent symptoms after a cholecystectomy that was converted intraoperatively from laparoscopic to open, the index of suspicion for bile leak should be high<sup>4,32,33</sup>. Braghetto et al. recorded 30% of biliary complications related to acute cholecystitis<sup>1</sup>. A Bile leakage is a complication that is associated with a potential for higher morbidity<sup>14</sup>. It requires a prolonged hospital stay, and sepsis may lead to several complementary procedures, even reoperations<sup>1,14,32, 34,35</sup>. Strasberg et al.

TABLE IV - Risk factors for bile duct injuries during cholecystectomy

Risk factors surgeon related	Risk factors patient related
Lack of experience (learning curve)	Empyema
Intraoperative bleeding	Acute and chronic cholecystitis
Misidentification of biliary anatomy	Long standing recurrent disease → fibrosis
Lack of recognition of anatomical biliary tree variations	Porcelain gallbladder
Errated dissection plane	Obesity
Improper interpretation of IOC	Previous surgery
Residual of common bile duct stones	Intrahepatic gallbladder



TABLE A - *US-sign of bile collection after cholecystectomy*


---

No collection
Well-circumscribed collection within the gallbladder fossa and adjacent perihepatic region that is easily misinterpreted
A complex or large perihepatic and subhepatic collection
Collection at other peritoneal sites (parietocolic, pelvic cavity)

---

TABLE B - *Clinical manifestation of bile leak*


---

External biliary fistula through the drain
Biloma (or localized collection)
Diffuse uncontaminated bile collection (bile ascites)
Diffuse bile peritonitis

---

included DL injury in *type A* <sup>36</sup>. The true frequency of the DL leaks after LC in the population is unknown and ranges from 1% to 50% according to published series <sup>14,32,35</sup>. Strasberg et al. reported 23% of *type A* injury, of which 15% were DL leaks, 4.4% of all of the iatrogenic bile duct injuries <sup>36</sup>. Deziel et al. described DL injuries in 10.4% of total bile duct injuries, Ramia et al. recorded an incidence of DL leaks in 0.15% of cases <sup>12,23,37</sup>. Sandha et al. reported an incidence Luschka duct injury of 13% <sup>5</sup>. A Strasberg *type-A* bile duct injury is not usually identified during a LC and clinically manifests in the first postoperative week. Among *type A* injuries, latent clinical symptoms are more common in the duct of Luschka than in cystic duct leakage <sup>5</sup>. Ultrasonography (US) is the first diagnostic tool, but under these circumstances, especially when it is done early after surgery, its accuracy is low, the results are equivocal, and errors are frequent <sup>1</sup>. According to Brooks et al. and Walker et al., positive results are <70% for early US but as reported by Braghetto et al. US could miss the presence of bile collection in 84% of cases <sup>1,14,38</sup>. However, as showed in several series when US is repeated or performed later than 5 days after surgery, confirmation of an intraabdominal collection is the rule (i.e.: subphrenic collections or diffuse peritonitis) because fluids were found even in the pelvic cavity <sup>1</sup>. There is a wide spectrum of US findings (Table I). ERCP as CT scan usually show also initial bile collection in all the cases <sup>1</sup>. The CT scan is an important diagnostic tool, even when the initial findings are normal. There are other diagnostic tools. HIDA scintigraphy is a dynamic study in which an ongoing bile leak may be detected. However, it provides suboptimal anatomic detail. A DL injury will be shown as extravasation of radionuclide from the gallbladder fossa. It is similar to ERCP or CT scan, and it provides more specific information about the location and cause of free fluid, with an accuracy of nearly 100% <sup>14</sup>. Intraoperative cholangiography is helpful in clarifying the anatomy of the biliary pedicle. However, some reports suggest that this procedure does

not prevent the injury and that it can provide a diagnosis of the lesions only in some cases <sup>14,19,39,40</sup>. Clinic manifestation of bile leaks occurs from the 3rd to 21st postoperative days (mean, 5 days), and it can appear in many ways relatively to the magnitude of the bile flow <sup>1,14,15,32,38,42</sup> (Table II). Shandha et al. classified the bile leaks as small (SL) or high (HL), on the severity or the degree of bile leak based on the amount of contrast observed fluoroscopically to extravasate from the ductal disruption <sup>28,43</sup>. The optimal treatment depends on the cause, the time of diagnosis, and the magnitude of the collections. Percutaneous drainage of fluid collections ("bilomas"), therapeutic biliary endoscopy, and surgery are the options. In several published series, surgery often was used as first-line. Surgery was associated with high morbidity (22-37%) and mortality (3-18%) <sup>4,8,23,32,33,41,43-46</sup>. The goal at ERCP is twofold: (1) to identify the site of bile leakage, and (2) to negate the transpapillary pressure gradient. The principle of therapy is a reduction in the pressure gradient across the sphincter of Oddi leading to preferential flow through the papilla and closure of the leak. The therapy consists of nasobiliary tube (NBT) alone, sphincterotomy alone, or placement of a biliary stent with or without sphincterotomy <sup>28</sup>. ERCP with ES and stent or NBT placement has become the treatment of choice, and in experienced hands, its efficacy is upper 80% <sup>55</sup>. Davids et al. reported a successful rate of endoscopic therapy in 90% of cases <sup>47</sup>. Ryan et al. in the 88% of patients who underwent ERCP resolved the leak <sup>54</sup>. NBT has the advantages of insertion without ES and repetition of cholangiography without another endoscopic procedure, but it is a source of discomfort for patients. Displacement of NBT is an adjunctive risk <sup>28</sup> [Table V]. In our experience, we preferred the NBT in patients with a severe leak (biliary drainage >180 ml daily) to monitoring the magnitude of bile flow daily and in DL leakage. While in case of no severe DL leaks we prefer the stent insertion (Fig. 1). The obstruction associated with ductal stones may increasing intraductal pressure. The frequency of LG bile

TABLE V - Endoscopic management of bile duct leaks

	Endoscopic sphincterotomy	Naso-biliary tube	Stenting
Advantages	<p>reduce the bile duct-duodenal pressure gradient maintained by an intact sphincter of Oddi</p> <p>divert bile away from the site of the leak</p>	<p>prevent stricture formation during healing</p> <p>provide visual confirmation of biliary decompression</p> <p>bile cultures can be done</p> <p>clogging in the tube (external drain) can be washed out</p> <p>facilitate repeat cholangiography</p> <p>allow gravity assisted drainage of bile from duct</p>	<p>eliminates outflow resistance offered by basal sphincter of Oddi pressure</p> <p>results in preferential draining of bile into the duodenum</p>
Disadvantages	Haemorrhage, pancreatitis, perforating	<p>Uncomfortable</p> <p>high risk of displacement (? "pig-tail" type)</p> <p>deprive patient of large amount of bile</p>	<p>associated with biliary obstruction, cholangitis</p> <p>stent migration</p> <p>requires second endoscopy for stent removal</p>

TABLE VI - Experimental strategies in management of bile ducts leaks

Product	Nitroglycerin	Poly-N-Acetyl glucosamine	Botulinum toxin
Origin		Biodegradable gel derived from marine diatom	Derived from <i>C. botulinum</i> , an anaerobic GPR
Physical characteristic		Solidifies at basic PH	—
Action modality	Calcium channel blockers and long-acting nitrates relax the sphincter	Safely plugs cystic duct stump leaks in animal studies	Paralyzes muscle (irreversible inhibition of Ach release) Induces relaxation of sphincter of Oddi
Somministration	Intravenous	May be performed endoscopically	Endoscopy
Studies	Sphincter dyskinesia	Human trials scheduled to start	Compared to stenting in animal studies

leak may be increased in patients with residual stones<sup>28</sup>. If ERCP fails or if bile collections persist even after this procedure, relaparoscopy can treat the cause of the bile leak. The successful rate of this method is only 70% because, with this technique, the treatment may be incomplete in patients with diffuse bile peritonitis, which is often associated with a delayed diagnosis<sup>15,32,38,55-57</sup>. In these cases a diffuse bile peritonitis associated with a high risk of sepsis occurs and a laparotomy is mandatory<sup>1</sup>. This approach could reach successful upper 70% of patients as the definitive treatment with good final outcome<sup>1,14,32,38</sup>. Kaffes et al. noted significantly more patients in the group treated by ES alone required further intervention to control the leak, surgery in particular, compared with the groups in which other forms of

endoscopic intervention were used. Stent insertion was superior to sphincterotomy alone without any influence on the diameter of the stent<sup>2</sup>. ERPC is unsuitable in presence of alteration of gastro-duodenal anatomy (i.e.: Billroth II gastrectomy or Roux-en-Y biliary-enteric anastomoses)<sup>53</sup>. CT/US guided percutaneous biliary drainage (PBD) can be performed in patients with no severe DL (i.e.: localized collections)<sup>56</sup>. The complications PBD related include: (1) fistula formation, (2) stricture formation, (3) haemorrhage and (4) bile leak secondary to liver puncture<sup>56</sup>. At present, topical application of nitroglycerine (which relaxes the sphincter of Oddi) or injection of botulinum toxin are experimental strategies, and data from clinical trials are needed before that can be considered for clinical practice<sup>59</sup> (Table VI).

## Conclusion

LC is the main treatment of gallstones, but is so diffuse as insidious. However, in all gallbladder pathologies, the surgeon must recognize the potential for biliary complications. The consequences are a major morbidity and prolonged hospitalization, high cost and medico-legal aspects, and stress. An adequate subhepatic drainage is needed to prevent postoperative complications. However, drains are not used routinely after LC, and early recognition of this complication is therefore more difficult. It is mandatory to make the diagnosis of this complication as early as possible so to treat with noninvasive procedures. In our opinion the most effective strategies is to avoid biliary leak during LC with experience.

## Riassunto

**INTRODUZIONE:** La colecistectomia videolaparoscopica (LC) è la procedura chirurgica più comune nel trattamento della patologia litiasica biliare e le fistole biliari rimangono tutt'oggi una importante causa di morbidità (0.2-2%). I dotti di Luschka (DL) sono piccolo duttuli biliari che originano dal lobo epatico destro, decorrono lungo il letto della colecisti e usualmente sboccano nei dotti biliari extraepatici. Le lesioni di questi dotti sono la seconda causa di fistola biliare post-colecistectomia videolaparoscopica. Scopo del nostro studio è eseguire una review della letteratura partendo dalla nostra esperienza endoscopica e chirurgica.

**ESPERIENZA PERSONALE:** 44 pazienti con coleperitoneo post-colecistectomia sono stati sottoposti ad ERCP, con successo della procedura in 42 pazienti (95.5%). Secondo la portata giornaliera della fistola, abbiamo suddiviso i pazienti in un gruppo a (< 180 ml/die), e b (> 180 ml/die). Il più frequente sito di leakage è stato il moncone cistico (94.5%), seguito dal DL (2 pazienti = 5.5%). Il posizionamento di una endoprotesi biliare da 10 Fr dopo sfinterotomia endoscopica è stato il trattamento iniziale. In 6 pazienti (14%) è stato posizionato un sondino naso biliare da 7 Fr. Considerando l'intention-to-treat, la ERCP ha avuto il 100% di successo per la risoluzione della fistola. Il tempo medio di chiusura della fistola è stato 8 e 12 giorni rispettivamente per il gruppo a e b. Complicanze precoci minori si sono registrate in 7/42 (16.5%) pazienti.

**MATERIALI E METODI:** Una review della letteratura usando MEDLINE con Medical Subject Heading terms è stata usata per evidenziare i lavori scientifici dell'ultimo quinquennio e le Cross-references sono state aggiunte alla ricerca.

**RISULTATI:** La ERCP è la metodica più comune nel trattamento delle fistole biliari post-colecistectomia. I pazienti con DL sono asintomatici, e molti leakage si appalesano solo dopo la prima settimana post-operatoria. La riduzione della pressione intra-duttale dopo sfinterotomia

e posizionamento di protesi o sondino naso-biliare dirige il flusso biliare preferibilmente verso la papilla, così da permettere la rapida guarigione della fistola. In una minore percentuale di pazienti è possibile un reintervento, con visualizzazione diretta del leakage e sua legatura. Il semplice drenaggio è limitato a casi isolati asintomatici e con fistola a bassa portata.

**CONCLUSIONI:** Le fistole biliari da lesione di DL sono frequenti dopo colecistectomia videolaparoscopica. La colangiografia intraoperatoria non è in grado di evidenziare tutti i DL. La ERCP con sfinterotomia endoscopica ed il posizionamento di protesi o sondino naso-biliare costituiscono oggi il trattamento più efficace e meno invasivo di questa complicanza.

## References

1. Braghetto I, Bastias J, Csendes A, Demandi A: *Intraperitoneal bile collections after laparoscopic cholecystectomy. Causes, clinical presentation, diagnosis, and treatment.* Surg Endosc, 2000; 14: 1037-41.
2. Kaffes AJ, Hourigan L, De Luca N, Byth K, Williams SJ, Bourke MJ: *Impact of endoscopic intervention in 100 patients with suspected postcholecystectomy bile leak.* Gastrointest Endosc, 2005; 61:269-75.
3. Trondsen E, Ruud TE, Nilsen BH, Marvik R, Myrvold HE, Buanes T, et al.: *Complications during the introduction of laparoscopic cholecystectomy in Norway. A prospective multicentre study in seven hospitals.* Eur J Surg, 1994; 160:145-51.
4. Barkun AN, Rezig M, Mehta SN, Pavone E, Landry S, Barkun JS, et al.: *Postcholecystectomy biliary leaks in the laparoscopic era: Risk factors, presentation and management.* Gastrointest Endosc, 1997; 45:277-82.
5. Sandha GS, Bourke MJ, Haber GB, Kortan PP: *Endoscopic therapy for bile leak based on a new classification: Results in 207 patients.* Gastrointest Endosc, 2004; 60:567-74.
6. Luschka H: *Die Anatomie d. Menschen in Rücksicht auf d. vols I, II, III.* Tübingen; Bedürfnisse d. Heilkunde, 1862-1867.
7. Champetier J, Davin JL, Letoublon C, Laborde Y, Yver R, Cousset F: *Aberrant biliary ducts (vasa aberrantia): Surgical implications.* Anat Clin, 1982; 4:137-45.
8. Mergener K, Strobel JC, Suhocki P, Jowell PS, Enns RA, Branch MS, Baillie J: *The role of ERCP in diagnosis and management of accessory bile duct leaks after cholecystectomy.* Gastrointest Endosc, 1999; 50:527-31.
9. Dvorak J, Sandler S, von Luschka H: *Pioneer of clinical anatomy.* Spine, 1994; 19:2478-482.
10. Ko K, Kamiya J, Nagino M, Oda K, Yuasa N, Arai T, Nishio H, Nimura Y: *A study of the subvesical bile duct (duct of Luschka) in resected liver specimens.* World J Surg, 2006; 30(7):1316-320.
11. Spanos CP, Syrakos T: *Bile leaks from the duct of Luschka (subvesical duct): A review.* Langenbecks Arch Surg, 2006; 391:441-47.
12. Ramia JM, Muffak K, Mansilla A, Villar J, Garrote D, Ferron J: *Postlaparoscopic cholecystectomy bile leak secondary to an accessory duct of Luschka.* JSLS, 2005; 9:216-17.



13. Rossi RL, Schirmer WJ, Braash J: *Laparoscopic bile duct injuries: Risk factors, recognition and repair.* Arch Surg, 1992; 127:596-602.
14. Walker AT, Shapiro AW, Brooks DC: *Bile duct disruption and biloma after laparoscopy cholecystectomy.* Am J Radiol, 1992; 158: 785-89.
15. Yi-Yin JI, Han-Ming CH, Chia-Sin N: *Biliary complications during and after laparoscopic cholecystectomy.* Hepatogastroenterology, 1997; 44:370-75.
16. Thompson RW, Schuler JG: *Bile peritonitis from a cholecystohepatic bile ductule: An unusual complication of cholecystectomy.* Surgery, 1986; 99:511-13.
17. Goor DA, Ebert PA: *Anomalies of the biliary tree: Report of a repair of an accessory bile duct and review of the literature.* Arch Surg, 1972; 104:302-09.
18. Misra M, Schiff J, Rendon G, Rothschild J, Schwaitzberg S: *Laparoscopic cholecystectomy after the learning curve. What should we expect?* Surg Endosc, 2005; 19:1266-271.
19. Braghetto I, Debandi A, Korn O, Bastias J: *Long-term followup after laparoscopic cholecystectomy without routine intraoperative cholangiography.* Surg Laparosc Endosc, 1998; 8:349-52.
20. Kauvar DS, et al: *Influence of resident and attending surgeon seniority on operative performance in laparoscopic cholecystectomy.* Journal of Surgical Research, 2005; 132:159-63.
21. Richardson MC, Bell G, Fullarton GM: *Incidence and nature of bile duct injuries following laparoscopic cholecystectomy: An audit of 5913 cases.* Br Journ Surg, 1996; 83:1356-360.
22. The Southern Surgeons Club: *A prospective analysis of 1518 laparoscopic cholecystectomies.* N Engl J Med, 1991; 324:1073-78. Erratum in: N Engl J Med, 1991; 325:1517-518.
23. Deziel DJ, Millikan KW, Economou SG, Doolas A, Ko ST, Airan MC: *Complications of laparoscopic cholecystectomy: A national survey of 4, 292 hospitals and an analysis of 77, 604 cases.* Am J Surg, 1993; 165:9-14.
24. McMahon AJ, Fullarton G, Baxter JN, O'Dwyer PJ: *Bile duct injury and bile leakage in laparoscopic cholecystectomy.* Br J Surg, 1995; 82:307-13.
25. Lee VS, Chari R, Cucchiars G, Meyers WC: *Complications of laparoscopic cholecystectomy.* Am J Surg, 1993; 165:527-32.
26. Moore MJ, Bennett CL: *The learning curve for laparoscopic cholecystectomy. The Southern Surgeon's Club.* Am J Surg, 1995; 170:55-59.
27. Rulli F, Grasso E: *Biliary peritonitis for duct of Luschka bile leak after laparoscopic cholecystectomy performed with a 10-mm harmonic scalpel.* Langenbecks Arch Surg, 2007; 92:111-12.
28. Jenkins MA, Ponsky JL, Lehman CA, Fanelli R, Bianchi T: *Treatment of bile leaks from cystohepatic ducts after laparoscopic cholecystectomy.* Surg Endosc, 1994; 8:193-96.
29. Peters JH, Ellison EC, Innes JT, Liss JL, Nichols KE, Lomano JM, et al. : *Safety and efficacy of laparoscopic cholecystectomy: a prospective analysis of 100 initial patients.* Ann Surg, 1991; 213:3-12.
30. Bailey RW, Zucker KA, Flowers JL, Scovill WA, Graham SM, Imbembo AL: *Laparoscopic cholecystectomy: experience with 375 consecutive patients.* Ann Surg, 1991; 214:531-41.
31. Mongenstern L, Berci G, Pasternak EH: *Bile leakage after biliary tract surgery.* Surg Endosc, 1993; 7:432-38.
32. Sefr R, Ochman J, Kozumplik L, Nrstjak J: *The role of relaparoscopy in the management of bile leaks after laparoscopic cholecystectomy.* Int Surg, 1995; 80:356-57.
33. Buanes T, Waage A, Mjaland O, Solheim K: *Bile leak after cholecystectomy significance and treatment: Results from the Norwegian Cholecystectomy Registry.* Int Surg, 1996; 81:276-79.
34. Soper N, Flye W, Brunt M, Stockman P: *Diagnosis and treatment of biliary complication of laparoscopic cholecystectomy.* Am J Surg, 1993; 165: 663-69.
35. Bastias J, Braghetto I, Debandi A, Csendes A: *Postoperative bile peritonium after laparoscopic cholecystectomy.* Hepatogastroenterology, 1993; 3:146.
36. Strasberg SM, Hetl M, Soper NJ: *An analysis of the problem of biliary injury during laparoscopy cholecystectomy.* J Am Coll Surg, 1995; 180:101-25.
37. McQuillan T, Manolas SG, Hayman JA, Kune GA: *Surgical significance of the bile duct of Luschka.* Br J Surg, 1989; 76:696-98.
38. Brooks D, Becker J, Lommors P: *Management of bile leaks following laparoscopic cholecystectomy.* Surg Endosc, 1992; 7:292-95.
39. Becci G, Sackier JM, Par-Partlow M: *Routine or selected intraoperative cholangiography during laparoscopic cholecystectomy.* Am J Surg, 1991; 161:355-60.
40. Phillips EH, Berci G, Carroll B: *The importance of intraoperative cholangiography during laparoscopic cholecystectomy.* Am Surg, 1990; 56:792.
41. Sicklick JK, et al.: *Surgical management of bile duct injuries sustained during laparoscopic cholecystectomy.* Ann Surg, 2005; 241(5): 786-95.
42. Flowers JL, Zucker KA, Groham SM: *Laparoscopic cholangiography.* Am Surg, 1992; 215:209-16.
43. Wills VL, Jorgensen JO, Hunt DR: *Role of relaparoscopy in the management of minor bile leakage after laparoscopic cholecystectomy.* Br J Surg, 2000; 87:176-80.
44. Slater K, Strong RW, Wall DR, Lynch SV: *Iatrogenic bile duct injury: The scourge of laparoscopic cholecystectomy.* Anz J Surg, 2002; 72:83-88.
45. ANZ J Surg, 2002; 72: 83-88: *Endoscopic management of post-operative bile leaks: review of 77 cases and report of two cases with biloma formation.* Am J Gastroenterol, 1991; 82:227-31.
46. Liguory C, Vitale GC, Lefebvre JF, Bonnel D, Cornud F: *Endoscopic treatment of postoperative biliary fistulae.* Surgery, 1991; 110:779-83.
47. Davids PHP, Rauws EAJ, Tytgat GNJ, Huibregtse K: *Postoperative bile leakage: Endoscopic management.* GUT, 1992; 33:1118-122.
48. Foutch PG, Harlan JR, Hoefer M: *Endoscopic therapy for patients with a post-operative biliary leak.* Gastrointest Endosc, 1993; 39:416-21.
49. Woods MS, Shellito JL, Santoscoy GS, Hagan RC, Kilgore WR, Traverso LW, et al.: *Cystic duct leaks in laparoscopic cholecystectomy.* Am J Surg, 1994; 168:560-63.
50. Bourke MJ, Elfant AB, Alhalel R, Kortan P, Haber GB: *Endoscopic management of post-operative bile leak (EMBL) in 85 patients [abst]* Gastrointest Endosc, 1995; 41:AB378.
51. Bjorkman DJ, Carr-Locke DL, Lichtenstein DR, Ferrari AP,

- Slivka A, Van Dam J, et al.: *Postsurgical bile leaks: Endoscopic obliteration of the transpapillary pressure gradient is enough*. Am J Gastroenterol, 1995; 90:2128-133.
52. Prat F, Pelletier G, Ponchon T, Fritsch J, Meduri B, Boyer J, et al.: *What role can endoscopy play in the management of biliary complications after laparoscopic cholecystectomy?* Endoscopy, 1997; 29:341-48.
53. Zhang JM, Yu SA, Shein W, Zheng ZD: *Pathogenesis and treatment to postoperative bile leakage: Report of 38 cases*. Hepatobiliary Pancreatic Dis Int, 2005; 4(3): 441-44.
54. Ryan ME, Geenen JE, Lehman GA, Aliperti G, Freeman ML, Silverman WB, et al.: *Endoscopic intervention for biliary leaks after laparoscopic cholecystectomy: A multicenter review*. Gastrointest Endosc, 1998; 47:261-66.
55. De Palma GD, Iuliano GP, Puizziello A, Manfredini S, Masone S, Persico G: *Biliary leaks after laparoscopic cholecystectomy. Results of the endoscopic treatment*. Minerva Chir, 2002; 57:123-27.
56. Asbun HJ, Rossi RL, Corwell JA: *Bile duct injury during laparoscopic cholecystectomy: Mechanism of injury, prevention and management*. World J Surg, 1993; 17:547-52.
57. Albasini JC, Aledo VS, Dexter SP, Martin J: *Bile leakage following laparoscopic cholecystectomy*. Surg Endosc, 1995; 9:1274-78.
58. Pala FX, Mendez EX, Gomez PS, Sintes MG: *Topical nitroglycerin: An alternative in the conservative treatment of biliary fistula*. Rev Esp Enferm Dig, 1996; 88:877-77.
59. Brodsky JA, Marks JM, Malm JA, Bower A, Ponsky JL: *Sphincter of Oddi injection with botulinum toxin is as effective as endobiliary stent in resolving cystic duct leaks in a canine model*. Gastrointest Endosc, 2002; 56:849-51.