

Soft tissue and tendon reconstruction after Achilles tendon rupture: Adipofascial sural turnover flap associated with cryopreserved gracilis tendon allograft for complicated soft tissue and Achilles tendon losses. A case report and literature review



Ann. Ital. Chir., 2006; 77: 361-368

Pier Camillo Parodi, Loredana Moretti, Giorgio Saggin*, Fabrizio De Biasio, Vincenzo Alecci*, Luca Vaianti**

Department of Plastic Reconstruction Surgery, University of Udine; (*) Department of Orthopaedic Surgery, Monfalcone "San Polo" Hospital; (**) Department of Plastic Reconstruction Surgery, San Donato Hospital, San Donato, all in Italy

Soft tissue and tendon reconstruction after Achilles tendon rupture: Adipofascial sural turnover flap associated with cryopreserved gracilis tendon allograft for complicated soft-tissue tendon losses. A case report and literature review

Achilles tendon rupture is often complicated by skin substance loss around the tendon, which is a poorly-vascularized site. Treatment may be conservative or surgical, but the former is not generally accepted by the orthopedic community and is reserved for selected cases, while surgery remains the most widely-used approach.

Soft tissue repair at this site is a crucial reconstruction problem, and becomes very complex if skin reconstruction has to be associated with a complex tendon repair.

The Authors describe a new approach to the repair of Achilles tendon substance loss compounded by a soft tissue defect, using a cryopreserved gracilis tendon allograft in combination with a distally-based adipofascial sural flap.

KEY WORDS: Achilles tendon, Distal leg reconstruction, Foot reconstruction, Sural flap, Tendon allograft.

Introduction

Spontaneous Achilles tendon rupture poses a reconstruction problem of great clinical interest because this is the third most common tendon tear ¹, and its correction involves the orthopedic surgeon. It occurs mainly in men with a sedentary lifestyle and generally aged between 40 and 50 years, though it can also occur in individuals who exercise regularly and in top-level athletes. Various mechanisms may trigger this lesion and clinical forms such develop form a series of concomitant causes but, generally speaking, Achilles tendon rupture

is attributable to direct basic mechanisms, occurring singly or in various combinations.:

- excessive stretching of the tendon under tension, as in falling from a considerable height, be it accidentally or in sports such as parachuting;
- forced dorsiflexion with a relaxed ankle, as in some of the typical movements of a basketball game;
- trauma directly affecting the tendon in tension, as in a soccer or football game.

The rupture usually occurs in the ribbon-like portion of the tendon, between 2 and 4 cm from the insertion in the heel, in an area characterized by a poor vascularization, as shown by Langergren's and Lindholm's studies ². Vascularization of the tendon depends strictly on the mesotendon, and the blood supply progressively declines over the years. Repeated injuries in the Achilles tendon area may also reduce the vascular supply to the region, thus facilitating a subsequent tendon tear. The inflammatory repair processes associated with enough to with-

Pervenuto in Redazione Aprile 2005, Accettato per la pubblicazione Luglio 2005.

For correspondence: Pier Camillo Parodi, MD, Università di Udine c/o Ospedale "San Michele", Dipartimento di Chirurgia Plastica Ricostruttiva, Piazza Rodolone 1, 33013 Gemona del Friuli (Udine) (e-mail: piercamillo.parodi@dsc.uninud.it).

stand very intense mechanical stress, and they further reduce the vascular supply to the area due to subsequent fibrosis. Treatment for Achilles tendon rupture may be conservative or surgical ³.

The conservative approach has been proposed by several Authors ⁴, who have reported excellent results after immobilizing the ankle 2,5 cm high for the next 4 weeks. This approach has not been widely accepted by the orthopedic community, however, and is reserved for selected cases, while surgical treatment remains the most common repair approach.

Surgery is ordinarily performed as an immediate or delayed emergency procedure. It varies from direct suturing to suturing with minimal access, using the peroneus brevis muscle, and a number of techniques proposed by various Authors ⁵⁻⁹.

In the case of inveterate rupture, the space between the two ends of the tendon is filled with scar tissue and treatment must be strictly customized, depending on the patient's clinical status, functional requirements, psychological compliance, age, and normal activities. There are many surgical techniques, which goes to show the difficulty of this reconstruction ^{5,10-13}. Many authors have reported using stents to repair inveterate rupture.

Wherever possible, all losses of tendon substance are repaired using the elongation flap of the residual proximal tendon. The techniques used to repair Achilles tendon tears often encounter significant complication. Nistor claims that 3% of fistulas, 2% of skin necrosis, and 2% of new ruptures ¹⁴. Achilles tendon repair is often complicated by skin substance loss around the tendon, requiring the exposure of the underlying tendon and the previously performed tenorrhaphy. This may be due to infection or the tension applied to the skin by the surgeon on a level with the rupture, at a poorly-vascularized site. Hence the frequent need to cover the previously-repaired tendon again, so as to facilitate tendon repair and avoid secondary infections involving the reconstructed tendon.

Soft tissue repair at such a site poses a crucial reconstruction problem, and becomes highly demanding if skin reconstruction has to be associated with reconstruction of the Achilles tendon region achieved by rotating a sural adipofascial turnover flap and reconstructing the tendon with a homologous gracilis tendon allograft, considered worthy of discussion given the original approach and particular characteristics of the reconstruction.

Case report.

A 35-year old male patient suffered rupture of the right Achilles tendon during while playing soccer. He had surgery elsewhere involving a vertical skin incision and rotation of the central band of the Achilles tendon (Bosworth's technique). Postoperatively, he developed a significant

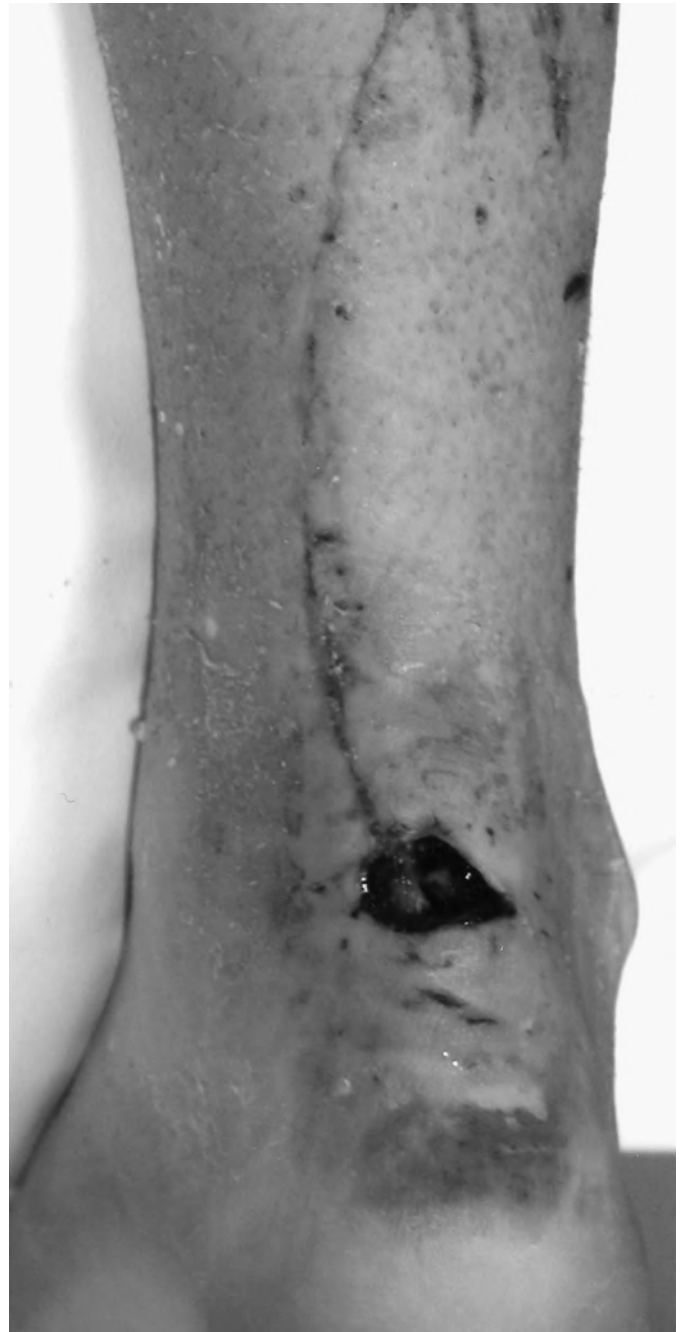

Fig. 1: Preoperative photograph showing the defect after Bosworth's reconstruction.

infection at Achilles tendon level, associated with skin necrosis, which was treated conservatively with local medication. Two months after surgery, the patient came under our observation with an extensive tendon gap associated with significant skin necrosis (Figs. 1 and 2) covering an area of approximately 2x2 cm.

The need to combine adequate tendon reconstruction and proper skin coverage in a single procedure led us to use a bank tendon graft (homologous gracilis tendon allograft of UFTB) associated with an adipofascial turnover sural flap. This would maximize the chances of

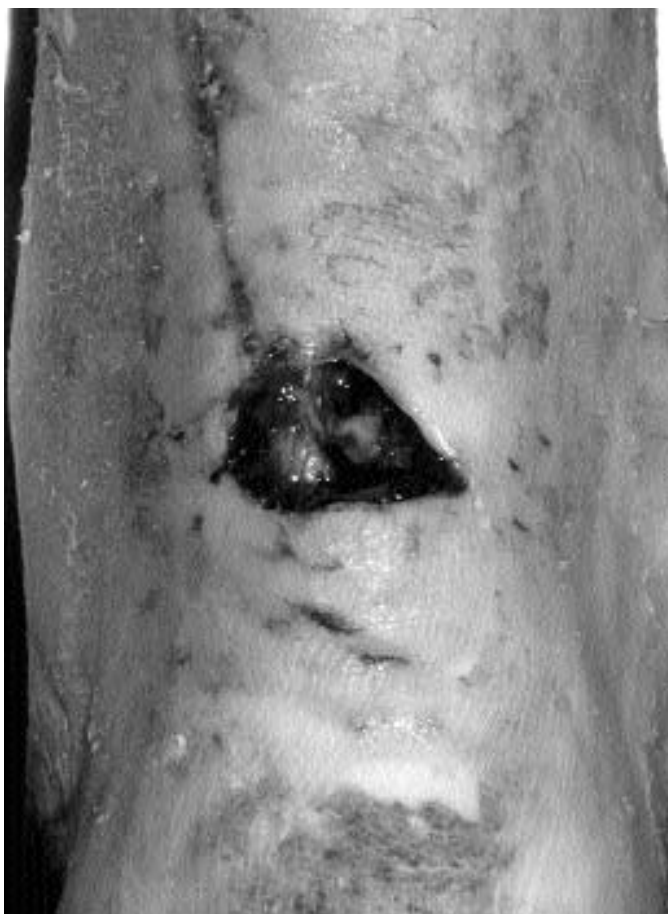

Fig. 2: Particular of the defect.

successful skin coverage in a mechanically-resistant tendon graft, while limiting cosmetic and functional sequelae in the donor area. Surgery was performed jointly by the orthopedic and plastic surgeons, was initially involved debridements, refreshing and curetting of the cutaneous edges of the exposure. Access was the previous surgical wound and dieresis was performed in layers. The Achilles tendon was isolated and its stumps (which were markedly separated) revealed severe degenerative phenomena. And extensive substance loss (Figg, 3 and 4). The stumps were adjusted and the Achilles tendon was reconstructed with a homologous gracilis graft passed through the two eyelets and sutured at the appropriate level of tension. The distally-based adipofascial sural flap was then prepared and used to cover the substance loss (Fig.5). The donor site was closed directly (Fig.6).

For the first month, a plastered boot was fitted and the foot was kept in a neutral position (90°). Thereafter, the patient was simply advised to start walking again, and no rehabilitation therapy was prescribed.

Two years on, the patient was resumed normal physical activities (Figs. 7 and 8) and the viability of the tendon graft was confirmed by MRI, performed two years after surgery with T1- and T2-weighted and FSE sequences, in the sagittal plan (Fig. 9).

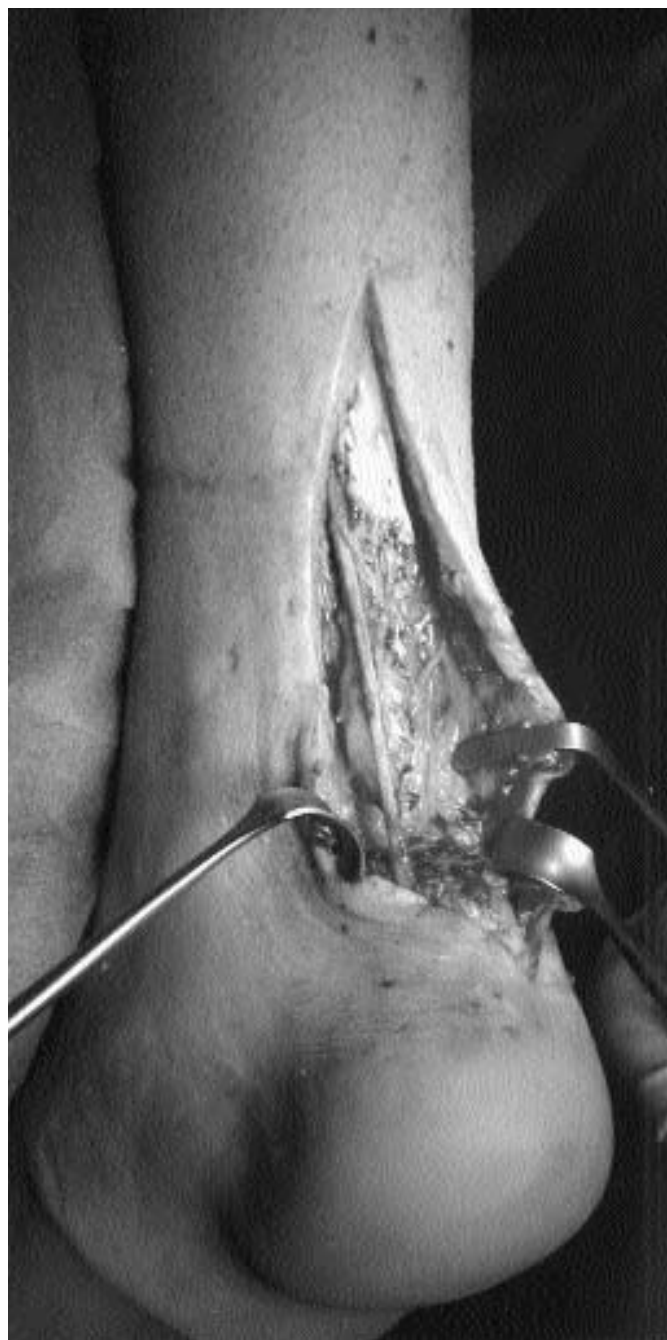

Fig. 3: Intraoperative photograph showing the tendon gap.

Discussion

Numerous techniques have been published for reconstructing composite defects of the Achilles tendon region in a single stage, and several authors have described cutaneous-tendinous composite reconstruction using local or microsurgical flaps¹⁵⁻¹⁹.

The particular anatomical aspects of the distal third of the leg (characterized by a thin layer of tegument, a relative absence of muscle tendon units than can be sacrificed for repair purposes, and an axial type vasculariza-

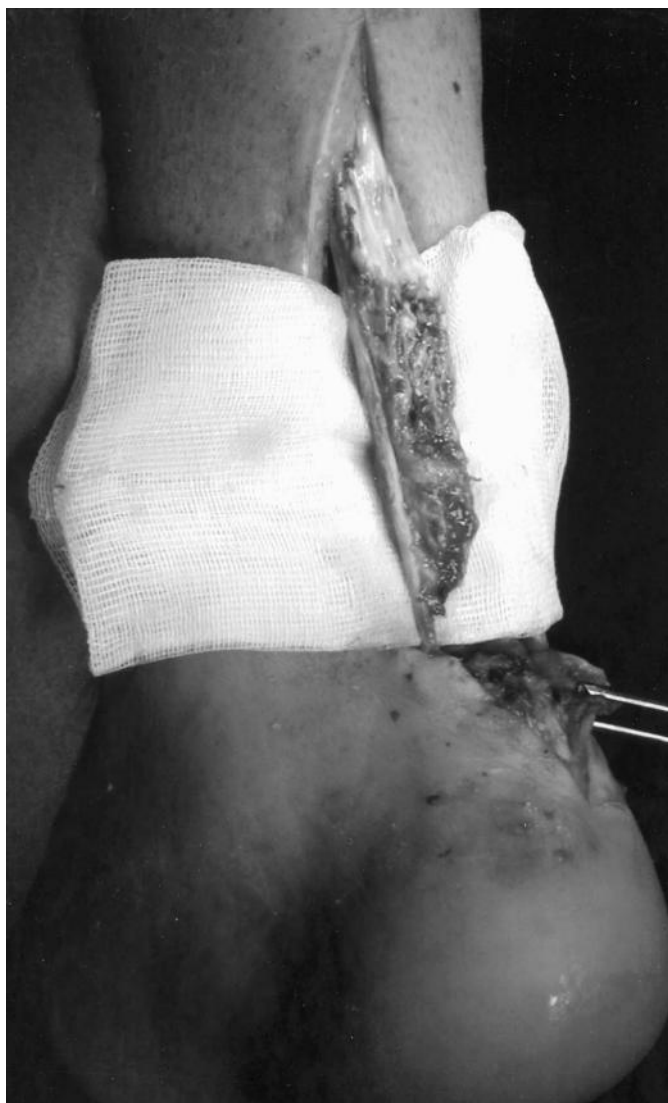

Fig. 4: Particular of the tendon substance loss.

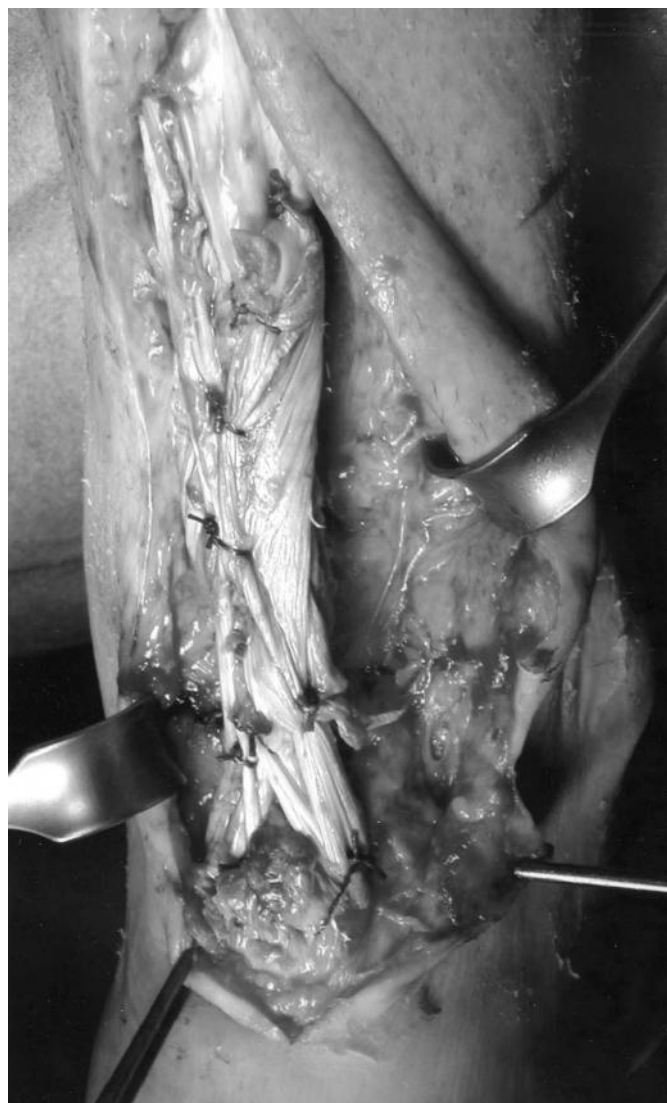

Fig. 5: Intraoperative photograph with the homologous gracilis graft secured in place and its covering by sural flap.

tion) make reconstruction with local flaps possible only for small defects, at the price of a high vascular risk and a large number of secondary complications.

In the case of larger composite deficits (a 3-5 cm tendon gap after prior reconstruction surgery), it is best to resort to microsurgical flaps, such as the fascia lata tensor muscle flap or the gracilis muscle flap¹⁷⁻²⁰.

Through microsurgical flaps are a viable alternative, they are also characterized by long operating times and requires a team trained in this specific type of reconstruction procedure.

Our extensive experience of soft tissue reconstruction in the distal third of the leg and Achilles tendon region using neurocutaneous and adipofascial turnover sural flaps^{21,22} induced us to use this technique in combination with a bank tendon graft to treat the particularly wide tendon gap in the case described here.

Used according to the appropriate indications, the sural flap has proved in our experience to be a viable alter-

native to the microsurgical repair of soft tissue substance loss of the distal third of the leg. It is indicated for minor and moderate tegumental substance loss without major bone deficits or significant infections.

By comparison with microsurgery, it has the advantage of being quick and easy to perform, with a limited morbidity in the donor area,

This flap is richly vascularized and given the vascular features of the fascial and neurocutaneous network, it can fit successfully into even very extensive tendon grafts. The flap's rich vascularization and great pliability make it possible to completely envelope the graft in an environment conducive to its implantation, minimizing the spaces around the graft and the risk of infection. These aspects are specially important if we consider the biological processes associated with the graft of a homologous tendon, characterized by a progressive revascularization and substitutive necrosis on the part of the host cell elements.

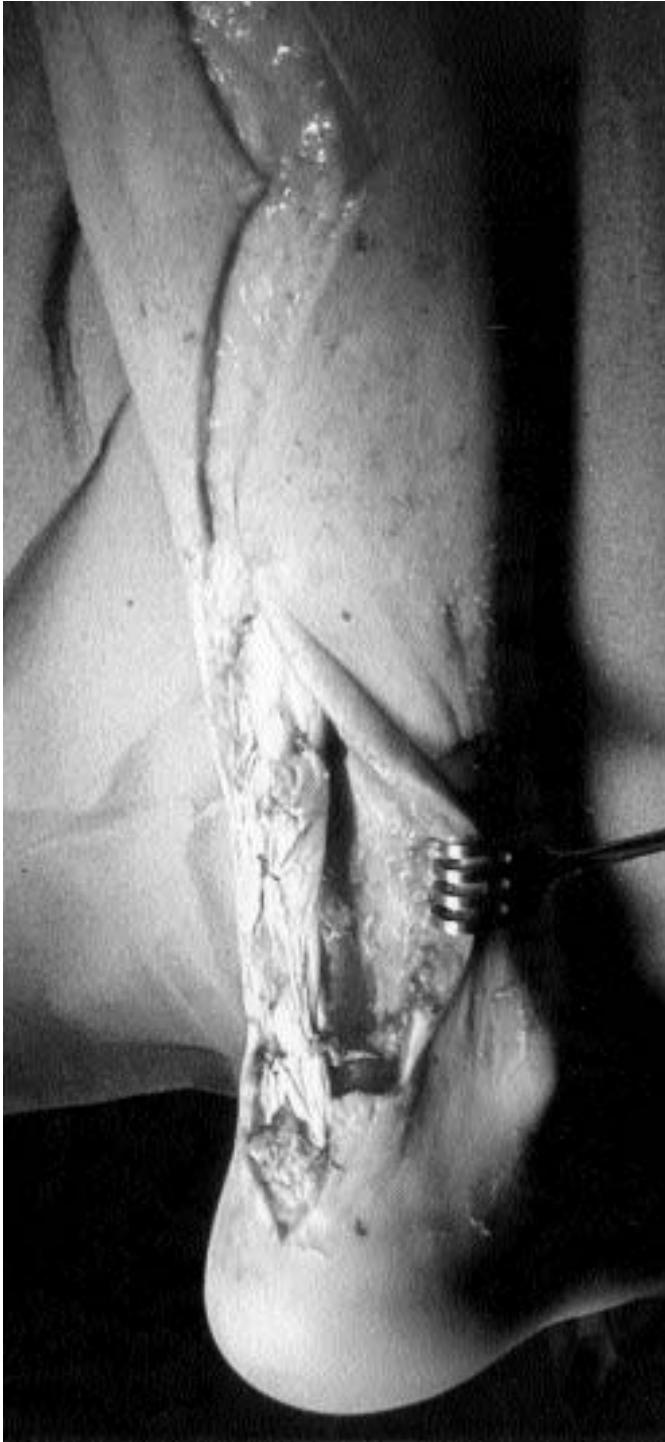

Fig. 6: Preparation of the adipo-fascial turnover sural flap.

We have opted for the adipofascial rather than the fascio-cutaneous variant because the former offers the following advantages:

- a lower morbidity and better cosmetic quality of the flap donor area, which is repaired by directly closing the margins with no stress. It is important to preserve the dermal plexus when raising the skin flaps, however, so as to avoid any necrosis of the flap's edges;

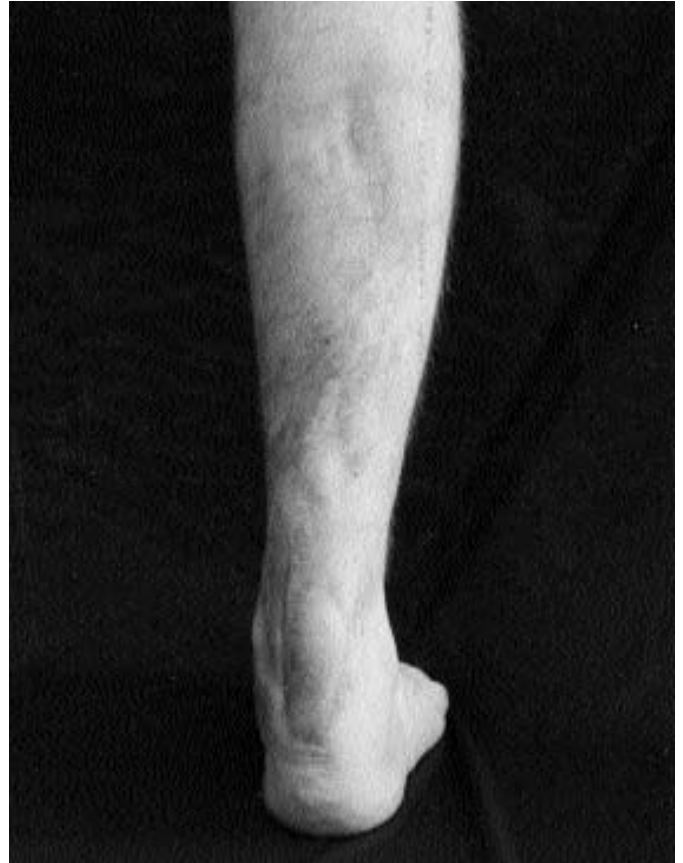

Fig. 7: Postoperative view at 1 year.

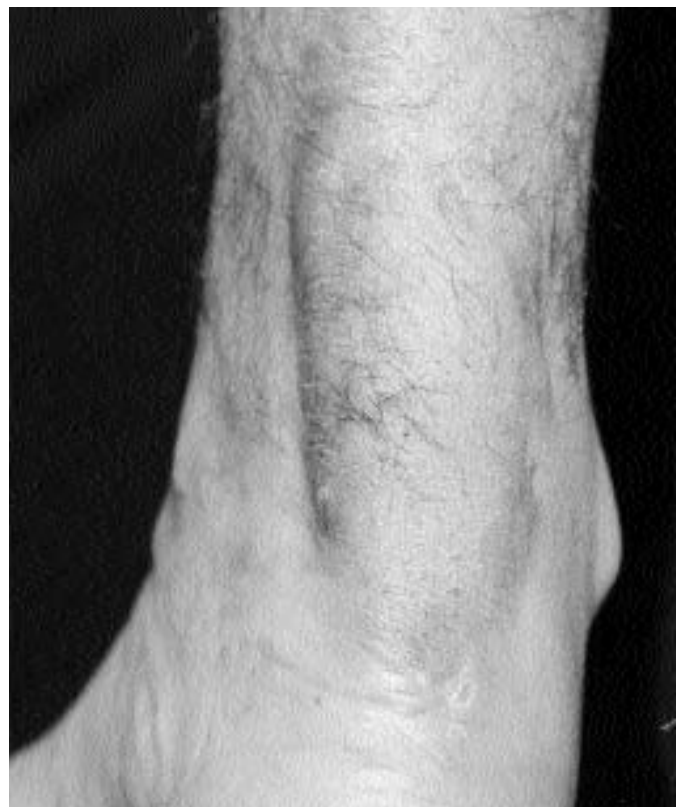


Fig. 8: Particular of the scar.

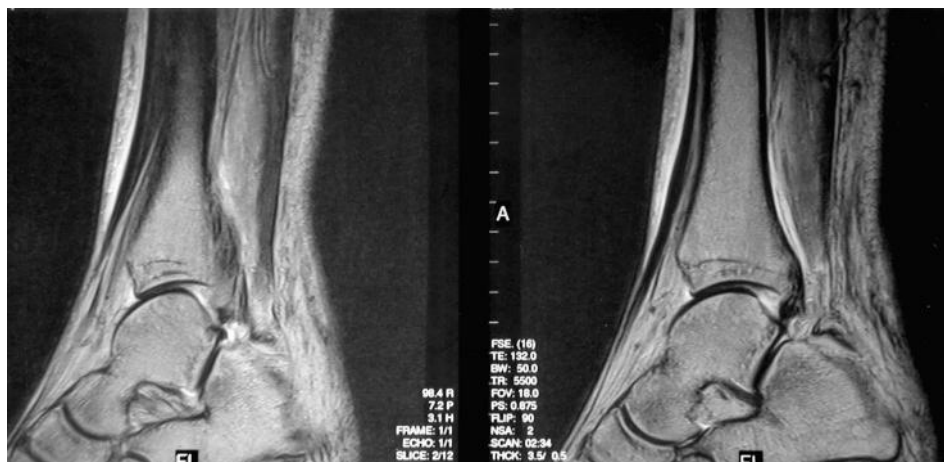


Fig. 9: Postoperative MRI at 2 years demonstrating a viable tendon in perfect continuity with the recipient tissue.

- a greater tissue malleability because not as thick as the fasciocutaneous flap;
- a less extensive postoperative edema because the flap can be turned over while preserving total pedicle width, without any twisting (which would cut off part of the circulation, consequently increasing venous congestion);
- a lower incidence of trap-door effect after any minor postoperative edema;
- a greater flap mobility because it can be turned over, making a possible to reach defects that need repairing up to 2-3 cm. more distally than is achievable by transposing the fasciocutaneous flap;
- a better functional recovery of the reconstructed region thanks to the interface between the subcutaneous adipose tissue and the moving muscle and tendon structures, which allows the better sliding;
- a better adaptation of the dermo-epidermid unit used to cover the flap thanks to the presence on the surface of the subfascial vascular plexus.

The choice of a cryopreserved tendon for tendon reconstruction stemmed from our experience of using these graft types in other orthopedic reconstructions (to repair cruciate ligaments and patellar tendon), and from data in the literature²³⁻²⁶.

The first case reported in the literature in which this type of allograft was used to reconstruct the Achilles tendon was published by Nellas et al²⁷.

There are no reports in the literature of any immune-reactions, since the allograft is screened for histocompatibility; the only residual risk concern HIV contamination^{28,29}.

Animal studies have shown that allografts experience a revascularization, repair and ligament formation process similar to that of autografts, with comparable functional results³⁰.

The rich vascularization and pliability of the adipofascial sural flap seems to make it ideal for fostering the inoculation of new vessels in the tendon graft, while simultaneously reducing the empty spaces and the risk of infection.

Riassunto

La rottura del tendine di Achille è spesso complicata da perdita di sostanza a livello cutaneo attorno al tendine zona a vascolarizzazione precaria. Il trattamento può essere conservativo o chirurgico, ma il primo non è generalmente bene accetto alla comunità ortopedica che lo indica solo per casi selezionati, mentre la chirurgia resta l'approccio più largamente adottato.

La riparazione dei tessuti molli in questa sede rappresenta un problema delicato, che diventa molto complicato se la ricostruzione cutanea deve essere associata con una riparazione complessa del tendine. Viene qui descritto un nuovo approccio per la riparazione di una perdita di sostanza del tendine di Achille associata ad un difetto dei tessuti molli, mediante il trapianto di tendine del muscolo gracile crioconservato in combinazione con un lembo surale adipofasciale a base distale.

References

- 1) Weiner AD, Lipscomb PR: *Rupture of muscles and tendons*. Min Med, 1956; 39:731.
- 2) Langergren C, Lindholm A: *Vascular distribution in the Achilles tendon: An angiographic and microangiographic study*. Acta Chir Scand, 1958-1959; 116:491.
- 3) Cetti R: *Operative versus nonoperative treatment of Achilles tendon rupture*. Am J Sports Med, 1993; 21:6.
- 4) Lea RB, Smith L: *Non surgical treatment of tendon Achilles rupture*. J Bone Joint Surg, 1972; 54-A:1398.
- 5) Bosworth DM: *Repair of defects in tendon Achilles*. J Bone Joint Surg, 1956; 38-A:111.
- 6) Krackow KA, Thomas SC, Jones LC: *A new stitch for ligament tendon fixation*. J Bone Joint Surg, 1986; 68-A:764.
- 7) Lindholm A: *A new method of operation in subcutaneous rupture of the Achilles tendon*. Acta Chir Scand, 1969; 117:261.
- 8) Lynn TA: *Repair of the torn Achilles tendon, using the plantaris*

- tendon as a reinforcing membrane. *J Bone Joint Surg*, 1966; 48A:268.
- 9) Ma GWC, Griffith TG: *Percutaneous repair of acute closed ruptured Achilles tendon*. *Clin Ortho*, 1977; 128:247.
- 10) Abraham E, Pankovich AM: *Neglected rupture of the Achilles tendon: treatment by V-Y tendinous flap*. *J Bone Joint Surg*, 1975; 57-A: 253.
- 11) Teyffer AP: *Traumatic rupture of the Achilles tendon: Reconstruction by transplant and graft using the lateral peroneus brevis*. *Orthop Clin North Am*, 1974; 5:89.
- 12) Wapner KL, Pavlock GS, Heckt PJ, et al: *Repair of chronic Achilles tendon rupture with flexor hallucis tendon transfer*. *Foot Ankle*, 1993; 14:443.
- 13) White RK, Kraynick BM: *Surgical use of peroneus brevis tendon*. *Surg Gynecol Obstet*, 1959; 108:117.
- 14) Nistor L: *Surgical and non surgical treatment of Achilles tendon rupture*. *J Bone Joint Surg*, 1981; 63-A:394.
- 15) Babu V, Chittaranjan S, Abraham G, Korula RJ: *Single-stage reconstruction of soft tissue defects including the Achilles tendon using the dorsalis pedis arterialized flap along with the extensor digitorum brevis as bridge graft*. *Plast Reconstr Surg*, 1985; 76: 177.
- 16) Fumarola A: *A one-stage reconstruction of a large defect of the tendon Achilles and the overlying skin*. *Br J Plast Surg*, 1985; 38:403.
- 17) Yuen JC, Nicholas R: *Reconstruction of a total Achilles tendon and soft tissue defect using on Achilles allograft combined with a rectus muscle free laps*. *Plast Reconstr Surg*, 2001; 107(7):1807-11.
- 18) Linton PC: *The combined medial and lateral gastrocnemius musculocutaneous V-Y island advancement flap*. *Plast Reconstr Surg*, 1982; 70:490.
- 19) Suominen E, Tukiainen E, Asko-Seljavaara S: *Reconstruction of the Achilles tendon region by free microvascular flaps: Nine cases follow-up*. *Acta Orthop Scand*, 1992; 63:482.
- 20) Feibel RJ, Jackson RL, Lineweaver WC, Buncke HJ: *Management of chronic Achilles tendon infection with musculocutaneous gracilis interposition free-flap coverage*. *J Reconstr Microsurg*, 1993; 9:321.
- 21) Parodi PC, et al: *Adipofascial and neurocutaneous flaps for the coverage of soft tissue defects of the limbs: Our personal experience*. *Hepatogastroenterology*, 2000; 47(suppl 122).
- 22) Parodi PC, De Biasio F, Vaienti L, Delorenzi F, Riberti C: *Distally based sural neuro-fasciocutaneous island flap to cover tissue loss in the distal third of the leg*. *Eur J Plast Surg*, 2003; 26:175-78.
- 23) Falconiero RP, Mallis MP: *Chronic rupture of a patellar tendon: A technique for reconstruction with Achilles allograft*. *Arthroscopy*, 1996; 12:5.
- 24) McNally PD, Marcelli EA: *Achilles allograft reconstruction of a chronic patellar tendon rupture*. *Arthroscopy*, 1998; 14:340.
- 25) Shino K, Kawasaki T, Hirose H, et al: *Replacement of the anterior cruciate ligament by an allogeneic tendon graft. An experimental study in the dog*. *J Bone Joint Surg (b)*, 1984; 66:672.
- 26) Shino K, Inoue M, Horibe S, Hamada M, Ono K: *Reconstruction of the anterior cruciate ligament using allogeneic tendon. Long-term follow-up*. *Am J Sport Med*, 1990; 18:457.
- 27) Nellas ZJ, Loder BG, Wertheimer SJ: *Reconstruction of an Achilles tendon defect utilizing an Achilles tendon allograft*. *J Foot Ankle Surg*, 1996; 35:144.
- 28) Buck BE, Malinin TI, Brown MD: *Bone transplantation and human immunodeficiency virus: An estimate risk of acquired immunodeficiency syndrome (AIDS)*. *Clin Orthop*, 1989; 240:129.
- 29) Buck BE., Resnick L, Shah SM, et al: *Human immunodeficiency virus cultured for bone: Implication for transplantation*. *Clin Orthop*, 1990; 251:249.
- 30) Shino K, Horibe S: *Experimental ligament reconstruction by allogeneic tendon graft in a canine model*. *Acta Orthop Belg*, 1991; 57 (suppl 2):44-53.

**FONDAZIONE
ROMA
CHIRURGIA**



*Saper fare - Fare sapere
Far sapere di saper fare
Euripide*

COSA C'È DI NUOVO IN CHIRURGIA

INCONTRI DEL VENERDÌ

diretti da: Mario M. Giordani

PER LA SERIE

"IL FUTURO HA UN CUORE ANTICO"

Memoria di: G. Picardi

INCONTRO DI STUDIO A DUE TEMI

IL TRAPIANTO DI FEGATO DA DONATORE VIVENTE

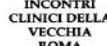SI È FATTO SEMPRE COSÌ EBM VERSUS TRADIZIONE

Venerdì 27 ottobre 2006 - ore 15.00

Palazzo Roccagiovine
Sede Romana della Fondazione Europea Dragan
Foro Traiano, 1/A (Piazza Venezia) - Roma

Con il patrocinio di:

Università degli Studi "La Sapienza" - Roma
Università degli Studi "Tor Vergata" - Roma
Università degli Studi "Campus Bio-Medico" - Roma
Società Italiana di Chirurgia
Associazione Chirurghi Ospedalieri Italiani
International College of Surgeons
Collegium Internationale Chirurgiae Digestivae, Italia
Società Italiana di Chirurgia Ambulatoriale e Day Surgery
Società Italiana di Chirurgia Oncologica
Società Italiana dei Trapianti d'Organo
Società Italiana di Endoscopia Digestiva
Società Italiana di Chirurgia Maxillo-Facciale
Società Italiana di Chirurgia Vascolare ed Endovascolare
Società Italiana di Chirurgia Tecnologica e Computer Assistita
Società Italiana di Chirurgia d'Urgenza e del Trauma
Società Medica del Lazio
Ordine dei Medici di Roma e Provincia
Assessorato alla Sanità della Regione Lazio
Associazione Stampa Medica Italiana



Venerdì 27 ottobre 2006 - ore 15.00 - 19.00

ore 15.00 *Ospitano: M.M. Giordani, A. Moraldi*

Per la serie

"IL FUTURO HA UN CUORE ANTICO"

Memoria di: C. Picardi

Intervengono: A. Gargiulo, M.M. Giordani

ore 15.15 **IL TRAPIANTO DI FEGATO
DA DONATORE VIVENTE**

SIMPOSIO promosso e moderato da: G. Tisone

Partecipano:

B. Gridelli: Lo stato dell'Arte

M. Angelico: Il punto di vista dell'epatologo

G. Simonetti: Imagin preoperatorio del donatore

H. Bourquain: Simulazione virtuale - Analisi del rischio

Il trapianto da vivente e lo Split: tecniche per l'espansione del pool dei donatori

Tavola Rotonda

Partecipano: S. Agnes, M. Angelico, P. Berloco,

B. Gridelli, G. Tisone

ore 17.15 **SI È FATTO SEMPRE COSÌ
EBM VERSUS TRADIZIONE**

SIMPOSIO promosso e moderato da: A. Moraldi

Partecipano:

R. Salvatori, M. Vaccaro: RX toracico pre-operatorio: sempre?

P. Guaitoli, F. Ciaraldi: Utilità della ginnastica vescicale: mito o realtà?

E. Procaccianti, A. Zullo: Antisecretivi nel post-operatorio: indispensabili?

S. Morini, M. Del Prete: Pancreatite acuta: terapia con somatostatina?

G.B. Doglietto, G. Pappalardo: Sondino nasogastrico p.o. in chirurgia del digerente: sempre?