

# Single incision laparoscopic surgery for hepatic hydatid disease

## Report of a case



Ann. Ital. Chir., 2013 84: 451-453

Published online 9 November 2012

pii: S0003469X12019549

[www.annitalchir.com](http://www.annitalchir.com)

Ilhan Karabacak, Savas Yuruker, Deniz Temel Seren, Tugrul Kesicioglu, Hamza Cinar, Necati Ozen

Ondokuz Mayıs University Medical Faculty, Department of General Surgery, Samsun, Turkey

### Single incision laparoscopic surgery for hepatic hydatid disease. Report of a case

*A 76 year-old female patient with a long-time history of nonspecific abdominal pain admitted to our hospital. Imaging studies showed 5 cm liver hydatid cyst between segments 2 and 3. She was recommended surgery and was informed about the details of single incision laparoscopic surgery (SILS). We performed single-incision laparoscopic pericystectomy. This is the first reported case of single-incision laparoscopic surgery for liver hydatid disease according to searching of English literature at the pubmed. SILS is a feasible surgical method for liver hydatid disease in selected patients with good outcome.*

KEY WORDS: Laparoscopic pericystectomy, Single-incision, Hydatid disease

This case was presented At Asian Pacific HPBA Congress Melbourne September 2011 as a medical poster

### Introduction

Surgical treatment is the gold standard for management of hepatic hydatid disease. Laparoscopic pericystectomy combines the advantages of radical surgical resection with those of minimally invasive surgery.<sup>1-3</sup> For good cosmetic appearance efforts aiming to reduce incision of laparoscopic surgery has been thought recently. For this purpose single-incision laparoscopic surgery (SILS) has gained significant momentum in different fields of surgical practice.<sup>4-6</sup> We report the first laparoscopic total pericystectomy for hepatic hydatid disease managed by SILS to our knowledge.

*Pervenuto in Redazione Aprile 2012. Accettato per la pubblicazione Luglio 2012*

*Correspondence to: Ilhan Karabacak, MD, Ondokuz Mayıs Üniversitesi Tıp Fakültesi, Genel Cerrahi Departmanı Samsun, TURKEY (e-mail: [ikarabacak@yahoo.com](mailto:ikarabacak@yahoo.com); [doktorhamza@yahoo.com](mailto:doktorhamza@yahoo.com))*

### CASE REPORT

A 76 year-old female patient with a long-time history of nonspecific abdominal pain admitted to Ondokuz Mayıs University Medical Faculty Department of General Surgery. Abdominal ultrasound (USG) and magnetic resonance imaging (MRI) demonstrated 5 cm hydatid cyst between segments 2 and 3 (Fig. 1). The case was appropriate for SILS. She was informed about the details of the SILS.

### Surgical Technique

Patient was placed in supine position. The surgeon stood between the spread legs of the patient. 2.5 cm complete umbilical skin incision was made. Two gauzes were inserted into the abdominal cavity through the incision. A special port, specifically designed for SILS, with three (One 10, and two 5 mm) trocars was used. After the creation of pneumoperitoneum we initially placed the gauzes under the cyst to prevent any contamination in rupture of cyst (Fig. 2). We have used a rigid 30°, 10-mm laparoscope during the most part of the procedure and 5-mm laparoscope during the

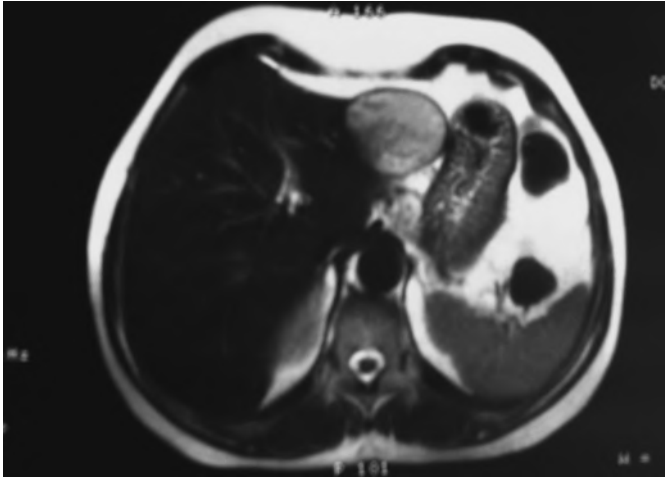


Fig. 1: 5 cm hydatid cyst between segments 2 and 3.

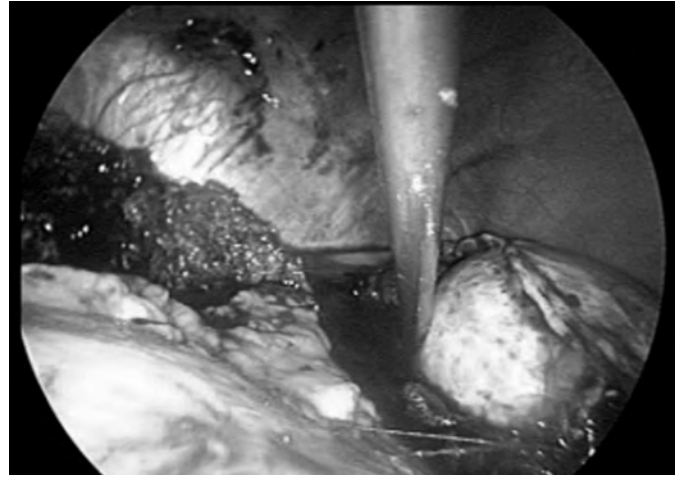


Fig. 4: introduction in the bag.

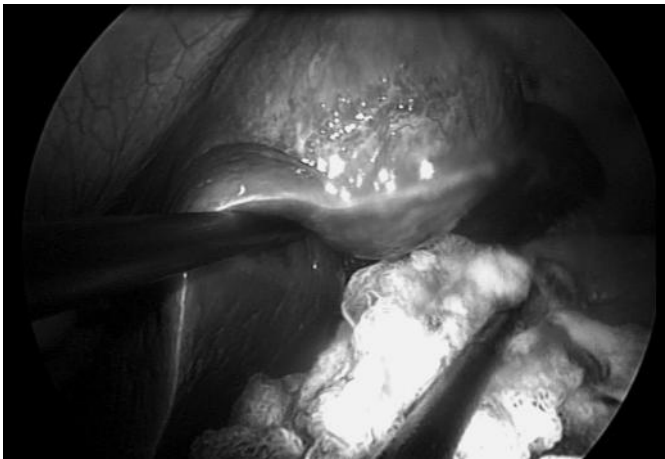


Fig. 2: Placed the gauzes under the cyst.

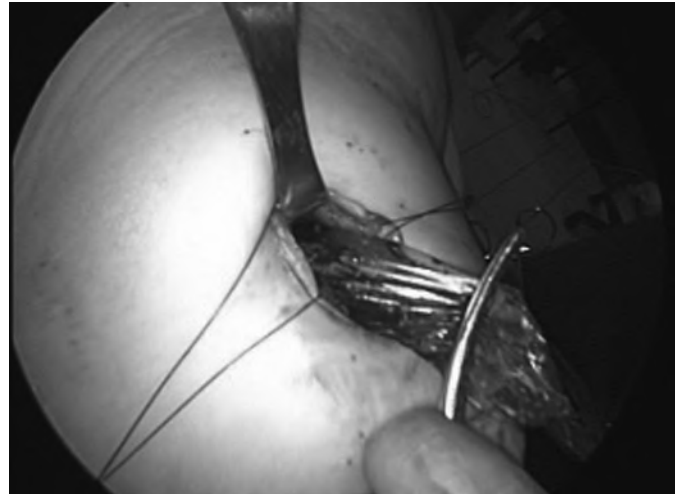


Fig. 5: Extraction with a bag.

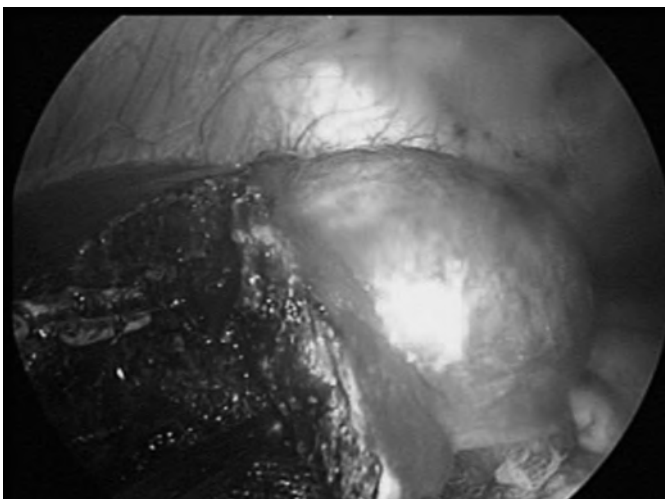


Fig. 3: Pericystectomy procedure.

retrieval of the cyst in endobag. A transection line was marked by electrocautery. Pericystectomy was performed using ultrasonic shears (Harmonic Scalpel, Ethicon). The resection was performed through healthy liver parenchyma adjacent to the pericyst (Fig. 3). The first assistant held the laparoscope and the second assistant held a surgical instrument through the right port. The surgeon used the ultrasonic shears, endoclips and scissors through the left port with the right hand. By this technique, the instruments did not cross each other. We elevated the liver under the transection line with an instrument which facilitated the transection and to get good exposure of the vessels and bile duct. We clipped the vessels and bile ducts if needed. We did not use any roticulating instrument during the procedure. Once the transection was completed the cyst with the liver tissue was removed with a retrieval bag that was introduced through the 10- mm trocar.

We enlarged the incision to 4 cm to remove the cyst since we did not want to open the cyst. Instead of enlarging the incision we could drain the cyst content when the cyst was in the bag. We did not prefer this technique since the operating room would be accepted contaminated if the cyst is opened. A single drain was placed. The procedure lasted 70 minutes. No perioperative complications occurred. The patient was discharged on postoperative day 4.

## Discussion

Surgery is still the mainstay of therapy of hydatid cysts. Several surgical approaches from simple drainage to radical liver resection have been described for hydatid cysts. Laparoscopic interventions are usually limited to cystotomy and drainage<sup>1-3</sup>.

The location of the cyst is a major factor that governs the type of the operation<sup>1</sup>. Cysts located to the left lateral segment seems to be an appropriate indication for laparoscopic pericystectomy. Successfully performed laparoscopic pericystectomy has been reported by Kapan et al<sup>1</sup>. Laparoscopic pericystectomy is a superior technique over cystotomy and drainage procedures, with the advantage of minimal risk of intra-abdominal contamination and anaphylactic reactions<sup>1</sup>.

Single incision laparoscopic pericystectomy prone to perioperative disadvantage as blood loss and bile leak during hepatic parenchymal dissection. Meticulous dissection with devices specifically designed for laparoscopic liver resection such as ultrasonic shears can avoid these problems.

We present the first single incision laparoscopic pericystectomy case for hydatid disease reported in English literature. It is a feasible and safe technique especially in patients with cyst located peripherally in the left lateral segment.

## Riassunto

Si riferisce su una donna di 76 anni con una lunga storia di dolori addominali non specifici ricoverata nel nostro ospedale. Lo studio per immagini ha mostrato una cisti idatidea di 5 cm tra i segmenti 2 e 3 del fegato. Le è stato consigliato il trattamento chirurgico informandola delle caratteristiche dell'approccio laparoscopico con incisione singola (SILS) procedendo quindi alla sua esecuzione.

Si tratta del primo caso di SILS per idatidosi epatica nella letteratura di lingua inglese controllata su Pub Med. Tale procedura si è dimostrato un metodo realizzabile per cisti epatica idatidea valido per pazienti selezionati e con un buon risultato.

## References

1. Kapan M, Yavuz N, Kapan S, Polat S, Goksoy E: *Totally laparoscopic pericystectomy in hepatic hydatid disease*. J Laparoendosc Adv Surg Tech A, 2004; 14:107-09.
2. Ertem M, Uras C, Karahasanoglu T, Erguney S, Alemdaroglu K: *Laparoscopic surgery of hepatic hydatid disease*. Dig Surg, 1998; 15:333-36.
3. Khoury G, Abiad F, Geagea T, Nabout G, Jabbour S: *Laparoscopic treatment of hydatid cysts of the liver and spleen*. Surg Endosc, 2000; 14:243-45.
4. Barbaros U, Sümer A, Tunca F, Gözkün O, Demirel T, Bilge O et al.: *Our early experiences with single-incision laparoscopic surgery: the first 32 patients*. Surg Laparosc Endosc Percutan Tech. 2010; 20:306-11.
5. Kobayashi S, Nagona H, Marabushi S, Wada H, Eguchi H, Takeda Y, et al.: *Single-incision laparoscopic hepatectomy for hepatocellular carcinoma: Initial experience in a Japanese patient*. Minim Invasive Ther Allied Technol. 2010; 19:367-71.
6. Cai Xiu-Jun, Zhu Zhi-yi, Liang Xiao, Yu Hong, Wang Yi-fan, He Ji-kai: *Single incision laparoscopic liver resection: A case report*. Chin Med J, 2010; 123:2619-20.

