

Congenital adrenal hyperplasia and Leydig cell tumor of testis.

Case report and review of literature



Ann. Ital. Chir., 2010 81: 445-448

Antonio Santoriello, Raffaella Benevento, Pasquale Petronella, Giuseppe Perna, Silvestro Canonico

Second University of Naples, School of Medicine, Unit of General and Geriatric Surgery, Naples, Italy

Congenital adrenal hyperplasia and Leydig cell tumor. Case report and review of literature

Adrenogenital Syndrome, more properly defined as Congenital Adrenal Hyperplasia (CAH), is related to the enzyme 21-beta-hydroxylase deficiency, with impaired glucocorticoids and aldosterone syntheses and increased ACTH synthesis.

This report describes a case of a monorchid patient suffering from Adrenogenital Syndrome and Leydig cell tumor of his testis. A right orchidectomy with implantation of testis prosthesis was performed, after informing the patient on the consequences of his castration and obtaining his consent. Histology showed a testis measuring 4x3x2.5 cm with a 6 cm long spermatic cord; there was a yellowish, well-defined nodule measuring 3.5x1.5 cm, surrounded by normal parenchyma. This nodule had morphologic and immunohistochemical characteristics of a Leydig cell tumor, even found in the spermatic cord; those cells showed positivity to inhibin, MART-1 and vimentin.

KEY WORDS: Adrenogenital syndrome, Leydig tumor, Orchidectomy, Testis tumor.

Introduction

Adrenogenital Syndrome, more properly defined as Congenital Adrenal Hyperplasia (CAH), is related to the enzyme 21-beta-hydroxylase deficiency, with impaired glucocorticoids and aldosterone syntheses and increased ACTH synthesis¹. The true frequency of testicular masses in patients with the CAH is unknown², even if it has been reported that testicular adrenal rest is a rare clinical condition³. The association of the CAH with Leydig cell tumor of the testis was described in 1940⁴ and few cases have been reported in literature⁴⁻¹². This report describes a case of a monorchid patient suffering from Adrenogenital Syndrome and Leydig cell tumor of his testis.

Case report

A 24-yr-old man was admitted to our Unit because of lower abdominal pain extended to the right groin and testis. He was suffering from "salt-wasting" CAH, diagnosed early in neonatal period, and was in therapy with hydrocortisone (40mg/die) and dexamethasone (0.25mg/die).

He was also affected from post-thyroiditis hypothyroidism, treated with levothyroxine, and phobic psychosis, treated with risperidone, carbamazepine and delorazepam. Seven years before, the patient underwent orchidectomy for abnormal twisting of left testis and lab tests showed aspermia. No bacteria, fungi and flagellate protozoa were checked by sperm-culture.

On palpation, right testis had hard consistency and irregular margins. Hormonal assay showed increase of plasma renin, FSH and 17-hydroxyprogesterone levels, low levels of DHEA-sulphate and total testosterone, borderline levels of free testosterone and delta-4-androstenedione, normal levels of aldosterone, prolactin and 17-beta estradiol.

Scrotal US, both standard grey scale and Colour Doppler, was performed by using 7.5 MHz linear array transducer

Pervenuto in Redazione: Luglio 2010. Accettato per la pubblicazione Agosto 2010

Correspondence to: Prof. Silvestro Canonico, Unit of General and Geriatric Surgery, Director, School of Medicine, Second University of Naples, Piazza Miraglia 2, 80138 Naples, Italy (e-mail: silvestro.canonico@unina2.it).

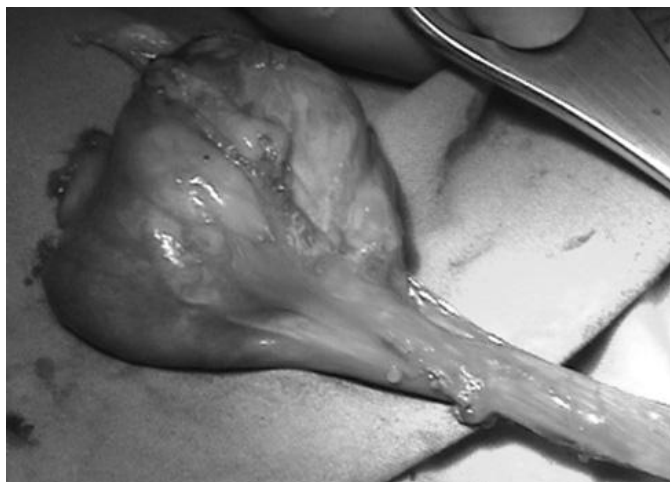


Fig. 1. Intraoperative picture of the right testis and spermatic cord.

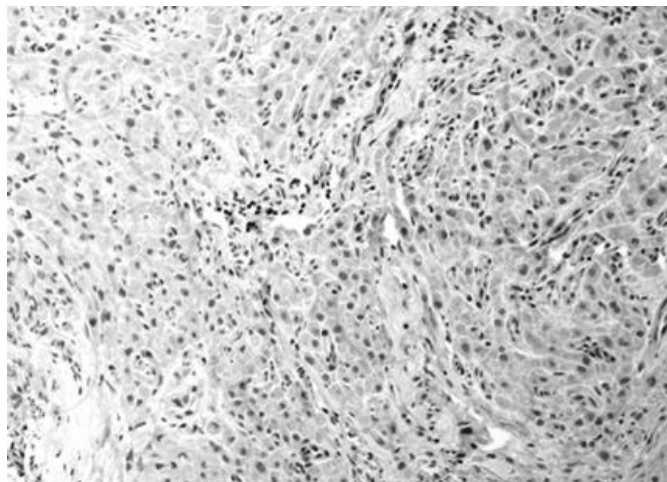


Fig. 4. Immunohistochemical specimen. Positivity to Vimentine.

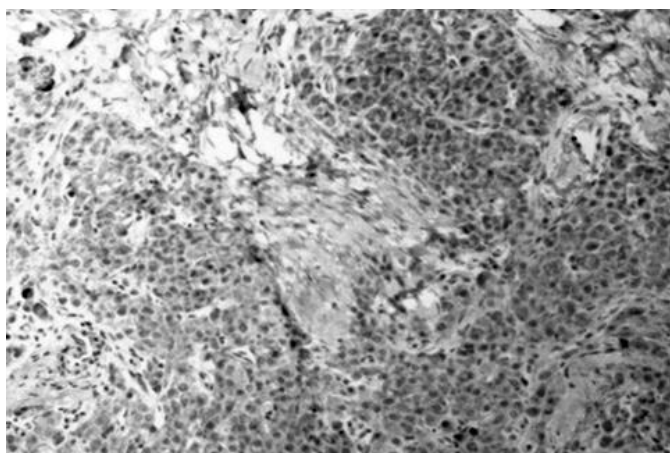


Fig. 2. Immunohistochemical specimen. Positivity to Inibine.

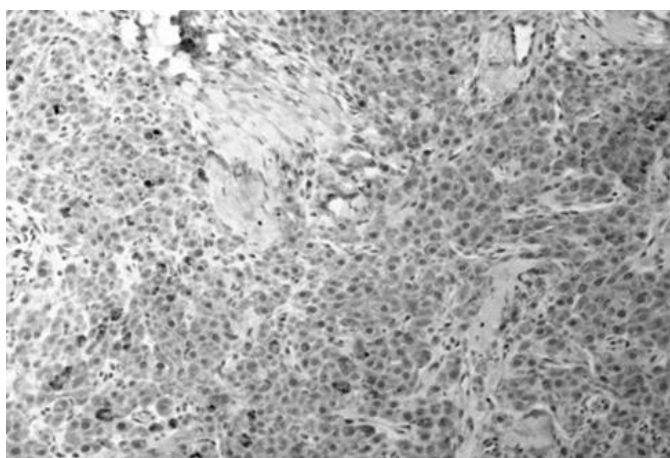


Fig. 3. Immunohistochemical specimen. Positivity to MART-1.

with a commercially available sonographic equipment (model AUC50 unit, Esaote Medical System, Genova, Italy). The US detected a moderate increase size of the

right testis that was dismorphous and inhomogeneous in consequence of a lesion measuring 40x27 mm, with irregular margins and poor vascularisation in peripheral portions. The patient underwent biopsies of testis with intraoperative histology that was negative for tumor. On the contrary, the postoperative immunohistochemical study showed a proliferation of large eosinophilic cytoplasm and low-grade nuclear pleomorphism cells which was organized in lobules, separated by fibrous septa. Therefore, the nodule was diagnosed as a Leydig cell tumor. Based on this diagnosis, a right orchidectomy (Fig. 1) with implantation of testis prosthesis was performed, after informing the patient on the consequences of his castration and obtaining his consent. The final histology showed a testis measuring 4x3x2.5 cm with a 6 cm long spermatic cord; there was a yellowish, well-defined nodule measuring 3.5x1.5 cm, surrounded by normal parenchyma. This nodule had morphologic and immunohistochemical characteristics of a Leydig cell tumor, even found in the spermatic cord; those cells showed positivity to inibine, MART-1 and vimentine (Figg. 2-4).

Discussion

The CAH is a congenital autosomal recessive disease, characterized by 21-hydroxylase deficiency, that leads to an inefficient cortisol and/or aldosterone production or function with over activity of the adrenal steroid-producing. Such deficient production of glucocorticoids and/or mineral corticoids results in rising levels of adrenocorticotrophic hormone (ACTH) which causes hyperplasia of the adrenal glands.

In 1940, Wilkins et al.⁴ described in a male patient the association of the CAH with a bilateral Leydig cell tumor. This cancer can be unilateral and histology is characterized by steroid secreting cells, above all testos-

terone but also estrogens or derivatives ^{9, 13}. In these patients immunohistochemical assay shows receptors of estrogens and progesterone in Leydig cells that are physiologically lacking of them ¹⁴. Leydig cell tumor is considered to be originated from the aberrant adrenal tissue descended with the testis along its artery ^{1, 9, 13, 15-17}. Therefore Gotoh et al. ¹⁸ suggested a careful adrenal gland evaluation in presence of a Leydig cell tumor. It represents 1-3% of testicular tumors and only 3-10% are bilateral ^{13, 19, 20}. There is no association with cryptorchidism and sometimes it was reported in patients with Klinefelter syndrome ^{9, 21, 22}. Moreover this cancer is also related to high levels of ACTH ¹, because the immunohistochemical assay demonstrates that tumor cells produce ACTH and angiotensin II receptors. Therefore it was hypothesized that angiotensin II and ACTH can assume an important role as Leydig tumor growth factors ²³.

Leydig cell tumor can occur at any age, even if the higher incidence is from 20 to 60 years of age and 25% of cases were reported in prepubertal age ¹³. Leydig cell tumor is always benign before puberty ^{9, 24}, with excellent prognosis after surgery ¹⁰, but in adults it may be malignant in 10-20% of cases (tumor size exceeding 5 cm in diameter) ²⁵ with an average survival time of 2-3 years after surgery ^{9, 13, 26}. Tumor metastases are rare and predictive factors that emphasize the invasive behaviour are represented by the presence of atypical cells, necrosis, lymphatic invasion, numerous and atypical mitoses, extra testicular invasion ^{9, 10, 13, 27-30}. The tumor is often asymptomatic and detected incidentally during US of testis ^{9, 10}. In prepubertal age, symptoms include precocious puberty with short stature ^{29,31}, while in adulthood, testicular swelling, gynaecomastia, female hair distribution, sexual disorders with infertility, azoospermia and decreased libido may be observed ³². Hormonal assay is modified in 20% of tumors, with increased estradiol and testosterone serum levels, leading to signs of masculinisation and acquisition of female sexual characteristics, in adults and in children respectively ^{33, 34}. Endocrine changes usually come before the finding of palpable testis swelling ^{19, 29}. So these changes can also be a helpful marker of tumor recurrence in the follow-up ⁹. Usual treatment is orchidectomy followed by chemotherapy and radiotherapy for malignant tumors, although a chemo- and radio-resistance have been reported ^{9, 13, 21, 22}.

Conclusions

Our case was a typical association between the CAH and a unilateral Leydig cell tumor. It was characterized by the particularity that in this young patient a testicle had been previously removed for its torsion. So the orchidectomy for Leydig cell tumor was a surgical castration with consequent serious psychological effects.

Riassunto

La sindrome adrenogenitale (CAH), meglio conosciuta come iperplasia congenita surrenalica, è correlata ad una deficienza dell'enzima 21-beta-idrossilasi con conseguente riduzione dei glucocorticoidi e della sintesi di aldosterone e con aumento della sintesi dell'ACTH.

Viene descritto il caso di un paziente monorchide sofferente di CAH e portatore di tumore delle cellule di Leydig nel testicolo.

Venne quindi eseguita un'orchidectomia destra con impianto di protesi testicolare dopo aver naturalmente informato il paziente delle conseguenze della castrazione e dopo aver ottenuto il suo consenso all'atto operatorio. L'esame istologico ha mostrato un testicolo di cm 4x3x2,5 con un funicolo spermatico di 6 cm. È stato riscontrato un ben definito nodulo di cm 3,5 x 1,5 di colorito giallastro, circondato da parenchima normale.

Tale nodulo aveva le caratteristiche morfologiche e immunoistochimiche del tumore delle cellule di Leydig malgrado fosse stato rinvenuto nel funicolo spermatico: tali cellule sono state riscontrate positive all'inibina, al MART-1 ed alla vimentina

References

- 1) Stikkelbroeck NMML, Otten BJ, Pasic A, Jager GJ, et al: *High prevalence of testicular adrenal rest tumors, impaired spermatogenesis, and Leydig cell failure in adolescent and adult males with congenital adrenal hyperplasia*. J Clin Endocrinol Metab, 2001; 86: 5721-728.
- 2) Proto G, Di Donna A, Grimaldi F, Mazzolini A, Purinan A, Bertolissi F: *Bilateral testicular adrenal rest tissue in congenital adrenal hyperplasia: US and MR features*. J Endocrinol Invest, 2001; 24: 529-31.
- 3) Pizzocaro A, Re T, Bonomi M, Vaninetti S, Travaglini P: *Testicular adrenal rest in a patient with congenital adrenal hyperplasia (CAH)*. J Endocrinol Invest, 1998; 21 (suppl. 7): 55.
- 4) Wilkins L, Fleishmann W, Howard JE: *Macrogonitosomia precox associated with hyperplasia of the androgenic tissue of the adrenal and death from corticoadrenal insufficiency*. Endocrinology, 1940; 26:385-95.
- 5) Srikanth MS, West BR, Ishitani M, Isaacs HJ, Applebaum H, Costin G: *Benign testicular tumors in children with congenital adrenal hyperplasia*. J Pediatr Surg, 1992; 27:639-41.
- 6) Rutgers JL, Young RH, Scully RE: *The testicular tumor of the adrenogenital syndrome. A report of six cases and review of the literature on testicular masses in patients with adrenocortical disorders*. Am J Surg Pathol, 1988; 12:503-13.
- 7) Willi U, Atares M, Prader A, Zachmann M: *Testicular adrenal-like tissue (TALT) in congenital adrenal hyperplasia: Detection by ultrasonography*. Pediatr Radiol, 1991; 21:284-87.
- 8) Avila NA, Premkumar A, Shawker TH, Jones JV, Laue L, Cutler GBJ: *Testicular adrenal rest tissue in congenital adrenal hyperplasia: findings at Gray-scale and color Doppler US*. Radiology, 1996; 198:99-104.

- 9) Ilkhanizadeh B, Taghizadieh M, Mahzad-Sadaghiani M, Noroozina F, Jahandideh B: *Bilateral Leydig cell tumor and male infertility: A case report*. Iranian Reproductive Med, 2005; 3:47-49.
- 10) Kim I, Young RH, Scully RE: *Leydig cell tumors of the testis a clinicopathological analysis of 40 cases and review of the literature*. Am J Surg Pathol, 1985; 9:177-192.
- 11) Hendry WS, Garvie WHH, Ah-See AK: *Ultrasonic detection of occult testicular neoplasms in patients with gynaecomastia*. Br J Radiol, 1984; 57:571-72.
- 12) Rich MA, Keating MA: *Leydig cell tumors and tumors associated with congenital adrenal hyperplasia*. Urol Clin North Am, 2000; 27:519-28.
- 13) Odabas Ö, Dilek FH, Avanoglu H, Atila MK, Yilmavaz Y, Aydins S. *Leydig cell tumor of the testis*. Eastern J Med, 1998; 3: 78-79.
- 14) Due W, Dieckmann KP, Loy V, Stein H: *Immunohistological determination of oestrogen receptor, progesterone receptor, and intermediate filaments in Leydig cell tumors, Leydig cell hyperplasia and normal Leydig cells of the human testis*. J Pathol, 1989; 157:225-34.
- 15) Graham LS: *Celiac accessory adrenal glands*. Cancer 1953; 6:149-52.
- 16) Falls JL: *Accessory adrenal cortex in the broad ligament. Incidence and functional significance*. Cancer, 1955; 8:143-50.
- 17) Dahl EV, Bahn RC: *Aberrant adrenal cortical tissue near the testis in human infants*. Am J Pathol, 1962; 40:587-98.
- 18) Gotoh A, Sugita Y, Maeda H, Umezu K: *Bilateral testicular Leydig cell tumor with adrenocortical adenoma: A case report*. Hinyokika Kyo, 1995; 41:149-52.
- 19) Leotta A, Lio SG: *Bilateral interstitial cell tumor of the testis: a report of a case in an adult*. Pathologica, 1994; 86:557-59.
- 20) Mostofi FK: *Testicular tumors*. Cancer, 1973; 32:1186-201.
- 21) Okada H, Fujioka H, Tatsumi N: *Klinefelter's syndrome in the male infertility clinic*. Hum Reprod, 1991; 14:946-52.
- 22) Ünlüer E, Özcan D, Altin S: *Malignant Leydig cell tumor of the testis: a case report and review of the literature*. Int Urol Nephrol, 1990; 22:455-60.
- 23) Hedi H, Claahsen-van der Grinten L, Otten BJ, et al: *Testicular Tumors in Patients with Congenital Adrenal Hyperplasia due to 21-Hydroxylase Deficiency Show Functional Features of Adrenocortical Tissue*. J Clin Endocrinol Metab, 2007; 92:3674-680.
- 24) Morse MJ, Whitmore WF: *Neoplasms of the testis*. In Campbell's Urology, vol 2, pp 1535-1582. Eds Walsh PC, Gittes RE, Perlmutter AD, Stamey TA. New York: WB Saunders Company; 1986.
- 25) Once de leon Roca J, Algaba Arrea F, Bassas, Villavicencio MH: *Leydig cell tumor of the testis*. Arch Esp Urol, 2002; 53:453-58.
- 26) Bertram K, Bratloff B, Hodges GF, Davidson H: *Treatment of malignant Leydig cell tumor*. Cancer, 1991; 68:2324-29.
- 27) Grem JL, Robins I, Wilson K: *Metastatic Leydig cell tumor of the testis*. Cancer, 1986; 48:2116-19.
- 28) Rosai J: *Ackerman's Surgical Pathology*. Edinburgh: Mosby; 2004.
- 29) Fletcher C: *Diagnostic Histopathology of Tumors*. London: Churchill Livingstone; 2002.
- 30) Mahon FB Jr, Gosset F, Trinity RG, Madsen PO: *Malignant interstitial cell testicular tumor*. Cancer, 1973; 31:1208-12.
- 31) Czernobilsky H, Czenobilsky B, Schneider HG, Franke WW, Ziegler R: *Characterization of a feminizing testicular leydig cell tumor by hormonal profile, immunohistochemistry and tissue culture*. Cancer, 1985; 56:1667-76.
- 32) Kondoh N, Koh E, Nakamura M: *Bilateral leydig cell tumor and male infertility: Case report*. Urol Int, 1991; 46:104-106.
- 33) Bercovici JP, Nahoul K, Ducasse M, Tater D, Kerlan V, Scholler R: *Leydig cell tumor with gynecomastia*. J Clin Endocrinol Metab, 1985; 61:957-62.
- 34) Freeman DA: *Steroid hormone-producing tumors of the adrenal, ovary and testes*. Endocrinol Metab Clin North Am, 1991; 20:751-66.