

Gastric GISTs.

Personal experience



Ann. Ital. Chir., 2007; 78: 283-289

Giuseppe Pietro Mingolla*, Paolo Antonino Riccio*, Romano Linguerri*, Michele La Donna*, Magda Zannelli**, Stefano Artuso*

AUSL Imola, Imola, Italy

*Unità Operativa di Chirurgia Generale - (Primario: dott. S. Artuso)

**Dipartimento di Anatomia patologica - (Primario: dott. R. Nannini)

Gastric GISTs. Personal experience.

BACKGROUND: With term GIST is now defined a group of mesenchimal tumours of the gastrointestinal tract expressing immunopositivity for kit protein kinase (CD117). Surgical therapy remains the gold standard for these rare tumours. Imatinib Mesylate (STI-571) is a potent inhibitor of Kit Kinase activity and different reports demonstrated its efficacy in unresectable or metastatic Gists. Aim of the paper: To value the incidence of GISTs among gastric mesenchimal neoplasms and analyzed their clinical presentation, prognostic parameters and surgical treatment. The response to Imatinib Mesylate in a case of metastatic GIST is then valued.

METHODS: Twelve cases of gastric mesenchimal neoplasms are retrospectively reviewed and tested by CD117 immunopositivity identifying 8 GISTs. The median follow-up was 37 (range 7-120) months. We describe in details the case of a metastatic Gist treated for 15 months with Imatinib Mesylate.

RESULTS: The 67 per cent of mesenchimal gastric tumours were CD117+. Gastrointestinal bleeding was the most common presenting symptom. The 50% of patients with malignant GISTs had a palpable abdominal mass at diagnosis. All tumors < 5 cm in diameter had a mitotic count (MC) < 5/50 high-power fields (HPFs) except a case of high grade leiomyosarcoma. Surgical therapy was complete tumour resection with free margins.

No recurrence was observed in lesions < 5cm and < 5 mitosis/50 High Power Fields (HPFs). A good response to Imatinib Mesylate was reported in a metastatic GIST.

CONCLUSION: The surgeon's role in gastric Gist's treatment is to achieve a complete cancer resection with free margins. In advanced lesions, even in presence of hepatic metastases, surgical resection of the mass is indicated because is possible to obtain a stabilization or a partial remission with Imatinib Mesylate palliative treatment in some patients.

KEY WORDS: Gastric stromal tumour, GIST, Imatinib Mesylate.

Introduction

The term GIST (GastroIntestinal Stromal Tumours) was previously used to designate a group of gastrointestinal neoplasms of mesenchimal origin that electronic microscopy and immunochemistry differentiated in smooth muscle (leiomyomas-leiomyosarcomas), neural (schwannomas), mixed neural-myoid or undefined phenotype. GANT (Ganglionic Autonomic Nerve Tumours) were a small group of neoplasias resembling features of autonomic nerve cell.

GIST is now defined as a particular intestinal mes-

enchimal tumor that probably originates from interstitial cell of Cajal or its precursor and includes about 80% of the neoplasias listed above ¹.

Interstitial cell of Cajal (ICC) is a pace-maker that regulate peristaltic movement of the gastrointestinal tract. The discovery comes from Hirota's experience who in 1998 found in a high number of GISTs the expression of a tyrosine kinase receptor called Kit (CD117), codified by c-kit proto-oncogene, after studies on mutant mice that lacking this protein showed depletion of ICC ².

It was common knowledge that an activated kit protein causes Chronic Myeloid Leukaemia (CML). Imatinib Mesylate (STI-571) is a drug that inhibits this protein activity and is effective in CML therapy. The possibility that an activated Kit protein was also implicated in carcinogenetic mechanism of Gists led to the experimental use of this drug in a patient with metastatic GIST in 2001. The results were encouraging. Since that

Pervenuto in Redazione Settembre 2006. Accettato per la pubblicazione Febbraio 2007.

For correspondence: Dott. Giuseppe Pietro Mingolla, via Cardelli n. 8, 40026 Imola (Bologna) (e-mail: pieromingolla@libero.it).

different studies demonstrated the efficacy of Imatinib Mesylate in unresectable or metastatic GISTs, opening new horizons in the treatment of these neoplasms. The Authors report their personal experience in the treatment of gastric GISTs underlining the importance of a correct diagnosis and treatment. A case of malignant metastatic GIST that was treated for 15 months with Imatinib Mesylate with good response is described.

Materials and methods

In our Unit 12 cases of gastric mesenchymal neoplasms were treated from 1993 to 2003. The clinical presentation, tumor location, pathology (immunohistochemistry, size and mitotic count), surgical treatment and follow up are illustrated in Table I. In collaboration with pathologists all cases are identifying as GISTs all the neoplasms CD117 positive. We classified as probably benign tumors <5 mitoses/50 HPFs and size <5cm, as malignant lesions >5 mitoses/50 HPFs and >10cm and as border-line or with uncertain malignant potential all neoplasms with size more than 5cm but no greater than 10cm and no more than 5 mitoses /50HPFs. All the patients were interviewed and the median follow up was 37(range 7-120) months.

Results

The 67% of gastric stromal tumors were CD117+ and can be considered real GISTs (8 cases). Two leiomyomas, one high grade leiomyosarcoma and a case with neural phenotype were CD117-.

The most common presenting symptom was gastrointestinal bleeding (6 cases), sometimes the tumor was incidentally detected during gastroscopy for dyspepsia (4 cases). Two patients already presented a palpable abdominal mass at diagnosis.

The 50% of GISTs were malignant.

One case presented multiple liver metastases while in other two patients tumor was extended to the spleen and transvers colon respectively.

All the neoplasias <5cm had less than 5 mitoses except one 3.5 cm high grade leiomyosarcoma, confirming the good correlation of the two parameters.

In tumors <5cm we preferentially performed a wedge resection with wide margins (4 cases); in larger or distal tumors a partial gastrectomy was performed (5 cases); we made total gastrectomy only for voluminous or iuxta-cardia lesions (3 cases). Removal of spleen (1 case) and transvers colon (2 cases) for tumor infiltration was necessary in three cases.

All patients with benign lesions are alive except one died for stroke 13 months after surgery. Among three non metastatic malignant GISTs, two recurred after 13 and 25 months, one is disease free after 14 months follow up.

Two patients underwent Imatinib Mesylate treatment: of these one was a recurrent GIST but for him we have a limited follow up (1 month); the other had liver metastases at surgery and is living since 15 months of therapy. We report this last case.

Case report

A 69 year old man presented in October 2002 with a palpable, huge mass filling all the upper and left abdomen. Computerized tomography revealed a larger fluid filled pseudocyst (>20cm) adjacent the greater curvature and another smaller (7 cm) similar lesion adjacent lesser curvature.

Pancreas was compressed but not infiltrated. Only in venous phase some small lesions with diameter <1cm compatible with metastases could be appreciated in liver. Gastroscopy and barium enema were negative for endoluminal lesions of stomach and colon. A barium swallow showed a deformity in gastric wall with normal mucosa compatible with external invasion.

At surgery two large greyish, with thick wall, blood filled pseudocysts originating from stomach were detected; tumor invaded transvers colon. A tissue sample was sent for pathologic examination and revealed a high grade sarcoma. A distal gastrectomy with resection of transvers colon was performed. Liver surface presented on both lobes multiple small nodules of about 1 cm in diameter and one was resected for pathologic examination.

Pathology revealed a gastric malignant Gist (>10 mitoses/50HPFs) with liver metastases (Figure 2 and 3). In December 2002 the patient started treatment with Imatinib Mesylate at the dose of 400mg daily without significant side effects.

A first control with magnetic resonance 4 months later showed that liver metastases were stable and treatment was continued. A further control at 10 months revealed a decrease in number (11 versus 14) and size of liver metastases without signs of peritoneal recurrence.

The patient is ongoing treatment and is in good condition without important side effects since 15 months of therapy.

Discussion

GISTs are mesenchymal tumors that probably originate from interstitial cell of Cajal or its precursor and express immunopositivity for Kit protein (CD117).

Mesenchymal neoplasms of smooth muscle origin (leiomyomas, leiomyosarcomas) and schwannomas are CD117- but positive for smooth muscle actin (SMA) and S-100 respectively.

Gant present immunohistochemical and molecular pattern similar to GISTs and cannot be considered as a separate entity ¹.

TABLE I – *Mesenchimal gastric tumours: Personal experience (1993-2003).*

Name, age, sex	Site Clinical presentetation	Surgical therapy	histology	Size cm	mitoses n/50HPFs	Follow up months
L.A, 40, F	Antrum Gastrointestinal bleeding	Partial gastrectomy	Vimentin+ S.M.A.+ CD117- leiomyoma	4,5	1	120, Alive
V.G, 70, F	Corpus Incidentally detected	Wedge resection	S.M.A+ Desmin+ CD34- S100- leiomyoma	2,6	<2	24, Alive
C.M.T,	Dyspepsia	Wedge resection	Actin+ CD34- Desmin- Vimentin- Chromogranin- NSE- S100- leiomyosarcoma	3,2	10	7, Alive
Z.L, 73,	Antrum Dyspepsia	Partial gastrectomy	Vimentin+ S100+ NSE+ Cd34- S.M.A- Desmin- Schwannoma	3,5	<5	63, Alive
A.A, 67, F	Corpus Incidentally detected	Wedge resection	CD34+ S.M.A.- S100- Chromogranin- benign GIST	2,5	<2	60, Alive
P.D, 79, F	Iuxta cardia Gastrointestinal bleeding	Total Gastrectomy	Vimentin+ CD34+ S100- S.M.A.- benign GIST	4,5	4	13, died for stroke
S.P 67aa. M	Antrum Gastrointestinal bleeding	Partial gastrectomy	CD34+ S100- NSE+ S.M.A-/+	4,5	<5	23, Alive
P.L 87 F	Angulus Gastrointestinal bleeding	Wedge resection	Cd34+ NSE+ S.M.A+ S100- benign GIST	3,5	2	42, Alive
V.B, 80aa, M	Iuxta cardia Gastrointestinal bleeding	Iuxta cardia Gastrointestinal bleeding	CD34+ Actina m.l.+ Vimentin + S100-/ + Desmin- NSE- malignant GIST	7	>10	52, Alive peritoneal recurrence liver metastases
S.C 69 M	Antrum Dyspepsia Transvers colon invasion Liver metastases	Partial gastrectomy Transvers Colon resection	CD34+ NSE+ S.M.A- Desmin- 100- malignant GIST	21	>10	15, Alive Therapy with Imatinib Mesylate
C.C 68aa M	Dispepsia Palpable tumour Transvers colon invasion	Gastroresezione Rezezione colon trasverso	S100+/- Actina m.l./- malignant GIST	10	>5	14, Alive Therapy with Imatinib Mesylate since 1 month
G.C, 48, F	Iuxta cardia Gastrointestinal bleeding	Total Gastrectomy	NSE+ CD34+ S100-/ + S.M.A.- Desmin- ChromograninaA- malignant GIST	8	>5	14, Alive

S.M.A= Smooth Muscle Actin; HPFs= High Power Fields; NSE: neuron specific enolase.

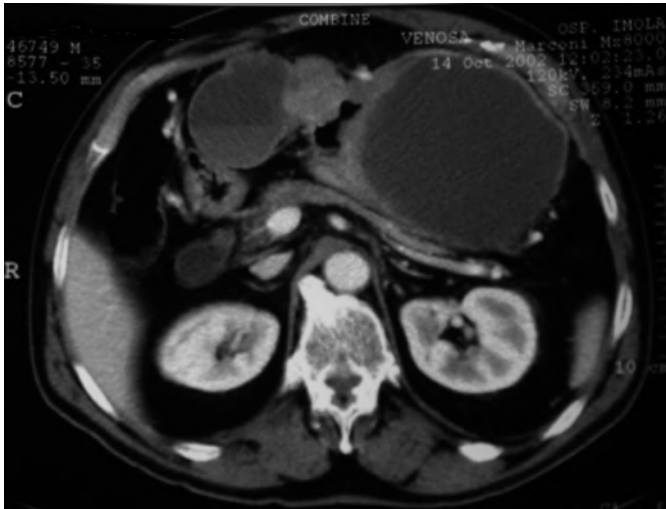


Fig. 1: Abdomen Computed Tomography. A larger fluid filled pseudocyst (>20cm) is adjacent the greater gastric curvature and another smaller (7 cm) similar lesion with a solid area is adjacent lesser curvature.

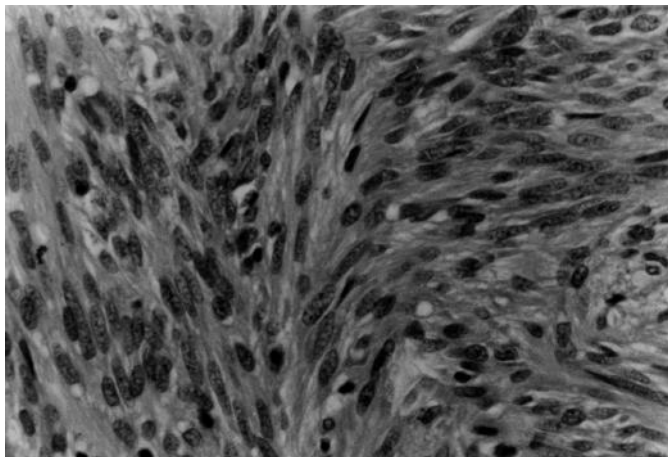


Fig. 2: Gastrointestinal stromal tumor composed of spindle cells with moderate nuclear pleomorphism. A mitotic figure is present (H-E 25X).

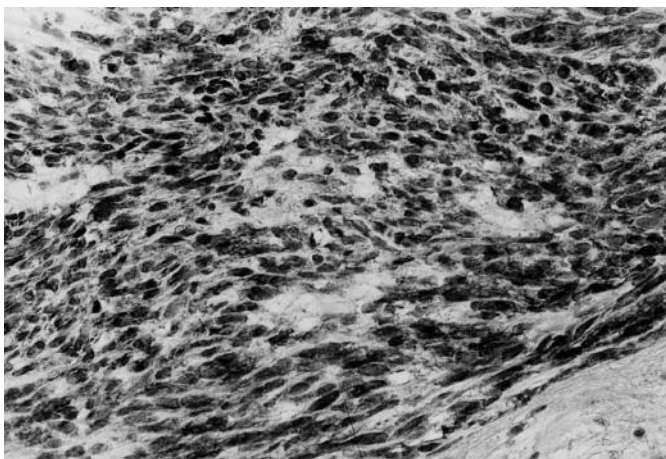


Fig. 3: CD117 staining showing diffuse, strong cytoplasmic positivity in the majority of tumor cells (25X).

At light microscopy GISTS appear as proliferation of spindle cell (70%), epithelioid (20%) or mixed type cells. Stomach is most frequent site (60-70%), followed by small bowel (25-35%), colon-rectum (5%) and esophagus (2-3%)⁴.

All GISTs should be considered potentially malignant tumors and even lesions with low proliferative activity can metastasize or give metastases after years⁵. Around 40-60% of recurrences occur within two years from primary resection^{5,6}. Liver is preferred site of metastases, rarely lung or bone, while recurrences involve peritoneal surface⁶⁻⁸.

De Matteo reports a recurrence rate of 40% and an overall 5 years survival of 54% in a group of 80 patients with non metastatic GISTs⁹. When recurrence occurs median survival is around 15-16 months^{8,9}.

Tumor size and mitotic count (MC) are the two parameters best correlated to prognosis, especially when considered together¹⁰.

Hyan et al. found no recurrence in a group of 69 patients after a median follow up of 25 months in lesions with size <5cm and MC <5/50HPFs. An aggressive behaviour assumed tumours with size >10cm and MC >5/50HPFs and median survival rate was 18 months. In border line lesions the absence of invasion and cytologic atypia were criteria capable to define neoplasias with better prognosis^{11,12}.

In a series of 156 duodenal GISTs Miettinen reported an 86% overall mortality in tumours with size >5cm and MC >5/50HPFs⁷. Kwon experience validates the high prognostic value of the association of tumour size and mitotic count¹³.

GIST treatment is based on complete cancer removal with gross surgical margins without lymphadenectomy. GISTs never give lymph nodes metastases.

In gastric GISTs with diameter <5cm treatment of choice is a wedge resection, limiting partial gastrectomy to larger distal lesions and total gastrectomy to fundic or iuxta cardia lesions^{14,15}.

The extension of surgical resection doesn't influence prognosis if margins are free. No studies show a significant correlation between extension of surgical resection and survival¹⁶. If tumour invades adjacent organs their removal is necessary although this represents a sfavorable prognostic factor.

Different reports demonstrated the scarce response of GISTs to both radiation and chemotherapy¹⁷. Imatinib Mesylate (STI-571) is a potent inhibitor of activated Kit protein and its efficacy in CML treatment is known^{1,2}. Some studies showed that STI-571 is also effective in the treatment of non resectable or metastatic GISTs. Demetri evaluated the activity of the drug in 120 patients with a minimum follow up of 9 months: 53% of patients had partial response (decrease in size $\geq 50\%$, absence of progression and absence of new lesions), 27.9% had stable disease, 13.6% showed progression and no patients had a complete response to the treatment¹⁷.

Verweij et al obtained slightly better results. A complete response was observed in 4% of patients, a partial response in 67%, a stable disease in 19% and a progression in 11%. Overall 73% of patients were free from progression at 1 year¹⁸. It's difficult to establish whether the better result of this study than previous is caused by a higher dose of drug (400mg twice daily versus 400 or 600mg daily). The response rate of sarcomas and other mesenchymal non GIST tumours is very low¹⁸.

There are no sufficient data to establish the value of Imatinib for neoadjuvant or adjuvant other than for palliative treatment.

Bumming reported the treatment of a patient with a huge 35cm ileal GIST and liver metastases considered unresectable. After 12 weeks of therapy with ST-571 tumour size had considerably decreased (18cm) and liver metastases had become cystic allowing surgical resection of the tumour¹⁹.

Conclusion

Most of mesenchymal gastric tumours are GISTs. Gastrointestinal bleeding is the most common presenting symptom. Tumours with size <5cm and MC <5/50HPFs can be considered with low malignant potential but recurrences or metastases are even possible. A strict follow up is necessary in lesions with more than 5 mitoses/50HPFs, size > 10cm or with invasion at surgery.

The surgeon's role in gastric GIST treatment is to achieve a complete tumour resection with free margins. A wedge resection is whenever possible the optimal treatment in small tumours (size <5cm).

Sometimes tumours with size <5cm are malignant, consequently a wide margin of resection should always be obtained avoiding excessive manipulation with intraabdominal dissemination.

In advanced tumours even with liver metastases surgical resection can be combined with Imatinib Mesylate palliative treatment obtaining in some patients a prolonged stable disease or a partial response.

Further studies are needed to evaluate the efficacy of the drug in neoadjuvant and adjuvant therapy.

Riassunto

Oggi con il termine GIST si indica un gruppo di neoplasie mesenchimali dell'intestino che mostrano positività immunoistochimica per la proteina kinasi KIT (CD 117). La terapia chirurgica rimane il cardine del trattamento di queste rare neoplasie. L'Imatinib-Mesilato (STI-571) è un potente inibitore della Kit protein-kinasi attivata il cui utilizzo si è dimostrato efficace nella terapia dei GIST non reseccabili o metastatici.

SCOPO: In questo lavoro abbiamo valutato l'incidenza dei

Gist tra le neoplasie mesenchimali gastriche e ne abbiamo analizzato le manifestazioni cliniche, i criteri prognostici di malignità e il tipo di trattamento chirurgico. Abbiamo inoltre valutato la risposta all'Imatinib Mesilato in un GIST metastatico.

MATERIALI E METODI: Abbiamo analizzato retrospettivamente dodici casi di neoplasie mesenchimali gastriche ricercando la positività immunoistochimica per il CD117 ed identificando 8 casi di Gist. Il follow up medio è stato di 37 mesi (range 7-120mesi). Descriviamo in dettaglio il caso clinico di un Gist metastatico trattato con Imatinib Mesilato per 15 mesi.

RISULTATI: Il 67% delle neoplasie mesenchimali gastriche sono risultate CD117+. La manifestazione clinica più frequente è stata l'emorragia digestiva. Il 50% dei GIST maligni presentava già una massa palpabile alla diagnosi. Tutte le neoplasie <5cm avevano una conta mitotica (MC) <5/50 high-power fields(HPFs) eccetto un caso di leiomiomasarcoma ad alto grado. Il 50% dei Gist sono risultati maligni. Il trattamento chirurgico è consistito nell'asportazione completa del tumore con margini liberi da neoplasia. Nessuna recidiva si è osservata nelle lesioni <5cm di diametro e con <5 mitosi/50HPFs. Buona risposta alla terapia con Imatinib Mesilato si è avuta in un Gist metastatico.

CONCLUSIONI: Il ruolo del chirurgo nel trattamento dei GIST gastrici è quello di ottenere l'asportazione completa del tumore con margini liberi da neoplasia. Nelle lesioni in stadio avanzato anche con metastasi epatiche è sempre opportuno tentare l'asportazione della massa in quanto l'utilizzo dell'Imatinib Mesilato a scopo palliativo permette in una buona percentuale di pazienti di ottenere una stabilizzazione anche prolungata della malattia o addirittura una parziale regressione.

Bibliografia

- 1) Fletcher C, Berman JJ, Corless C, Gorstein F, Lasota J, Longlry J: *Diagnosis of Gastrointestinal Stromal Tumors. A Consensus Approach*. Human Pathology, 2002; 33:459-65
- 2) Kitamura Y, Hirota S, Nishida T: *Gastrointestinal Stromal Tumors (GIST). A model for molecule based diagnosis and treatment of solid tumors*. Cancer Sci, 2003; 94:315-20.
- 3) Miettinen M, El-Rifai W, Sobin L, Lasota J: *Evaluation of malignancy and prognosis of Gastrointestinal Stromal Tumors. A Review*. Human Pathology, 2002; 33:478-83.
- 4) Miettinen M, Lasota J: *Gastrointestinal Stromal Tumors (GISTs). Definition, occurrence, pathologic differential diagnosis and molecular genetic*. Pol J Pathol, 2003; 54(1):3-24.
- 5) Tornoczky T, Kover E, Pajor L: *Frequent occurrence of low grade cases among metastatic gastrointestinal stromal tumours*. J Clin Pathol, 2003; 56(5):363-67.
- 6) Evans HL: *Smooth muscle tumors of the gastrointestinal tract. A study of 56 cases followed for a minimum of 10 years*. Cancer, 1985; 56:2242-50.

- 7) Miettinen M, Kopczynski J, Mkhoulouf HR, Sarlomo-Rikala M, Burke A, Sobin LH: *Gastrointestinal stromal tumors, intramural leiomyomas and leiomyosarcomas in the duodenum: A clinicopathologic, immunohistochemical, and molecular genetic study of 167 cases*. Am J Surg Pathol, 2003; 27(5):625-41.
- 8) Hen H, Pollock R, Romsdahl M: *Prognostic implications of patterns of failure for gastrointestinal leiomyosarcomas*. Cancer, 1992; 69(6):1334-341.
- 9) Dematteo RP, Heinrich MC, El-Rifai W, Demetri G: *Clinical management of gastrointestinal stromal tumors: Before and after STI-571*. Human Pathology, 2002; 33(5):466-77.
- 10) Lin SC, Huang MJ, Zeng CY, Wang TI, Liu ZL, Shiay RK: *Clinical manifestations and prognostic factors in patients with gastrointestinal stromal tumors*. World J Gastroenterol, 2003; 9(12):2809-812.
- 11) Yan H, Marchetti P, Acherman Y, Gething SA, Brun E, Sugarbaker PH: *Prognostic assessment of gastrointestinal stromal tumor*. Am J Clin Oncol, 2003; 26(3):221-28.
- 12) Wong NA, Young R, Malcomson RD, Natar AG, Jamieson, Save VE: *Prognostic indicators for gastrointestinal stromal tumors: A clinicopathological and immunohistochemical study of 108 resected cases of the stomach*. Histopathology, 2003; 43(2):118-26.
- 13) Kwon SJ, Members of the Korean Gastric Cancer Study Group: *Surgery and prognostic factors for gastric stromal tumor*. World J Surg, 2001; 25:290-95.
- 14) Knoop M, Friedrichs K, Dierschke J: *Surgical management of gastrointestinal stromal tumors of the stomach*. Langenbeck's Arch Surg, 2000; 385:194-98.
- 15) Catena F, Pasqualini E, Campione O: *Gastrointestinal stromal tumors: Experience of an emergency surgery department*. Digestive Surgery, 2000; 17:503-7.
- 16) Fujimoto Y, Nakanishi Y, Yoshimura K, Shimoda T: *Clinicopathologic study of primary malignant gastrointestinal stromal tumor of the stomach, with special reference to prognostic factors: Analysis of results in 140 surgically resected patients*. Gastric Cancer, 2003; 6(1):39-48.
- 17) Demetri GD, von Mehren M, Blanke CD, Van den Abbeele AD, Eisenberg B, Roberts PJ: *Efficacy and safety of Imatinib Mesylate in advanced gastrointestinal stromal tumors*. New Engl Journ Med, 2002; 347(7):472-80.
- 18) Verweij J, van Oosterom A, Blay J, Judson I, Rodenhuis S, van der Graaf W: *Imatinib mesylate (STI-571 Glivec-R, Gleevec-TM) is an active agent for gastrointestinal stromal tumours, but not yield responses in other soft-tissue sarcomas that are unselected for a molecular target: Results from an EORTC Soft Tissue and Bone Sarcoma Group phase II study*. Euro Journ Cancer, 2003; 39:2006-11.
- 19) Bummig P, Andersson J, Meis-Kindblom JM, Klingenshierna H, Engstrom K, Stierner U: *Neoadjuvant, adjuvant and palliative treatment of gastrointestinal stromal tumours (GIST) with imatinib: A centre-based study of 17 patients*. Br Journ Cancer, 2003; 89:460-64.

Commento

Commentary

Prof. FRANCESCO MINNI
Ordinario di Chirurgia Generale
Università di Bologna

La trasformazione in senso oncogenetico della proteina ad attività tirosin-chinasica KIT, fisiologicamente espressa dalle cellule interstiziali di Cajal (ICC) del plesso mioenterico, pare rappresentare l'evento centrale nell'insorgenza di un GIST. L'impiego di anticorpi (CD117) diretti verso questa proteina di membrana permette spesso di catalogare una neoplasia stromale nel gruppo dei GIST. Le conoscenze di biologia molecolare permettono di chiarire sempre meglio gli eventi a livello genico che alterano la codifica proteica ed iniziano ad identificarsi gruppi familiari con mutazione "germline" e conseguente malattia a "precoce" manifestazione. La chirurgia rappresenta ancora la migliore terapia possibile per questi pazienti, archiviando buoni risultati nelle forme a rischio "molto basso", "basso" e "intermedio" (Fletcher 2002) trattate radicalmente; la prognosi delle forme ad "alto" rischio (>10 cm di diametro max elo > 10 mitosi/50 HPF) rimane scadente in virtù dell'elevato tasso di recidiva e metastatizzazione e degli scarsi risultati del reintervento chirurgico e delle altre terapie adiuvanti convenzionali. Una nuova strada pare essere aperta dall'impiego di un farmaco in grado di interferire con l'attività della proteina mutata: l'imatinib mesilato (STI571, Gleevec; Novartis Pharma, Basel, Switzerland). I risultati dei trail multicentrici (CSTIB2222 e European Organization for Research and Treatment of Cancer Soft Tissue and Sarcoma Group) riportano risultati positivi nei pazienti con malattia non resecabile o metastatica dimostrando una stabilizzazione della crescita neoplastica quando non una diminuzione della massa tumorale. Il ruolo neoadiuvante di questo 2-phenylpyrimidina derivato è attualmente in corso di valutazione. È verosimile che nel prossimo futuro la chirurgia potrà avvalersi, anche in fase precoce, di un potente alleato.

The oncogenetic transformation of the tyrosine kinase protein KIT, that is usually strongly expressed by cells of Cajal, belonging to the myenteric plexus, seems to be the main event in GIST development. The use of antibodies (CD117) versus KIT protein normally allows us to classify a stromal tumor as GIST. The molecular biology knowledge let us explain the events that genetically forge the KIT protein. Families with germline mutation and so with early tumor appearance may be identified. In these patients radical resection is still the sole therapy, with good results in "very low", "low" and "intermediate" risk tumor groups (Fletcher 2002). The prognosis is poor in patients with "high" risk tumor (>10cm in diameter and/or with >10 mitoses/50 HPF), because of the high rate of recurrence and metastases and because the poor results in case of reintervention or with adjuvant therapy. The Imatinib Mesylate (STI571 or Gleevec; Novartis Pharma, Basel, CH), a drug that works by turning off the KIT abnormal enzyme, seems to be the new frontier in the management of GIST. In fact Multicenter Trials (CSTIB2222 and the European Organization for Research and Treatment of Cancer Soft Tissue and Sarcoma Group) have shown positive results in patients with unresectable or metastatic tumor, with stable disease or with cancer remission, in selected cases.

The neoadjuvant role of this 2-phenylpyrimidinederivate is under evaluation, but probably it will avail surgery, in the next future. "Tetrahedron logic" was ideated by prof. Pagano Michele (4, 5) for civil engineering analysis, teaching and profession. I utilized this logic to find the principal dynamic variables of C.U.T. I wanted to obtain a Data Base easy and useful for surgeons at work in urgent ward (like I do), who "seldom have this subject in their background".

C.U.T. is based on the four variables of the "dynamic decisional tetrahedron" (Problem, Substrate, State, Decision). It was well accepted and easily utilized.

Human being (surgeons and patients are human beings) often looks at himself in a tetrahedron fashion (Body, Emotions, Mind, Spirit). He often exposes his medical advances following a tetrahedron schema (Introduction, Material and Methods, Results, Discussion). He perhaps finds easier and more acceptable a "complex subject" when it has been schematized by the tetrahedron logic.

