

The plastic surgeon and graves disease



Ann. Ital. Chir., LXXV, 3, 2004

A. Chiarelli

Unità Operativa Complessa
Chirurgia Plastica pediatrica
Azienda Ospedaliera - Università di Padova - Italia

Introduction

In the past, the surgical treatment of thyroid-associated ophthalmopathy posed a difficult problem and the outcome was almost always mediocre, often with far from negligible complications. Surgery was reserved exclusively for particularly severe cases, whose condition justified the risk. Such poor results have prompted numerous surgeons to attempt to optimize the techniques available to improve outcome and reduce postoperative sequelae.

Initially, the only solution adopted was surgical orbital expansion (1-4) involving one or more walls of the orbital cavity. The specialist capabilities required often meant calling in a brain surgeon, the approaches were disruptive and the operation somewhat aggressive until Olivari, a German plastic surgeon, ingeniously proposed reducing the orbit's content instead of increasing its capacity, as the conventional technique aimed to do (5). Since removing important tissue such as the eyeball or extrinsic musculature was out of the question, the only removable tissue (providing it was abundant and accessible) was the adipose deposits. This idea opened up new horizons in surgery for thyroid-associated ophthalmopathy and although the initial enthusiasm has faded to some degree, it nonetheless remains an innovative method that proves a useful tool in the hands of the expert surgeon in suitable cases, sometimes in association with the conventional methods.

Riassunto

IL CHIRURGO PLASTICO E L'OCULOPATIA BASE-DOWIANA

L'oftalmopatia tiroidea è una malattia causata da processi autoimmuni che interessa anche la ghiandola tiroidea, gli arti inferiori e a livello orbitario coinvolge in particolare il tessuto muscolare e adiposo. Quando la terapia medica non consente risultati apprezzabili la chirurgia mira a decomprimere la cavità orbitaria.

Negli ultimi anni questa tecnica ha subito notevoli miglioramenti grazie alla lipectomia trans-palpebrale. Essa ha consentito di ottenere buoni risultati specie quando l'ipertrofia dei muscoli estrinseci è scarsamente rappresentata. Nei casi in cui invece questa è importante, la lipectomia può integrare la fenestrazione ossea della cavità orbitaria riducendone l'esecuzione a meno pareti.

Lo studio di 52 pazienti sottoposti a decompressione orbitaria mediante lipectomia e/o fenestrazione ossea per un totale di 96 orbite ha consentito di valutare le possibilità e i limiti delle singole tecniche nel tentativo anche di individuare un approccio razionale di questa patologia.

È stato evidenziato che nei casi di proptosi di bassa-media gravità (proptosi inferiore a 24 mm) e con scarsa ipertrofia dei muscoli estrinseci, la lipectomia può essere sufficiente di per sé ad ottenere buoni risultati. Nei casi invece di media-alta gravità (proptosi superiore a 24 mm) la fenestrazione ossea può essere necessaria integrata o meno dalla lipectomia.

Tecniche aggiuntive sui muscoli elevatori e retrattori delle palpebre sono state quasi sempre necessarie.

Parole chiave: Oftalmopatia tiroidea, decompressione orbitaria, lipectomia, fenestrazione ossea, esoftalmo.

Abstract

Thyroid-associated ophthalmopathy is a disease caused by autoimmune processes that also affects the thyroid gland and the lower limbs; at orbital level, it involves the muscle and adipose tissue. When medical treatment fails to achieve appreciable results, surgery aims to decompress the orbital cavity.

In recent years, the treatment has been considerably improved by the introduction of transpalpebral lipectomy, which has produced valid results especially in cases when extrin-

sic muscle hypertrophy is limited; if it is severe, however, lipectomy can be combined with expansion of the orbital cavity, thus enabling the latter to be restricted to one or two walls instead of three.

Studying 52 patients who underwent orbital decompression involving lipectomy and/or orbital expansion, affecting a total of 96 orbits, enabled an assessment of the pros and cons of the single techniques in an attempt to identify a rational approach to this pathology.

It emerged that lipectomy alone may suffice and obtain valid results in cases of mild-to-moderate proptosis (up to 24 mm) with limited extrinsic muscle hypertrophy, whereas orbital expansion – with or without lipectomy – is likely to be necessary in moderate-to-severe cases (proptosis greater than 24 mm).

Additional procedures to correct the elevator and retractor muscles of the eyelids were almost always necessary.

Key words: Thyroid-associated ophthalmopathy, orbital decompression, lipectomy, orbital expansion, exophthalmos.

Materials and methods

Access to the surgical field is through the skin incisions usually adopted for aesthetic blepharoplasty surgery, slightly modified. After removing part of the orbital muscle, an incision is made in the orbital septum and the medial and lateral adipose spaces are identified superiorly and inferiorly. Using suitable surgical instrumentation, the extra – and intra-conical adipose tissue (which can amount to up to 10 cc) is removed. Particular attention must be paid to hemostasis and to avoid damaging the eyeball, extrinsic musculature, nerve and lachrymal gland. This method is relatively straightforward once it has been learnt. Good results depend on a careful patient selection and the surgeon's expertise in knowing how to isolate and remove the more superficial and the deeper fatty tissue. The outcome is not always assured. Where lipectomy is not indicated, it is advisable to resort to orbital expansion.

This latter method has recently become less aggressive and traumatic, however, though the experts have yet to reach a consensus as to which orbital walls should be demolished and to what degree. Changes have been made to the surgical access and the once-preferred coronal access can be substituted by the external alternative, in which case the same incisions are made as for lipectomy, which almost never leaves any evidence of scars.

The transnasal route (6), with or without endoscopy (7), is used by some surgeons for expansion of the medial wall. In the author's opinion, to ensure valid results and reduce any complications to a minimum, it is important to be able to assess the extent of the expansion and ensure that it is as symmetrical as possible (especially if the inferior wall is involved).

The procedure is sometimes combined with a further

expansion of the orbital cavity by milling the edge and the supero-posterior wall.

Lipectomy and orbital expansion can be performed in the same operation or in two separate procedures. The author prefers to combine the two techniques wherever possible to further improve the outcome and reduce the complications (8, 9).

From July 1996 to December 2002, 52 patients aged between 30 and 62 years, the majority of them female (61%), underwent surgery on a total of 96 orbits with a follow-up of up to 48 months.

Lipectomy alone was performed in 60% of cases, orbital expansion in 15% and the two procedures in combination in 25%.

The amount of adipose tissue removed ranged from 2.5 to 9.0 cc (mean 5.3 cc).

In cases of expansion alone, the operation included fracturing the medial, lateral and inferior walls. The combined procedures generally involved only the medial and lateral walls, though a three-wall procedure was sometimes necessary.

Results and complications

Almost all patients achieved an improvement in their exophthalmos; in particular, correction of proptosis ranged from 0.0 mm to 13 mm (mean 5.5 mm). When the techniques employed were compared, the mean correction was greater after orbital expansion and the combined techniques (7.0 and 6.0 mm respectively), while it was 3.7 mm after lipectomy alone.

As for the complications, pre-operative diplopia disappeared in 45% of cases, improved in 8%, remained unchanged in 42% and developed ex novo in 5%. Photophobia remained stationary in 36%, regressed in 61% and progressed in 3%. Visual acuity regressed in 3% and progressed in 13%, remaining stationary in the other 84%. The most significant parameters relating to the results and complications are summarized in tables 1 and 2.

Upper and lower eyelid retraction was corrected with serial measures, sometimes subsequent to decompression, using various techniques (resection, grafting, canthopexy).

Case studies

Fig. 1: This patient (C.O. 50 yr.) underwent lipectomy, removing 5.0 cc of adipose tissue from each orbit. Preoperative proptosis; RE 29 mm, LE 31 mm; postoperative proptosis with a follow-up of 11 months: RE 23 mm, LE 24 mm.

Fig. 2: This patient (B.R. 50 yr.) underwent transcoronal orbital expansion of the medial, lateral and inferior walls and lipectomy to remove 7.5 cc of adipose tissue from each orbit.

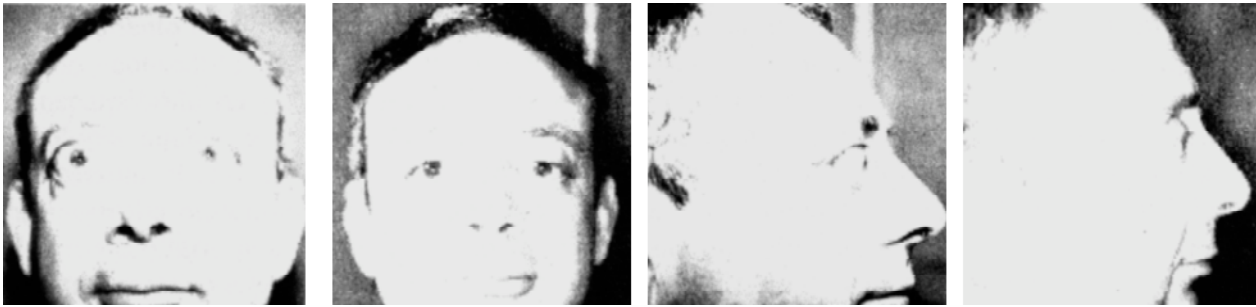

Fig. 1.

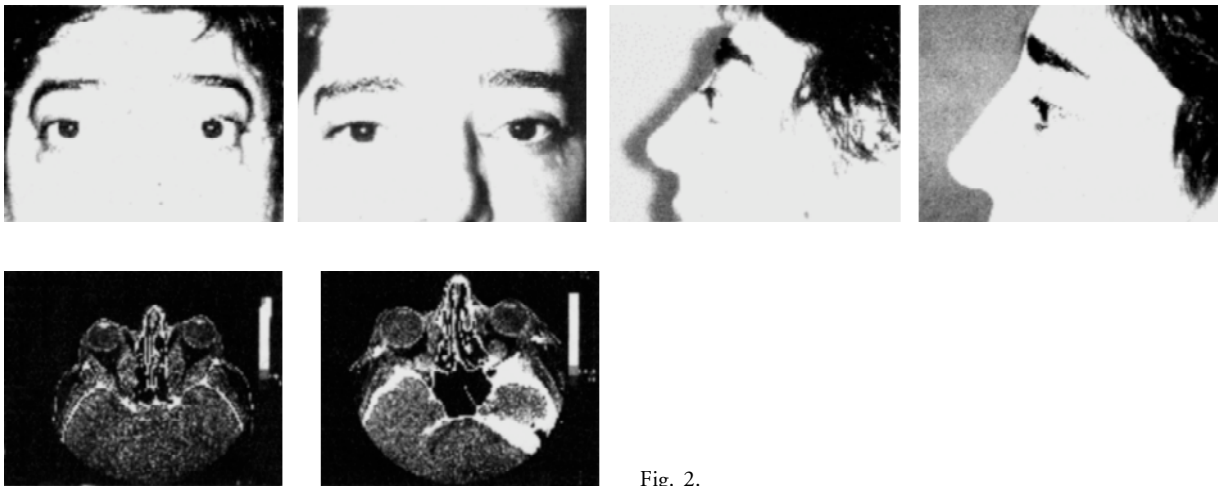


Fig. 2.

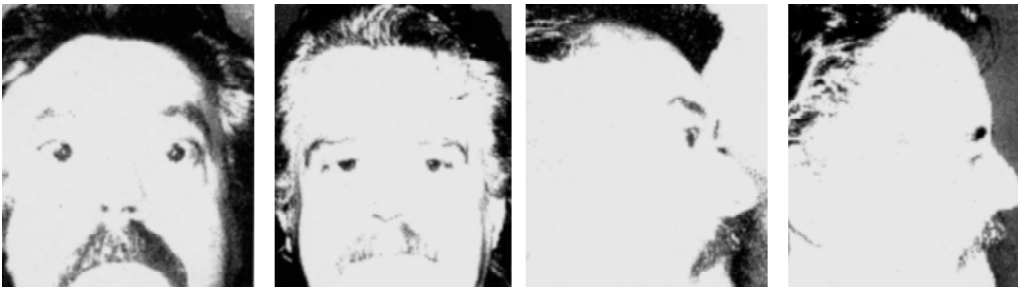

Fig. 3.

Preoperative proptosis: RE-LE >35 mm; postoperative proptosis with a follow-up of 18 months: RE-LE 25 mm.
 Fig. 3: This patient (Q.P. 46 yr.) underwent orbital expansion via external access of the medial, lateral and inferior walls and lipectomy to remove 7.0 cc of fatty tissue from the RE and 6.0 cc from the LE.
 Preoperative proptosis: RE 26 mm, LE 25 mm; postoperative proptosis with a follow-up of 43 months: RE 22 mm, LE 20 mm.

Discussion

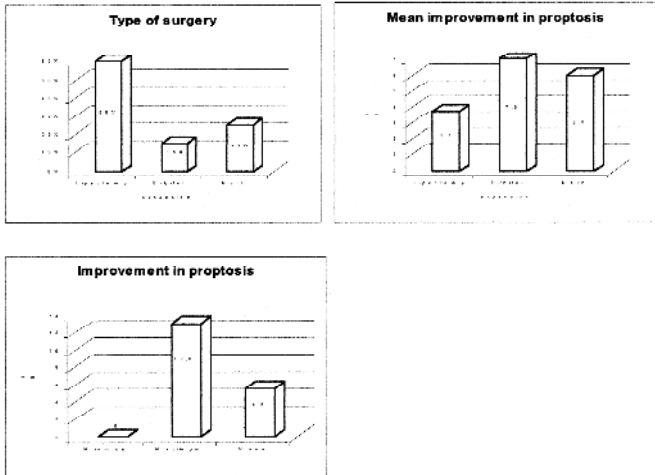
The surgical treatment of thyroid-associated ophthalmopathy has undergone various adaptations in recent years, enabling better results to be achieved with fewer complications.

Transpalpebral lipectomy has contributed considerably towards overcoming the problems involved in treating thyroid-associated ophthalmopathy, though it is not sufficient alone in all patients. It is indicated mainly in cases of proptosis <24-25 mm, with adequate fatty tissue deposits and limited muscle hypertrophy, no evidence of inflammation and an intact orbital nerve. Nonetheless, even when these indications are satisfied, the results can sometimes be unexpected and it is not easy to ascertain the causes of these failures.

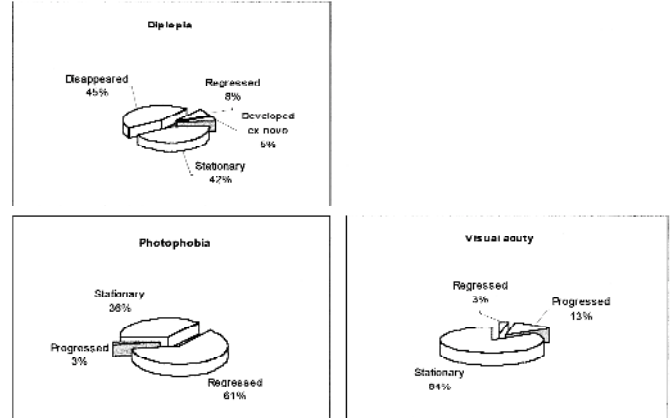
Lipectomy is also indicated as a complementary measure in patients with a proptosis of 24 to 28 mm. Used in combination with orbital expansion, it enables the extent of the fractures to be contained, generally restricting them to the lateral and medial walls.

When the proptosis exceeds 30 mm, however, valid

Tab. I – HISTOGRAMS SHOW THE TYPES OF SURGERY AND THE IMPROVEMENT IN PROPTOSIS AS PERCENTAGES



Tab. II – PERCENTAGE TRENDS OF THE MAIN COMPLICATIONS



results can only be achieved by performing a three-wall expansion (of the medial, lateral and inferior orbital walls) with or without lipectomy (because it may sometimes be advisable to leave a residual cushion of adipose tissue in situ).

Following these criteria, the improvements achieved by lipectomy – expressed as the reduction in proptosis in mm – are naturally less remarkable than with expansion, given that the technique is more suitable for the less severe cases, producing valid results in patients with mild or moderate proptosis. It is worth noting the trend of any diplopia, which disappeared after lipectomy in many patients who had the symptom preoperatively and it was generally transient and mild in those who developed the symptom after surgery. Photophobia almost always improved, persisting only in a few cases.

Many factors influence the outcome of surgery, e. g. any inflammatory conditions, the severity and duration of the Graves' disease, the patients' smoking habits. Opinions differ as concerns any influence of prior radiotherapy (10).

In the author's opinion, every case of thyroid-associated ophthalmopathy is a new story and it is only on the strength of experience that the surgeon can identify the correction method best suited to a given case and, in the light of the numerous factors involved, formulate a reliable prognosis.

In addition to the problem posed by the proptosis, there is also the matter of upper and lower eyelid retraction to consider. Elevator muscle retractions have been easier to deal with, though it often proved necessary to perform one or more adjustment operations. Mediocre results are more common with the lower eyelids, especially in cases where the improvement in proptosis has been relatively small.

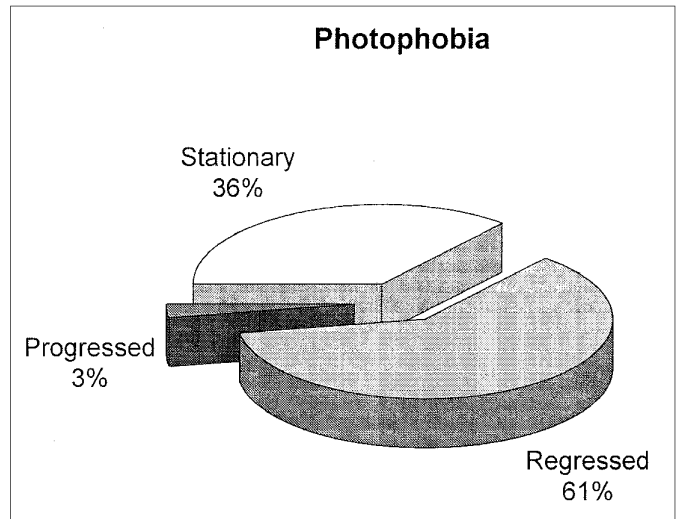


Grafico 1.

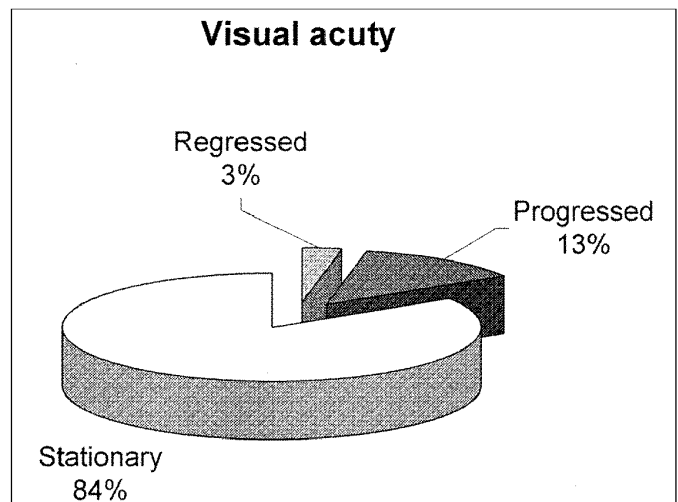


Grafico 2.

Conclusions

Considerable advances have been made in the treatment of thyroid-associated ophthalmopathy and researchers are moving towards a complete and definitive solution to the problems posed by this pathology, which is responsible for considerable morphological and functional limitations in the patients affected. A single technique clearly cannot offer the best solution and the choice of the most suitable treatment depends largely on whether the indications for surgery are functional or morphological: in the former case, even the more aggressive and hazardous operations may be inevitable; in the latter, needless to say, patients must be adequately informed about the available methods, the possible outcome and the risk of complications.

References

- 1) Walsh T.E., Agura T.M.: *Transantral orbital decompression for malignant exophthalmos*. Laryngoscope, 1957, 67:544.
- 2) Tessier P.: *Expansion chirurgicale de l'orbite*. Ann Chir Plast, 1969, 14:207.
- 3) Wolfe S.A.: *Modified three-wall orbital expansion to correct persistent exophthalmos or exorbitism*. Plast Reconstr Surg, 1979, 64:448.
- 4) Krastinova D., Rostallec A.: *Orbitopathie Basedowienne*. Ann Chir Plast Esthet, 1995, 40:31.
- 5) Olivari N.: *Transpalpebral decompression of endocrine ophthalmopathy (Graves' disease) by removal of intraorbital fat: Experience with 147 operations over 5 years*. Plast Reconstr Surg, 1991, 87:627.
- 6) Sellari-Franceschini S., Berrettini S., Forli F., Batolena L., Nolarocco C., Tonda M.L., Nardi M., Lepri A., Pinchera A.: *Orbital decompression in Grave's disease: comparison of techniques*. Acta Otorhinolaryngol Ital, 1999, 19:6.
- 7) Wright E.D., Davidson J., Codere F., Desrosiers D.: *Endoscopic orbital decompression with preservation of an inferomedial bony strut: minimization of postoperative diplopia*. J Otolaryngol, 1999, 28:5.
- 8) Morax S., Bok C., Chahbi M., Hurbli T.: *Decompression orbitaire ou cours de l'exophtalmie disthyroïdienne. A propos de 69 cas*. Chir Plast Esthet, 1997, 42:3.
- 9) Gola R.: *Exophtalmie Basedowienne: lipectomie ou expansion orbitaire*. Ann Chir Plast, Estet, 1995, 40:31.
- 10) Weetman A.P., Wiersinga W.M.: *Current management of thyroid-associated ophthalmopathy in Europe. Result of an international survey*. Clinical Endocrinology, 1988, 49.

Autore corrispondente:

Dott. Angelo CHIARELLI
U.O.C. Chirurgia Plastica Pediatrica
Azienda Ospedaliera - Università
Via Giustiniani, 2
35128 PADOVA - ITALIA
Tel.: 0039-049-821.2712/1913/8080/2487
Fax: 0039-049-821.8793
E-mail: chir.plastica.ped.labf@sanita.padova.it

