

Partial acute thrombosis of internal carotid artery: a case report



Ann. Ital. Chir., LXXVI, 1, 2005

R. Angelini, F. Rutolo, V. D'Amario,
F. Spigonardo

U.O. di Chirurgia Vascolare,
Ospedale Clinicizzato SS. Annunziata, Chieti

Introduction

The indications to the carotid TEA in case of acute occlusion of the internal carotid artery still do not have one sure coding. True it is that generally the surgical procedure is contraindicated when serious neurological deficits are present; in fact the lack of a proven benefit to the detriment of the high risk perioperative of another ictus and/or haemorrhage is rations them of the choice. Some Authors consider the opportunity of the surgical procedure if this happens within an hour from the acute event; the tolerance of the hypoxemia to cerebral level is function of the contribution of blood, of the severity and of the duration of ischaemia (1). Others report of selected cases of acute carotid occlusion treated by TEA considering like important prognostic factors the absence of embolism of the homolateral medium cerebral artery or to the presence of a good collateral flow in case of embolism of this (1, 2, 3, 4, 5). Ulterior possibility with replies in literature of clinical cases acute occlusion of internal carotid artery and embolism of the homolateral medium cerebral artery is the combination of the directed carotid surgery associated to thrombolysis (6).

Case report

C. A. age 62 male with outcomes of pulmonary K dealt

Riassunto

TROMBOSI ACUTA PARZIALE DELL'ARTERIA CAROTIDE INTERNA. A PROPOSITO DI UN CASO

L'efficacia della TEA carotidea eseguita d'urgenza in pazienti con gravi sintomi neurologici non stabilizzati rimane controversa. In letteratura sono riportati vari casi con trombosi acuta trattati in emergenza e con risultati variabili da casistica a casistica che alimentano controversie in proposito. Riferiamo su un caso di trombosi carotidea acuta con sintomatologia neurologica aspecifica diagnosticato con ecocolordoppler (ECD) e completato dal punto di vista diagnostico con TC dell'encefalo. Il trattamento chirurgico d'urgenza ha avuto esito positivo. Sono descritte le peculiarità del caso non correlate alla sintomatologia classica. Parole chiave: Arteria carotidea, trombosi acuta, efficacia della TEA.

Abstract

Objective: The effectiveness of the urgent carotid TEA in patients with not stabilizes serious neurological symptoms, remains controversial.

Material: The authors report on a case of a partial acute carotid thrombosis. The patient had outcomes of pulmonary tumor dealt with surgical removal of the medium right lobe. At admission, the neurological examination evidenced non specific neurological deficits to both the advanced limbs above all. The blood test evidenced 628000 platelets. The color Doppler showed in the internal carotid artery of right the presence of floating thrombus, during very small fibrocalcified plate, likely ulcerated.

Results: The patient was submitted to surgical urgent procedure without ulterior diagnostic deepening. Such attitude was justified from the total regression of the symptomatology and from the absence of alterations of the BEE.

Discussion: The urgent surgical treatment has had good outcome. In literature there are similar cases but not place upon ones because of "aetiology": to the inner presence of floating thrombus in carotid not completely occluding in all and the three cases, causes do not correspond from alters platelet parameters, but thrombus was of cardiogenic origin in one case, it was caused by hormonal therapy for sterility in the second, there was thrombosis of carotid aneurism in third.

Conclusion: *We remark the importance of ecocolor Doppler for urgent diagnosis of acute thrombosis, and timeliness of surgical treatment in the "acute" patient with attenuation or regression of the debut symptomatology.*

Key words: Carotid artery, acute thrombosis, urgent TEA.

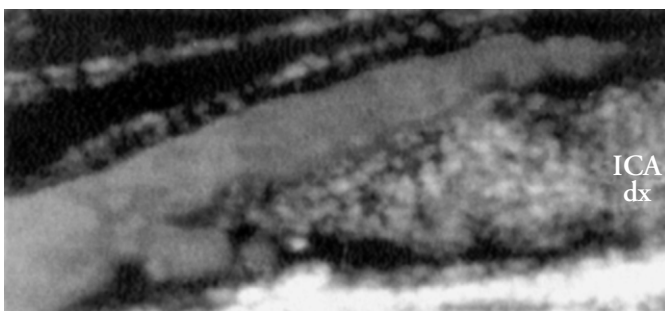
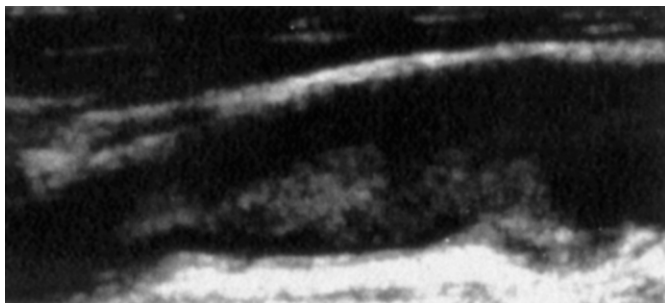
with surgical removal of the medium lobe of right 12 months before the shelter, in chemotherapy treatment. It reaches our observation transferred of urgency from the Neurological Division of a hospital bordering where it had been recovered during the previous night with symptomatology characterized from sensitive deficit to both the advanced limbs of the duration of approximately 1 hour. The neurological examination evidenced deficit of the look of left laterality associated to postural deficit of the left advanced limb in the antigravity tests (tendency to the superelevate of the same limb); deficit of the extension of hallux skilful (the outcome); Babinski on the left. The neurological deficits reverted about 12 hours. The executed encephalic TC of urgency evidenced focus in seat capsule-lenticular and in the radiate crown of right for past ischemica lesion on vascular base. The completed cardiological visit with ECG and trans-thoracic echocardiogram had excluded pathologies of cardiac origin. The congenital factors of the coagulation turned out in the norm.

The colordoppler of the epiaortic vessels showed in the internal carotid artery of right the presence of formation ecogena of the length of approximately 3.5 cm attached to the wall only for some millimetres in correspondence of the origin of the vase from the carotid bulb, during very small fibrocalcified plate likely ulcerated. For the rest

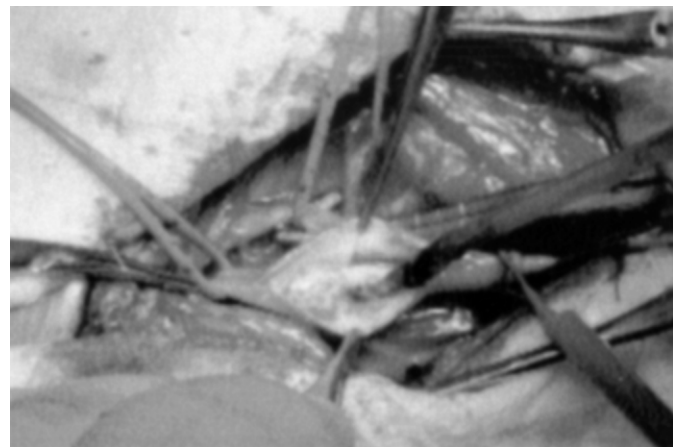
of its such length thrombotic formation appeared floating in the vessel (pic. 1 and 2). The blood test evidenced platelets increase with absolute value of the 628000 with normality of all other parameters. To 24 hours urgently from diagnosis ECD the patient was submitted to surgical procedure without ulterior diagnostic deepening (Rx-angiography and/or angio-RMN epiaortic and encephalic vessel). Such attitude was justified from the total regression of the symptomatology and from the absence of alterations of the BEE evidenced from the encephalic TC; not to neglect the possibility of partial separation or total of the intracarotid thrombus to the passage of contrast of in eventual angiographic examination.

The isolation of the distal internal carotid artery has been the first surgical manoeuvre continuation from the clamping of the internal carotid artery and from the isolation of the rest of vessel and of the neighbouring structures to avoid eventual embolizations.

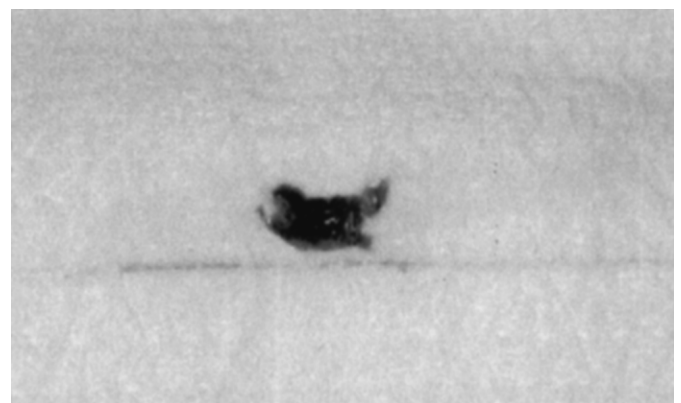
The morphology of the removed thrombus corresponded faithfully to the image shown from the ECD (pic. 3 and 4). Associated atheromatous plate was not found and consequently it was not proceeded to TEA but to



Pic. 1 and 2: Ecography of the floating partially occluding thrombus in internal carotid artery.



Pic. 3: Surgery: removal of the thrombus in carotid artery.



Pic. 4: Particular of the removed thrombus.

repeated washings of the segment subordinate to successive arteriotomy and directed suture.

The post-operative passed one has been regular and to three months the control of ECD is absolute normality like it counts platelet (from post-operative on council of the colleagues haematologist the patient has carried out associated specific therapy to platelet monitoring).

Discussion

The specific characteristics of the case over illustrated was beyond from the casuistries brought back in the introduction even if the clinical picture of the same one could mirror again the prodromic stage of one acute carotid thrombosis with successes to you important neurological deficits. In literature they are clinical signals cases to you similar to that from we reported (7, 8, 9) but not place upon ones. To the inner presence of floating thrombus in carotid not completely occluding in all and the three cases "aetiology" does not correspond from alters platelet parameters, but thrombus to you of cardiogenic origin with healthy carotid wall (7), thrombosis of carotid aneurism (8), from collateral effect following to hormonal therapy for sterility (9).

The ecocolor Doppler executed in urgency it has rendered reason of the successes to you diagnostic examinations and that to our warning is an important element in the economy of the management of such patients. This examination also second other Authors could not only assume the important in the diagnosis but also in monitoring intra and post-operative effectiveness in the study and prevention of embolic events (10, 11).

Conclusions

Also admitting our fortuitous timeliness care the factor time, our conclusions concern on the possibility to consider the examination color Doppler like diagnostic garrison of urgency where clinical the supports the suspicion of one pseudo and/or acute occlusion of the carotid supported from the absence of serious acute symptomatology

(side pathology, etc.) associate to attenuation or regression of the debut symptomatology. The demonstration thrombosis echography sub-total that of for himself evidences a highest probability of partial separation or total of the thrombus induces to our warning to the surgical treatment of deobstruent urgency.

Bibliografia

- 1) Meyer F.B., Sundt T.M., Piegras D.A., Sandok B.A., Forbes G.: *Emergency carotid endarterectomy for patients with acute carotid occlusion and profound neurological deficits*. Ann Surg, 1986; 203:1 88-88.
- 2) Hunt D.G., Wheeler C.G., Bukhari H.I., Hempel G.K.: *Surgical management of total carotid occlusion*. Am J Surg, 1980; 139: 700-703.
- 3) Najafi H., Javid H., Dye W.S.: *Emergency carotid thromboendarterectomy*. Arch Surg, 1971; 103: 610-614.
- 4) Donaldson M.L., Drezen A.D.: *Surgery for acute carotid occlusion*. Amer Surg, 1983; 118: 1266-1268.
- 5) Mc Cormick P.W., Spetzler R.F., Bailes J.E., Zabramski J.M., Frey J.F.: *Thromboendarterectomy of the symptomatic occluded internal carotid artery*. J Neurosurg, 1992; 76: 752-758.
- 6) Eckstein H.H., Hupp T., Allenberg J.R.: *Carotid endoarterectomy and local intraarterial thrombolysis: Simultaneous procedure in acute occlusion of internal carotid artery and middle cerebral artery embolism*. J Vasc Surg, 1995; 22:2 196-198.
- 7) Eudo M., De Bray J.M.: *Thrombus flottant dans une carotide*. J Radiol, 2000; 81: 1713-1714.
- 8) Spiegel M., Kopp H., Trese N.: *Ausgedehntes Aneurysma der Arteria carotis interna mit frei flottierendem Kugelthrombus*. Vasa (Switzerland), 1994; 23(4) p367-9.
- 9) Murrle G.A., Wetzel V., Burck C.H., Hasselbach G., Voss EU: *Flottierender thrombus der Arteria carotis interna als seltene Komplikation bei einem ovariellen hyperstimulationssyndrom nach in-vitro-fertilisation/embryotransfer*. Chirurg, 1998; 69, 1105-1108.
- 10) Russel D., Madden K.P., Clark W.N., Sandset P.M., Zivin J.A.: *Detection of arterial emboli using Doppler ultrasound in rabbit*. Stroke; 1991; 22: 2 253-258.
- 11) Paty P.S.K., Adeniyi J.A., Mehta M.: *Surgical treatment of internal carotid artery occlusion*. J Vasc Surg, 2003; 37: 785-788.

Autore corrispondente:

Dott. Romeo ANGELINI
Via Fonte Romana, 48/5
65124 PESCARA

