

# The double opposing “Y” technique for umbilical reconstruction after omphalectomy



Ann. Ital. Chir., 2011; 82: 505-510

Luca A. Dessy\*, Nefer Fallico\*, Emilio Trignano\*, Mauro Tarallo\*, Marco Mazzocchi\*\*

\*Department of Plastic and Reconstructive Surgery (Head: N. Scuderi), “La Sapienza” University of Rome, Italy

\*\*Department of Plastic and Reconstructive Surgery (Head: C. Alfano), University of Perugia, Perugia, Italy

## The double opposing “Y” technique for umbilical reconstruction after omphalectomy

**BACKGROUND:** *Abdominal surgical procedures, such as ventral hernia repair, may require the removal of the umbilicus, which gives an unnatural appearance to the abdomen. This situation can be corrected by umbilical reconstruction during the same operative time or at a later stage. In previous studies, we reported a versatile technique for umbilicoplasty based on a double opposing “Y” incision on the abdominal flap to create a new umbilicus. We now report the use of this technique for umbilical reconstruction in patients who underwent previous or concurrent omphalectomy.*

**METHODS:** *A prospective open-label study was performed on 10 patients undergoing the double opposed “Y” umbilicoplasty after omphalectomy. Postoperative patients’ satisfaction and results were evaluated during the follow-up of minimum 1 year. A modified 5 ml syringe was used to assess depth and volume of umbilical stalk. Depth value variations from one month to one year after surgery were statistically compared using the Wilcoxon test.*

**RESULTS:** *Complete healing of the new umbilicus was achieved in 14-21 days in nine cases. In one case, partial dehiscence of the wound occurred and complete healing was achieved in 4 weeks. Follow-up time ranged from 1 to 4 years. In all patients, a three-dimensional umbilicus with satisfactory depression was created. During follow-up, no significant changes in shape, dimension and appearance were observed. All patients were pleased with the results. No cicatricial umbilical stenosis occurred.*

**CONCLUSIONS:** *The double opposing “Y” technique creates a new natural umbilical scar; this technique can be easily performed for umbilical reconstruction after omphalectomy.*

**KEY WORDS:** Neoumbilicoplasty, Omphalectomy, Umbilicus reconstruction.

## Introduction

The abdomen plays a leading role in the aesthetic image of the upright human body and the umbilicus is an important structure from both an aesthetic and symbolic point of view. The umbilicus defines the median

abdominal sulcus and contributes to the curved shape of the inferior abdomen. Its absence leads to an unnatural abdominal appearance and may draw undue attention to the central abdomen. A patient may have its umbilicus removed during abdominal surgical procedures, such as the repair of ventral incisional hernias.

Many surgical procedures have been described for the reconstruction of the umbilicus<sup>1-24</sup>. Most of these techniques propose a circular incision of the umbilical cone that inevitably leads to the retraction and stenosis of the neo-umbilical depressed scar. In a preliminary report, we introduced the double opposing “Y” technique for umbilicus reconstruction in abdominoplasty; it has proved to give good aesthetic results and has demonstrated less scarring in the umbilical region<sup>25</sup>. In a lat-

Pervenuto in Redazione Aprile 2011. Accettato per la pubblicazione Luglio 2011.

Correspondence to: Dr. Luca Andrea Dessy, Via Irpinia 8, 09032 Assemini (CA), Italy (E-mail: lucadessy@hotmail.com)

er study, we have evidenced the long-term and stable results obtained with the double opposing "Y" umbilicoplasty<sup>26</sup>.

The purpose of this article is to describe the use of this technique for the reconstruction of the umbilicus in patients who underwent previous or concurrent omphalectomy.

## Material and methods

From February 2006 to February 2010, a prospective open-label study was performed. Ten patients underwent umbilical reconstruction after omphalectomy in the Department of Plastic Surgery of "Sapienza" University of Rome. The reconstruction of the umbilicus was performed using the authors' technique. Patients' age ranged between 25 and 65 years (median 45 years), 8 were females and 2 males. The body mass index (BMI) at the time of abdominoplasty ranged from 26 to 47 kg/m<sup>2</sup> (mean 33 kg/m<sup>2</sup>). Exclusion criteria were chronic skin diseases (psoriasis, sclerodermitis, etc.) and age over 65 years.

Surgical indication was in 5 cases the absence of the umbilicus as the outcome of previous abdominal sur-

geries and in 5 cases the concurrent removal of the umbilicus during the repair of a ventral hernia requiring omphalectomy.

Each patient included in these series was photographed in a standard manner before treatment and during follow-up visits. Minimum follow-up was 1 year. Clinical results were subjectively evaluated using a 4-point Likert scale (poor, fair, good, very good) by patients and by a panel of three external physicians (who were not involved in the procedure and in the clinical follow-up), who analysed pre- and post-treatment photos. Furthermore, results were objectively assessed using a 5 ml syringe as reported in previous studies<sup>31,32</sup>; in particular, the possibility to introduce the syringe inside the umbilicus permitted to exclude the occurrence of cicatricial stenosis; also, millilitres (ml) values were recorded during follow-up visits to assess depth and volume of umbilical stalk. The observed values between 1 month and 1 year after surgery were compared using the Wilcoxon matched pairs signed rank sum test and statistical significance was assigned at value of  $p < 0.05$ .

*Surgical technique:* After the elevation of the adipocutaneous superior abdominal flap, and after the repair of eventual ventral incisional hernias requiring omphalectomy (if umbilical reconstruction is performed at the same

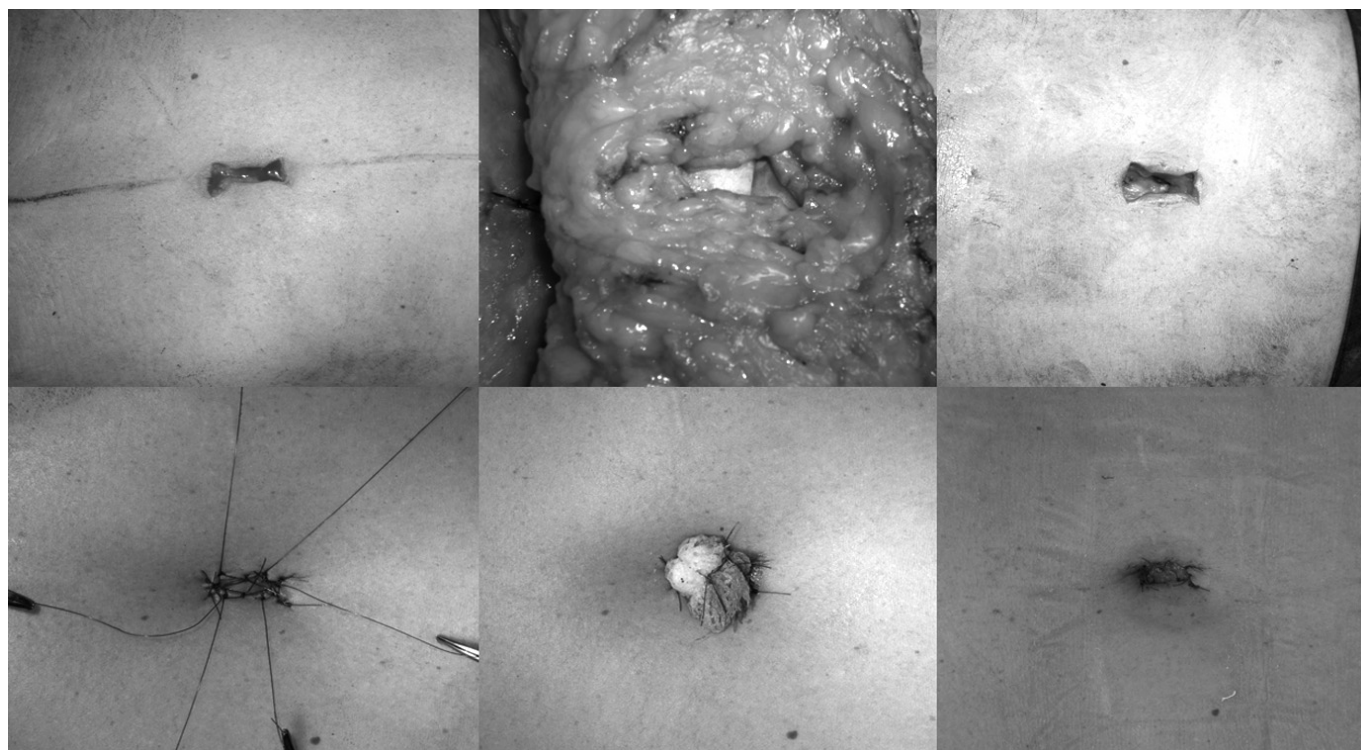


Fig. 1: Intra-operative views showing the steps of umbilical reconstruction. Above left: After choosing the new umbilical position on the abdominal flap, a small double opposing "Y" cutaneous incision is made in this point. Above centre: Internal aspect of the new umbilical site in the abdominal flap after Defatting; it is important to defat an area 2 to 3 cm wide around the umbilicus. Above right: External aspect of the new umbilical site after Defatting; the abdominal fascia is visualised. Below left/centre: The margins of the double opposing "Y" skin flaps are directly sutured to the abdominal rectus fascia with no absorbable sutures (nylon 4/0); four of these sutures are left longer and tied over a paraffin gauze patch to ensure deep umbilicus positioning. Below right: Clinical aspect of the new umbilicus 10 days after surgery; almost complete epithelisation can be noted.

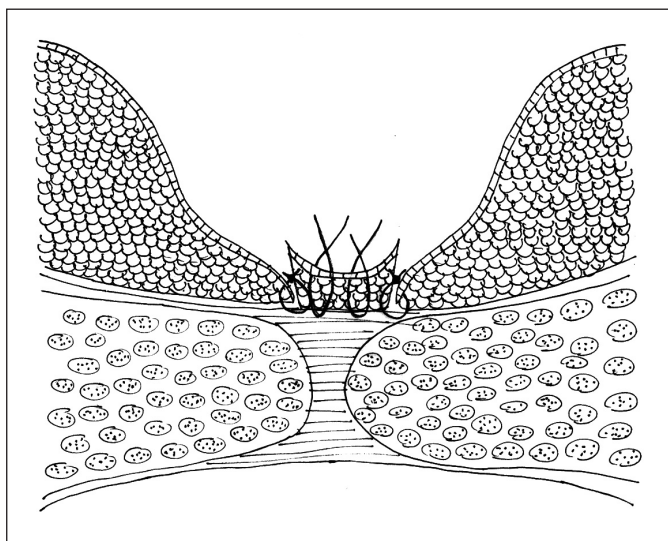


Fig. 2: Schematic design of neombilicus section: the margins of the double opposing "Y" skin flaps are directly sutured to the abdominal rectus fascia superiorly, inferiorly, and on both the lateral sides with no absorbable sutures (nylon 4/0).

time), the site of the new umbilicus reconstruction is determined by obtaining on the tensed abdominal flap the crossing point between two lines, the vertical xiphopubic line and the horizontal line traced above the antero-superior iliac spines. A small double opposing "Y" cutaneous incision is made in this point (Fig. 1). The vertical size should be the same of the original umbilicus (approximately 1 cm), the angle and the size of the four lateral incisions can be modified according to the width we want to obtain. Defatting is performed through the double opposing "Y" incision, which allows easy visualization of the abdominal fascia. It is important to defat an area 2 to 3 cm wide (Fig. 1). Two drains are placed under the tailored abdominal flap and the lower abdominal wound is sutured in a tension-free position. Thus, the margins of the double opposing "Y" incision are

sutured to the abdominal fascia with no absorbable sutures (nylon 4/0, Figg. 1, 2). Four of these sutures are left longer and tied over a paraffin gauze patch to ensure deep umbilicus positioning (Fig. 1).

## Results

Follow-up time ranged from 1 to 4 years.

General complications related to the abdominoplasty procedure were observed in three patients. A partial necrosis of the middle portion of the abdominal flap occurred in one inveterate smoker. In this case, the necrotic tissue was removed and complete wound healing was achieved by second intention in four weeks. In one diabetic patient, we observed abdominal suture dehiscence with local infection occurrence in the supra-pubic suture line a week after surgery. This complications was treated conservatively. Also, one case of seroma was observed in another patient, treated conservatively.

Specific complications of the new umbilical site have been reported in one case. In this patient, partial dehiscence of the wound margins occurred and wound healing with complete epithelisation of the was achieved in 4 weeks.

Complete healing of the new umbilicus was achieved in 14-21 days in the other nine cases. A three-dimensional umbilicus with a natural-looking vertical shape and satisfactory depression was created in all patients (Figg. 3, 4). During follow-up, no significant changes in shape, dimension and appearance were observed. These results were objectively confirmed by the not statistically significant modifications of depth values from one month to one year after surgery (Tab. I). The occurrence of cicatricial stenosis of the umbilicus was excluded in all patients by the possibility to easily introduce the modified 5 ml syringe (Fig. 3).

All patients were pleased with result. Evaluation of the Likert scale values of patients showed good judgments. The external reviewers confirmed the same aesthetic outcomes.

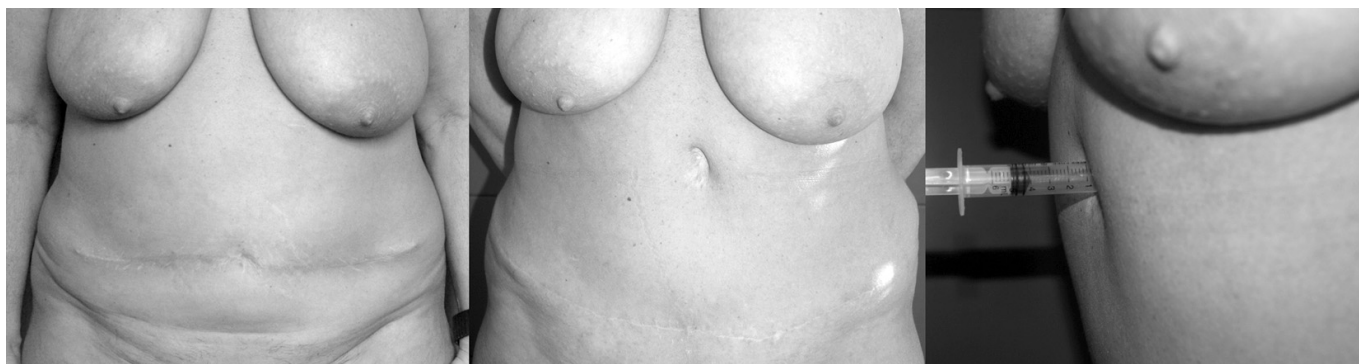

Fig. 3: Clinical aspect of case 1. Left: preoperative aspect of the umbilicus. Centre: postoperative view 3 years after surgery. Right: evaluation of umbilical depth with the modified syringe 3 years after surgery.

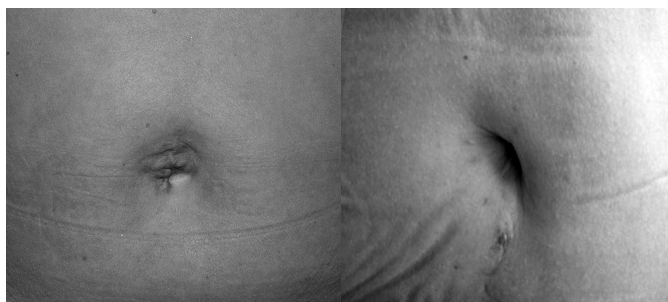


Fig. 4: Clinical aspect of case 2. Left: preoperative aspect of the umbilicus. Right: postoperative view 1 year after surgery.

TABLE I - Umbilical depth modification, expressed in ml, from 1 month (t1m) to 12 months after surgery (t12m).

	t1m	t12m	
Parameter	M ±SD	M ±SD	P
Depth (ml)	1.034 ± 1.61	1.007 ± 1.48	>0.05

M= medium; SD= standard deviation;

p=probability given by the Wilcoxon rank sum test

## Discussion

The umbilicus is an important aesthetic component of the abdominal wall<sup>27</sup>. It represents the only natural scar on the body and its absence gives an unnatural appearance to the abdomen<sup>28</sup>. Abdominal surgical procedures such as omphalocele or gastroschisis repair<sup>29</sup>, excision of skin cancer involving the umbilical stump, laparotomy and wide ventral herniorrhaphy<sup>30-32</sup>, as well as the treatment of umbilical endometriosis<sup>33,34</sup> may require omphalectomy. This situation can be corrected by the reconstruction of a new umbilicus, that can be performed during the same operative time or at a later stage.

There are many techniques for umbilical reconstruction<sup>35-51</sup>. The common objective of these techniques is to create a new umbilicus that looks natural in terms of location, size and depth.

In previous studies, we reported a versatile technique for umbilicoplasty based on an a double opposing "Y" incision on the abdominal flap to reposition and reshape the umbilicus. We now report a modification of this technique for the reconstruction of the umbilicus in patients who underwent previous or concurrent omphalectomy.

The author's technique for the neoumbilicoplasty consists in a double opposing "Y" cutaneous incision in the abdominal flap, a defatting under the double opposing "Y" skin flaps, and a firm suture of the double opposing "Y" skin flap to the abdominal fascia.

The advantages of the double opposing "Y" technique are numerous: it enables to create umbilical depth,

ensures optimal position and pulls the scar deep creating the new umbilicus. Moreover, the double opposing "Y" incision in the abdominal flap allows the achievement of different umbilical shapes, and reinforces the vertical orientation of the umbilicus. This technique can be performed either in obese or thin patients.

The presented technique produces a natural umbilicus and obtains patients' satisfaction. The reconstruction of the new umbilicus is easily performed, accurate and predictable. Finally, this technique allows a stable and long lasting result.

## Riassunto

Gli interventi di chirurgia addominale, quali la correzione delle ernie mediane, possono richiedere la rimozione dell'ombelico, il che fornisce all'addome un'aspetto innaturale. Questa situazione può essere risolta con un intervento di ombelicoplastica durante la stessa seduta operatoria o in un secondo tempo. In studi precedenti, abbiamo descritto una tecnica estremamente versatile per la ricostruzione dell'ombelico basata su un'incisione a doppia "Y" contrapposta. Nel presente studio, intendiamo mostrare l'applicazione di questa tecnica per la ricostruzione dell'ombelico in pazienti sottoposti a pregressa o concomitante onfalectomia.

È stato eseguito uno studio prospettico su 10 pazienti sottoposti ad intervento di ombelicoplastica con la tecnica della doppia "Y" contrapposta in seguito alla rimozione totale dell'ombelico. I risultati e il grado di soddisfazione dei pazienti sono stati valutati nel periodo postoperatorio per almeno un anno. Una siringa spuntata da 5 ml è stata impiegata per valutare la profondità ed il volume della cicatrice ombelicale. Le variazioni di volume a un mese e 12 mesi dall'intervento sono state analizzate statisticamente tramite il test di Wilcoxon. La completa guarigione del neo-ombelico veniva raggiunta nell'arco di 2-3 settimane in nove pazienti. In un solo caso, invece, si è verificata una deiscenza della ferita chirurgica e la riepitelizzazione si è completata in 4 settimane. Il periodo di follow-up varia da 1 a 4 anni. In tutti i pazienti, è stata creata una cicatrice ombelicale soddisfacente. Durante il follow-up, non si è osservato nessun cambiamento in termini di forma, dimensioni e aspetto dell'ombelico, né si è verificata alcuna stenosi della cicatrice ombelicale.

In conclusione, la tecnica della doppia "Y" contrapposta consente di creare un neo ombelico dall'aspetto naturale e può essere facilmente eseguita per la ricostruzione dell'ombelico in seguito ad onfalectomia.

## References

- 1) Baack BR, Anson G, Nachbar JM, White DJ: *Umbilicoplasty: The construction of a new umbilicus and correction of umbilical stenosis without external scars*. *Plast Reconstr Surg*, 1996; 97:227-31.

- 2) Cannistrà C, Pecorelli E: *Umbilical restoration in Abdominal dermolipectomy: A simple double-Y, double-M technique*. *Aesth Plast Surg*, 1999; 23:364-66.
- 3) Craig SB, Faller MS, Puckett CL: *In search of the ideal female umbilicus*. *Plast Reconstr Surg*, 2000; 105:389-92.
- 4) De Lacerda DJ, Martins DM, Marques A, Brenda E, De Moura Andrews J: *Umbilicoplasty for the abdomen with a thin adipose layer*. *Br J Plast Surg*, 1994; 47:386-87.
- 5) Delerm A: *Refinements in abdominoplasty with emphasis on reimplantation of the umbilicus*. *Plast Reconstr Surg*, 1982; 70:632-37.
- 6) Hoffman S: *A simple technique for locating the umbilicus in abdominoplasty*. *Plast Reconstr Surg*, 1989; 83:537-38.
- 7) Iida N, Ohsumi N: *Reconstruction of umbilical hypogenesis accompanied by a longitudinal scar*. *Plast Reconstr Surg*, 2003; 111:322-25.
- 8) Kurul S, Uzunismail A: *A simple technique to determine the future location of the umbilicus in abdominoplasty*. *Plast Reconstr Surg*, 1997; 100:753-54.
- 9) Lee MJ, Mustoe TA: *Simplified technique for creating a youthful umbilicus in abdominoplasty*. *Plast Reconstr Surg*, 2002; 109:2136-40.
- 10) Lim TC, Tan WT: *Managing the umbilicus during abdominoplasty*. *Plast Reconstr Surg*, 1996; 97:227-32.
- 11) Marconi F: *Reconstruction of the umbilicus: A simple technique*. *Plast Reconstr Surg J*, 1995; 95:1115.
- 12) Markman B, Barton Fe: *Anatomy of the subcutaneous tissue of the trunk and the lower extremity*. *Plast Reconstr Surg*, 1987; 80:248-54.
- 13) Masshida H, Montegut W, Phillips R: *A method of reconstructing a natural-looking umbilicus in Abdominoplasty*. *Ann Plast Surg*, 1997; 38:228-54.
- 14) Masuda R, Takeda A, Sugimoto T, Ishiguro M, Uchinuma E: *Reconstruction of the umbilicus using a reverse fan-shaped flap*. *Aesth Plast Surg*, 2003; 27:349-53.
- 15) Matsuo K, Kondoh S, Hirose T: *A simple technique for reconstruction of the umbilicus, using a conchal cartilage composite graft*. *Plast Reconstr Surg*, 1990; 86:149-51.
- 16) mcmillan wm: *Surgery of umbilical hernia with reconstruction of an artificial umbilicus*. *Q Bull Northwest Univ Med Sch*, 1955; 29(4):379-82.
- 17) Niranjana NS, Staiano JJ: *An anatomical method for re-sitting the umbilicus*. *Plast Reconstr Surg*, 2004; 113:2194-98.
- 18) Psillakis Jm, Appiani E, De La Plaza R: *Color Atlas of Aesthetic Surgery of the Abdomen*. 1991, Thieme Medical Publishers, New York.
- 19) Rozen SM, Redett R: *The Two-Dermal-Flap Umbilical Transposition: A Natural and Aesthetic Umbilicus after Abdominoplasty*. *Plast Reconstr Surg*, 2007; 119:2255-62.
- 20) Santanelli F, Mazzocchi M, Renzi L, Cigna E: *Reconstruction of a natural-looking umbilicus*. *Scand J Plast Reconstr Surg Hand Surg*, 2002; 36:183-85.
- 21) Sillitoe AT, Thornton DJ, Srinivasan J, Hart NB: *Elevation of the umbilicus with skin hooks aids excision in abdominoplasty*. *Plast Reconstr Surg*, 2005; 115:349.
- 22) Sugawara Y, Hirabayashi S, Asato H, Yoshimura K: *Reconstruction of the umbilicus using a single Triangular flap*. *Ann Plast Surg*, 1995; 34:78-80.
- 23) Suliman Mt: *A simple method for fishing out the umbilicus in abdominoplasty surgery*. *J Plast Reconstr Aesthet Surg*, 2009; 62(5):594.
- 24) Teimourian B, Marefat S: *Body Contouring with Suction-Assisted Lipectomy*. In: Cohen M (ed) *Mastery of Plastic and Reconstructive Surgery*, Little Brown, Boston, 1994; Vol 3:2186-200.
- 25) Not reported for blinded revision.
- 26) Not reported for blinded revision.
- 27) Akbaş H, Güneren E, Eroğlu L, Uysal OA: *Natural-looking umbilicus as an important part of abdominoplasty*. *Aesth Plast Surg*, 2003; 27:139-42.
- 28) Baroudi R: *Umbilicoplasty*. *Clin Plast Surg*, 1975; 2:431-48.
- 29) Pitanguy I: *Abdominal lipectomy: An approach to it through an analysis of 300 consecutive cases*. *Plast Reconstr Surg*, 1967; 40:384-410.
- 30) Al-Shaham A: *Neoumbilicoplasty is a Useful Adjuvant Procedure in Abdominoplasty*. *Can J Plast Surg*, 2009; 17:20-23.
- 31) Castillo Pf: *Umbilical Reinsertion in Abdominoplasty: Technique Using Deepithelialized Skin Flaps*. *Aesth Plast Surg*, 2007; 31:519-20.
- 32) Park S, Hata Y, Ito O, Tokioka K, Kagawa K: *Umbilical Reconstruction after Repair of Omphalocele and Gastroschisis*. *Plast Reconstr Surg*, 1999; 104:204-207.
- 33) Dessy LA, Buccheri EM, Chiummariello S, Gagliardi DN, Onesti MG: *Umbilical endometriosis, our experience*. *In Vivo*, 2008; 22(6):811-15.
- 34) Kokuba EM, Sabino NM, Sato H, Aihara AY, Schor E, Ferreira LM: *Reconstruction technique for umbilical endometriosis*. *Int J Gynaecol Obstet*, 2006; 94:37-40.
- 35) Abenavoli FM, Cusano V, Cucchiara V, D'Amico C, Corvelli L: *An idea for umbilicus reconstruction*. *Ann Plast Surg J*, 2001; 46:194.
- 36) Avelar JM: *Abdominoplasty: Technical refinement and analysis of 130 cases in 8 years' follow-up*. *Aesth Plastic Surg*, 1983; 7:205-12.
- 37) Borges AF: *Reconstruction of the umbilicus*. *Br J Plast Surg*, 1975; 28:75.
- 38) Juri J, Juri C, Raiden G: *Reconstruction of the umbilicus in abdominoplasty*. *Plast Reconstr Surg*, 1979; 63:580-82.
- 39) Kirianoff TG: *Making a new umbilicus when none exists*. *Plast Reconstr Surg J*, 1978; 61:603.
- 40) Dubou R, Ousterhout DK: *Placement of the umbilicus in an abdominoplasty*. *Plast Reconstr Surg*, 1978; 61:291-93.
- 41) Jamra FA: *Reconstruction of the umbilicus by a double V-Y procedure*. *Plast Reconstr Surg J*, 1978; 64:10.
- 42) Malic CC, Spyrou GE, Hough M, Fourie L: *Patient satisfaction with two different methods of umbilicoplasty*. *Plast Reconstr Surg*, 2007; 119:357-61.
- 43) Mateu LP, Hernandez C: *Neoumbilicoplasty through a pursestring suture of three defatted flaps*. *Aesth Plast Surg J*, 1997; 21:349.

- 44) Miller MJ, Balch CM: *"Iris" technique for immediate umbilical reconstruction*. *Plast Reconstr Surg*, 1993; 92:754-56.
- 45) Otto A, Wechselberger G, Schoeller T, Lille S: *A method of reconstructing a natural-looking umbilicus in abdominoplasty*. *Ann Plast Surg*, 1997; 38:228-31.
- 46) Ramirez OM: *Abdominoplasty and abdominal wall rehabilitation: a comprehensive approach*. *Plast Reconstr Surg*, 2000; 105:425-35.
- 47) Ribeiro L, Muzy S, Accorsi A: *Omphaloplasty*. *Ann Plast Surg*, 1991; 27:457-75.
- 48) Schoeller T, Wechselberger G, Otto A, Rainer C, Schwabegger A, Lille S, Ninković M: *New technique for scar less umbilical reinsertion in abdominoplasty procedures*. *Plast Reconstr Surg*, 1998; 102:1720-23.
- 49) Bruekers SE, Van Der Lei B, Tan TL, Luijendijk RW, Stevens HP: *"Scarless" Umbilicoplasty, A New Umbilicoplasty Technique and a Review of the English Language Literature*. *Ann Plast Surg*, 2009; 63:15-20.
- 50) Vernon S: *Umbilical Transplantation upward and abdominal contouring in lipectomy*. *Am J Surg*, 1957; 96:490-92.
- 51) Yotsuyanagi T, Nihei Y, Sawada Y: *A simple technique for reconstruction of the umbilicus, using two twisted flaps*. *Plast Reconstr Surg J*, 1998; 102:2444.