

Abdominal desmoid tumors

A new reconstructive approach



Ann. Ital. Chir., 2015 86: 78-84
pii: S0003469X15022526

Francesco Abbonante*, Diego Ribuffo**, Tiziana Vitagliano***, Maria Antonia Fiorillo****, Antonio Greto Ciriaco***, Andrea Conversi**, Manfredi Greco***

*U.O. of Plastic Surgery, Department of Surgery, Civil Hospital "Pugliese-Ciaccio", Catanzaro, Italy

**Unit of Plastic Surgery, Department of Surgery "P. Valdoni", University of Rome "Sapienza", Rome, Italy.

***Department of Clinical and Experimental Medicine, University "Magna Graecia" of Catanzaro Italy.

****Resident in U.O. of Plastic and Reconstructive Surgery, Department of Clinical and Experimental Medicine, University "Magna Graecia" of Catanzaro, Italy.

Abdominal desmoid tumors. A new reconstructive approach

INTRODUCTION: *Desmoid tumors are rare soft tissue tumors derived from musculoaponeurotic structures of the abdominal wall musculature. Although they are considered benign tumors because they don't metastasize to other parts of the body, they are clinically considered as malignant for their high tendency on infiltrative growth with local invasion and trend to recurrence after local excision. Several reconstructive techniques are proposed in the literature.*

METHODS: *Nine female patients with abdominal desmoid tumors underwent the removal of a mass of tissue running from the skin to peritoneum near the tumor with a safety margin in macroscopically normal tissue at least of 5 centimeters from the edge of the tumor. After wide excision, a polypropylene mesh was placed in the rear muscular pocket without anchoring suture (sliding mesh sutureless hernioplasty)*

RESULTS: *No patients had perioperative complications or abdominal wall weakness or an incisional hernia in the following 5 years.*

CONCLUSIONS: *We consider this technique of abdominal wall reconstruction after desmoid tumor removal a simple procedure that reduces relapsing events and recurrences of abdominal hernia, reducing tension and pain caused by the traditional suture repair technique. Level of evidence: IV.*

KEY WORDS: Abdominal tumors, Abdominal wall reconstruction, Desmoid tumors, Mesh.

Introductions

Desmoid tumors, also known as aggressive fibromatosis, are rare soft tissue tumors representing the 0.03% of all neoplasms derived from fibrous connective tissue ^{1,2}.

Their incidence is currently estimated in 2-4 new cases per million of people per year. These tumors arise from musculoaponeurotic structures of the abdominal wall musculature by an abnormal proliferation of myofibroblasts of those structures ³. The term "desmoid" refers, infact, to the hard, tendon-like appearance of the tumor. They are clinically characterized by pain, neurological symptoms or can be present only like asymptomatic palpable mass (Fig. 1). Although the etiology of these tumors is unknown, hormonal, genetic and physical factors play an important role in their development and growth ⁴. Abdominal desmoid tumors occur more frequently sporadically or in patients with familial adenomatous polyposis (FAP)⁵ and in post-partum women ⁶.

Pervenuto in Redazione Dicembre 2013. Accettato per la pubblicazione Febbraio 2014

Correspondence to: Manfredi Greco, MD, Department of Plastic and Reconstructive Surgery University "Magna Graecia" of Catanzaro, Viale Europa, loc. Germaneto, 88100 Catanzaro, Italy (e-mail: manfredigreco@unicz.it)

The World Health Organization considers those tumors like benign lesions because they are unable to metastasize to other parts of the body, even if they are clinically considered as malignant because they have high propensity on infiltrative growth with local invasion and tendency to recurrence after local excision⁷. Local recurrence is frequent and most closely related to the adequacy of surgical excision.

Desmoid tumors can be classified in⁸:

- Abdominal: localized in musculoaponeurotic structures of the abdominal wall musculature, especially in the rectus and internal oblique muscles and in their fascial covering⁹;
- Intra-abdominal: associated with the infiltration of abdominal viscera and pelvic or mesenteric vessels, or retroperitoneal fibromatosis¹⁰;
- Extra-abdominal: in the tendons and ligaments of arms, legs, head and neck regions, or chest wall^{11,12}.

Prognosis depends on tumor location: intra-abdominal desmoid tumors have the worst prognosis because they can cause intestinal or ureter obstruction, fistula formation and can also invade abdominal vessels¹³. When the desmoid tumor is localized in the anterior abdominal wall, the possibility of local recurrence, the necessity of a radical resection and the consequent reconstruction create surgical challenges. Our surgical treatment is characterized by an innovative technique. The aim of this study is to demonstrate the clinical effectiveness of the sutureless wall abdominal reconstruction for very large defects

after desmoid tumour removal through a ten years' experience of nine cases.

Materials and Methods

This is a retrospective study of 9 female patients (mean age 32.6 years old, range 29-38 years), with desmoid tumor of the anterior abdominal wall treated from March 2000 to June 2010 at our Department (Table I).

All tumors had abdominal localization, with a mean size of 6,7 centimetres (range 5,5-7,3 centimetres).

Six patients had previous pregnancies; two had history of colectomy (one total and one half) for familial adenomatous polyposis (FAP); only in one case the tumour had an unknown origin.

Pre operative studies were based on ultrasound scan (Fig. 2) and CT or MRI exams (Fig. 3), which showed the abdominal mass without infiltration of abdominal viscera and pelvic or mesenteric vessels, or retroperitoneal fibromatosis.

The diagnosis of desmoid tumor was confirmed histologically in all patients.

No patient underwent hormone or radio-chemotherapy before or after surgical treatment.

Follow-up (from 12 to 72 months) was based on clinical and radiological controls, which showed no recurrence of disease in all patients.

Table I - Data of individual cases.

Patient	1	2	3	4	5	6	7	8	9
Age	29	31	33	30	29	35	38	32	37
Method of diagnosis	CT scan US scan NMR scan	CT scan US scan NMR scan	CT scan US scan	CT scan US scan	CT scan US scan	CT scan US scan	CT scan US scan	CT scan US scan	CT scan US scan
Tumour maximum size (cm)	5,7	7,1	7	6,8	6,5	5,9	7,1	7,3	6,9
Other organ involvement	None	None	None	None	None	None	None	None	None
Pre-operative treatment	None	None	None	None	None	None	None	None	None
Follow-up (months)	72	48	12	24	72	12	36	12	24
Other	Colectomy for FAP	Colectomy for FAP	Previous pregnancy	Previous pregnancy	Unknown origin	Previous pregnancy	Previous pregnancy	Previous pregnancy	Previous pregnancy
Recurrence of disease	No	No	No	No	No	No	No	No	No

CT: Computed tomography; NMR: Nuclear Magnetic Resonance; US: ultrasound; FAP: familial adenomatous polyposis.

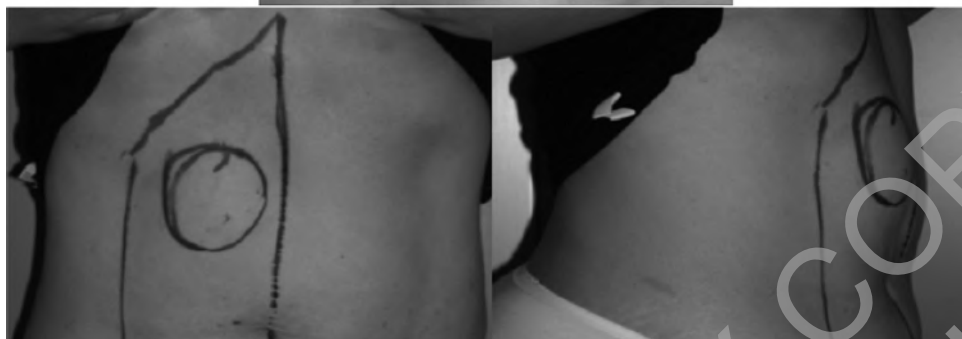
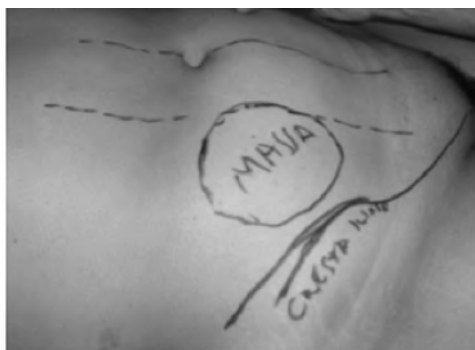
Fig. 1: Asymptomatic palpable masses of the abdominal wall musculature.

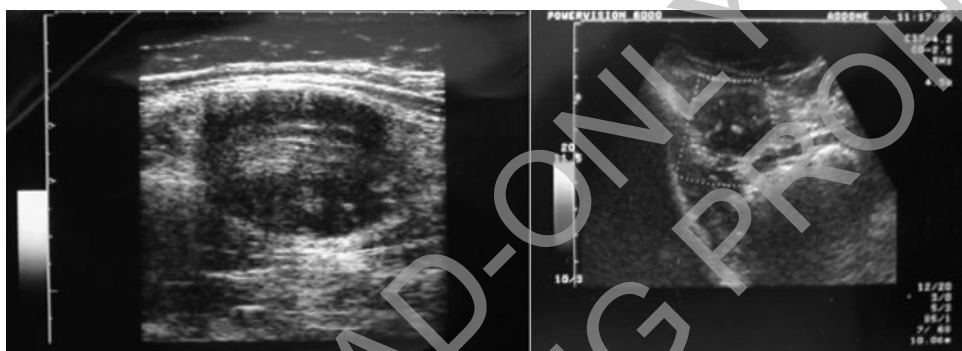

Fig. 2: Ultrasound scan shows a large hypoechoic mass located in the rectus abdominis muscle.

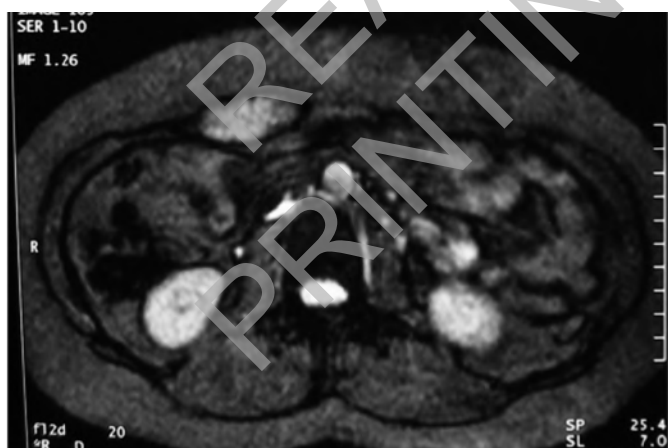


Fig. 3: NMR scan image.

SURGICAL TECHNIQUE

All 9 patients underwent the same surgical procedure, characterized by the following surgical steps (Fig. 4):

- A) skin incision following the lozenge designed on the skin over the tumour;
- B) isolation and visualization of rectus abdominal muscle fascia and the medial portion of transverse muscle;
- C) opening of the muscular and peritoneal layers;
- D) demolition of the rectus abdominal muscle from the insertion on the pubic bone to the transverse umbilical fascia when tumour is located below the navel; if the tumor is located in the upper half of the abdomen, the removal had been conducted from the immediate insertion on the costal arch far since below the umbilical transverse line;
- E) muscle demolition and tumour removal with a normal-tissue rim of 5 cm all around the tumour;
- F) closure of the peritoneum by a single continuous polypropylene type 0 suture;
- G) abdominal wall reconstruction is the last step of this surgical treatment.

The anatomical gap (Fig. 5) after tumor removal is usually very wide, because radical excision is carried out

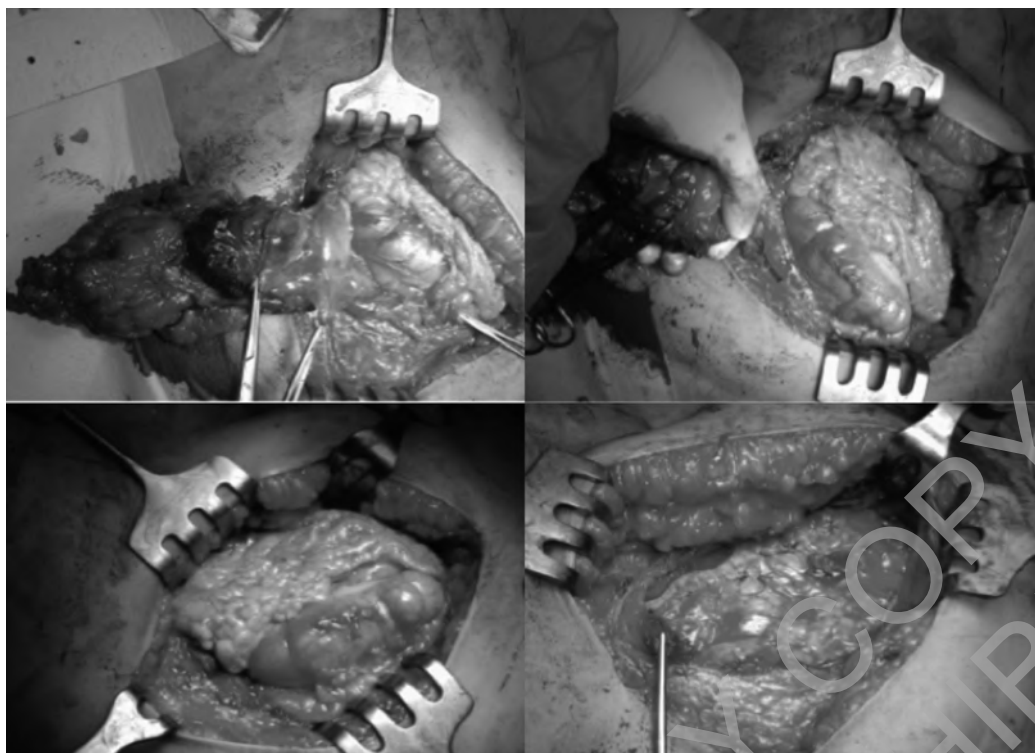


Fig. 4: Desmoid tumor removal and peritoneum closure.

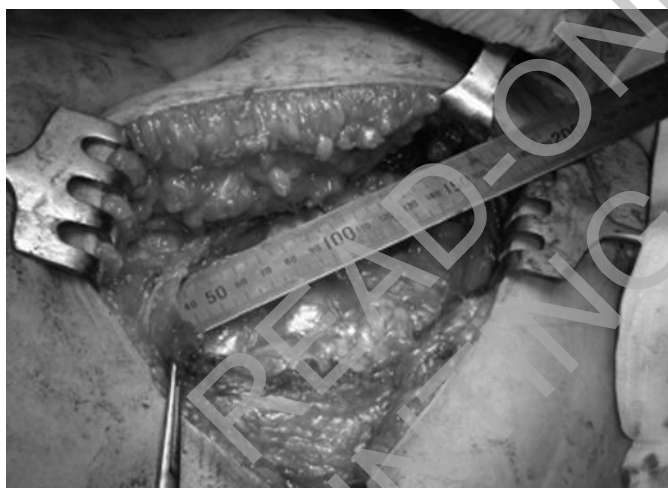

Fig. 5: Anatomical gap after tumor removal.



Fig. 6: The 80 grams/m² polypropylene mesh.

from skin to peritoneum, sacrificing 5 cm of safe tissues all around the tumour. So immediate closure is impossible.

This personal reconstructive technique is done with a large detachment of the peritoneum and rear rectus abdominal muscle fascia and by using an implantation of a 80 grams/m² density polypropylene mesh (Fig. 6) without anchoring suture.

Other techniques involve absorbable or not absorbable suture to anchor the mesh and to prevent its migration or wrinkling, but this causes extensive tissue tension and prolonged postoperative pain¹⁴.

We placed the mesh in the rear muscular pocket with no stitches, preserving its original form with no distortion, retraction, migration, wrinkling or curling due to the suture.

This technique, known as *sliding mesh sutureless hernioplasty*, is tension-free, so the mesh can adapt itself to every movement of the abdominal muscles without functional limitations due to pain caused by suture and muscular tension^{15,16} (Fig. 7).

A suction drain was always positioned over the mesh. Muscular fascia was closed by a polypropylene type 0 suture in interlocking.

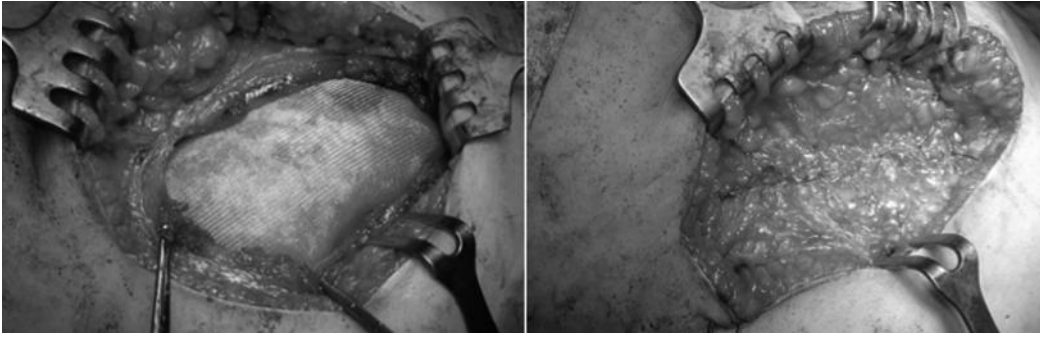

Fig. 7: Mesh sutureless hernioplasty.

Compressive dressing were always suggested to prevent blood and serum collects.

Results

No patient had perioperative complications. The median hospital stay was 7 days (range form 6 to 12). All pathological margins were clear of disease. During the postoperative course, after 7 years from the first case and after 6 months from the last case, no patient had either an abdominal wall weakness or an incisional hernia. The patients carried out every year a CT exam for the first 5 years and an ultrasound scan every six months in the first two years, then once a year to exclude relapsing events and herniation events and herniations (Fig. 8).

Discussion and Conclusion

Desmoid tumours are rare fibromatous lesions that are the results of abnormal proliferation of myofibroblast cells derived from fascial or muscle-aponeurotic structures of the abdominal wall. Desmoids tumours are more

frequent in the middle-age women and can be in association with familial adenomatous polyposis.

Causes of the desmoids tumors are unknown, but hormonal, genetic and physical factors play an important role in their development.

The differential diagnosis is not very easy because they have to be distinguished from benign conditions such as scar, nodular fasciitis, benign fibrous histiocytoma and finally from fibrosarcoma that represent a possible malignant evolution of desmoids tumors. So the pre-surgical CT exam and the post-surgical hystologic exam are two important elements for the diagnosis. Histologically the nodules consisted of well-differentiated fibroblastic spindle-shaped cells, surrounded by a large amount of collagen fibers.

These cells infiltrate the abdominal musculature^{17, 18}.

The treatment of desmoids tumors remains an enigma. Although there are other palliative treatments like radiotherapy or pharmacological therapy, surgery is the first-line treatment^{19, 20}.

Radical resection plays a central role in the treatment of abdominal wall desmoid tumors²¹.

Many reports describing good responses of desmoid tumors to irradiation, alone or before surgery or as adjuvant therapy in patients with positive resection margins, but our opinion is that obtaining a wide disease-free margin is crucial for reducing the recurrence rate.

In fact, local recurrence have been reported in many studies.

Our surgical treatment aims at remove of a mass of tissue running from the skin to peritoneum near the tumor with a safety margin in macroscopically normal tissue at least of 5 centimetres from the edge of the tumor (Fig. 9).

Abdominal wall reconstruction is the last step of the surgical treatment: because of radical and wide excision, our personal reconstructive technique is done with a large detachment of the peritoneum and rear rectus abdominal muscle fascia and by using an implantation of a 80 grams/m² density polypropylene mesh without suture anchoring. This technique, known as *sliding mesh sutureless hernioplasty*, takes advantage of the good adhesive features of the mesh placed in the retromuscular or preperitoneal compartment, prevents wrinkling, folding, and mesh migration due to the suture. Moreover, this leads

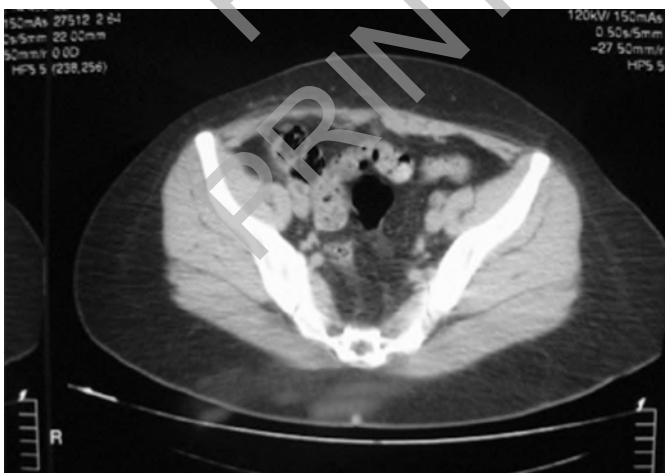

Fig. 8: CT scan image after 1 year: note the absence of the right rectus abdominis muscle.

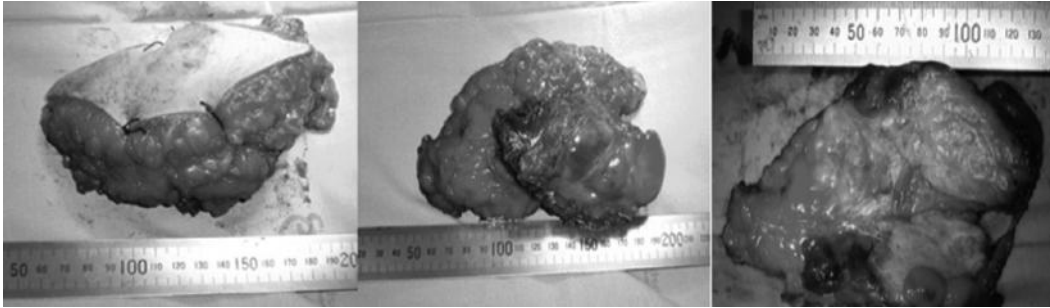


Fig. 9: Tumour removal with skin and healthy tissue rim of 5 cm all around the tumor.

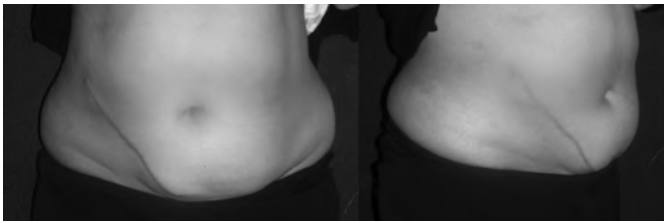


Fig. 10: Clinical results after 1 year.

to a full integration of the prosthesis into the abdominal wall, which is essential to reduce tension and pain caused by the traditional suture repair techniques^{14, 15, 16}. Furthermore, because the mesh is not sutured, it can move synergically with the abdominal wall muscle during respiratory acts.

We also compared the nine patients of this study, reconstructed by sutureless technique, with eleven patients operated in our department with the traditional technique in the previous years.

Populations are superimposable for age, tumor size and anamnesis.

The main difference between two populations is in the post operative period which is more comfortable, painless in the sutureless hernioplasty. In this population we observed also a faster recovery after surgical operation with a quick resumption of work or daily activity.

In conclusion, we consider the sutureless approach extremely useful for surgeons: this technique of abdominal wall reconstruction after desmoid tumor removal has the advantage to be a simple procedure without compromising outcomes and reduces relapsing events and hernia recurrences of abdominal wall in all our patients (Fig. 10).

Riassunto

INTRODUZIONE: I tumori desmoidi sono rari tumori dei tessuti molli derivanti da strutture muscolo-aponeurotiche della parete addominale. Anche se sono considerati tumori benigni perché non metastatizzano in altre parti del corpo, sono considerati clinicamente maligni a causa della loro elevata tendenza alla crescita infiltrativa con

invasione locale e della propensione alla recidiva dopo escissione locale.

METODI: 9 pazienti femmine con tumori desmoidi addominali sono state sottoposte ad asportazione di tessuto che va dalla pelle fino al peritoneo in prossimità del tumore con un margine di sicurezza di tessuto normale, macroscopicamente, di almeno 5 centimetri dal margine del tumore. Dopo ampia escissione, è stata posizionata nella tasca muscolare posteriore una rete in polipropilene senza sutura di ancoraggio

RISULTATI: Nessun paziente ha avuto complicanze perioperatorie, debolezza della parete addominale o un'ernia incisionale nei successivi 5 anni.

CONCLUSIONI: Noi consideriamo questa tecnica di ricostruzione della parete addominale dopo la rimozione del tumore desmoide, una procedura semplice che riduce la possibilità di eventi recidivanti e le ricorrenze di ernia addominale, poiché riduce la tensione e il dolore causato dalla tecnica tradizionale.

References

1. Sutton RJ, Thomas JM: *Desmoid tumours of the anterior abdominal wall*. Eur J Surg Oncol, 1999; 25:398-400.
2. Bertani E, Chiappa A, Testori A, et al.: *Desmoid tumors of the anterior abdominal wall: results from a monocentric surgical experience and review of the literature*. Ann Surg Oncol, 2009; 16:1642-649.
3. Mungas JE, Platz CE, Block GE: *Desmoid tumours of the abdominal wall*. Surg Clin North Am, 1976; 56:207-218.
4. Reitamo JJ, Scheinin TM, Hayry P: *The desmoid syndrome: New aspects in the cause, pathogenesis and treatment of the desmoid tumour*. Am J Surg, 1986; 151:230-37.
5. Lefevre JH; Parc Y, Kernéis S, et al.: *Risk factors for development of desmoid tumours in familial adenomatous polyposis*. Br J Surg, 2008; 95:1136-139.
6. Cormio G, Cormio L, Marzullo A, et al.: *Fibromatosis of the female pelvis*. Ann Chir Gynaecol, 1997; 86:84-89.
7. Posner MC, Shiu MH, Newsome JL, et al.: *The desmoid tumour: not a benign disease*. Arch Surg, 1989; 124:191-96.
8. Allen PW: *The Fibromatosis: A clinicopathologic classification based on 140 cases*. Am J Surg Pathol, 1977; 1:255-60.

9. Caldwell EH: *Desmoid tumour: musculoaponeurotic fibrosis of the abdominal wall*. Surgery, 1976; 79:104-106.
10. Remmele W, Muller LH, Paulus W: *Primary mesenteritis, mesenteric fibrosis and mesenteric fibromatosis. Report of four cases, pathology and classification*. Pathol Res Pract. 1988; 184:77-85.
11. Karakousis CP, Mayordomo J, Zografos GC, et al.: *Desmoid tumours of the trunk and extremity*. Cancer, 1993; 72:1637-640.
12. Batsakis JC, Raslan W: *Extra-abdominal desmoid fibromatosis*. 1994; 103:331-34.
13. Ballo MT, Zagars GK, Pollack A, et al.: *Desmoid tumours: Prognostic factors and outcome after surgery, radiation therapy, or combined surgery and radiation therapy*. J Clin Oncol, 1999; 17:158-167.
14. Stoeckle E, Coindre JM, Longy M, et al.: *A critical analysis of treatment strategies in desmoid tumours: A review of a series of 106 cases*. Eur J Surg Oncol, 2009; 35(2):129-34.
15. Witkowski P, Abbonante F, Fedorov I: *Are mesh anchoring sutures necessary in ventral hernioplasty? Multicenter study*. Hernia, 2007; 11(6):501-508.
16. Trabucco EE, Trabucco AF: *Tension-free sutureless preshaped mesh hernioplasty*. In: Fitzgibbons RJ, Greenburg AG, eds. Nyhus and Condons Hernia, 5th edn. Philadelphia: Lippincott Williams and Wilkins; 2002:159-64.
17. Hasegawa T, Hirose T, Kudo E, et al.: *Cytoskeletal characteristics of myofibroblasts in benign neoplastic and reactive fibroblastic lesions*. Virchows Arch Pathol Anat, 1990; 416:375.
18. Feiner H, Kaye GI: *Ultrastructural evidence of myofibroblasts in circumscribed fibromatosis*. Arch Pathol, 1976; 100:265.
19. Nuyttens JJ, Rust Pf, Thomas Cr Jr, et al.: *Surgery versus radiation therapy for patients with aggressive fibromatosis or desmoid tumours: a comparative review of 22 articles*. Cancer. 2000; 88:1517-523.
20. Lev D, Kotlingam D, Wei C, et al.: *Optimizing treatment of desmoid tumours*. J Clin Oncol, 2007; 25:1785-791.
21. Mikhopoulou A, Germanos S, Kanakopoulos D, et al: *Management of a large abdominal wall desmoids tumor during pregnancy. Case report*. Ann Ital Chir, 2010; 81:153-56.

READ-ONLY COPY
PRINTING PROHIBITED