



# A fatal complication of an incarcerated diaphragmatic hernia: pyo-pneumopericardium due to a gastro-pericardial fistula

## Case report and literature review

Bogdan Andrei Suciu\*, Mihaela Opris\*\*, Vasile Bud\*, Constantin Copotoiu\*, Klara Brînzaniuc\*\*\*, Mircea Mureşan\*\*\*

\*1st Surgical Clinic, University County Hospital Mures, University of Medicine and Pharmacy Târgu Mureş

\*\*Cardiology Department, Institute for Emergency Cardiovascular Diseases and Transplant Tg. Mures, University of Medicine and Pharmacy Târgu Mureş

\*\*\*Department of Anatomy, University of Medicine and Pharmacy Târgu Mureş

## A fatal complication of an incarcerated diaphragmatic hernia: pyo-pneumopericardium due to a gastro-pericardial fistula. Case report and literature review

**INTRODUCTION:** *The pyo-pneumopericardium is a very rare complication of an incarcerated diaphragmatic hernia. Usually, it depends on the existence of a gastropericardial fistula and, in most cases, it is a deadly complication.*

**CASE REPORT:** *We present the case of a 65 year old man who was admitted to our emergency service with clinical signs of septic shock. With the help of the CT scan a pyo-pneumopericardium and incarcerated diaphragmatic hernia was diagnosed. He was subjected to emergency surgical intervention with double approach (thoracic and abdominal), discerning during surgery the existence of a pericardial abscess due to a gastro-pericardial fistula due to an incarcerated diaphragmatic hernia. The gastric fundus was resected with abolition of the gastro-pericardial fistula, evacuation of the pericardial abscess, performing the splenectomy (in order to have a better surgical access) and adequate treatment of the diaphragmatic hernia. Despite the medical efforts, the patient died on the 10th postoperative day due to septic complications. To our knowledge this is the first case reported in the literature of gastro-pericardial fistula complicated with pyo-pneumo-pericardium due to an incarcerated diaphragmatic hernia. In such cases we consider that only by performing a double surgical approach (thoracic and abdominal) we can provide a proper resolution of the case, also based on the objective situation found during surgery, where the splenectomy can provide an easier approach to the diaphragmatic hernia.*

**KEY WORDS:** Diaphragmatic hernia, Gastropericardial fistula, Pyo-pneumopericardium

### Introduction

The pyo-pneumopericardium is a particularly severe disorder which is usually terminal. One of the most frequent conditions that can determine the appearance of

a pyo-pneumopericardium is a digestive-pericardial fistula. The gastro-pericardial fistula is an extremely rare complication of a diaphragmatic hernia. Usually it occurs due to the perforation of the stomach or esophagus into the pericardial cavity <sup>1</sup>. We report the case of a 65-year-old male admitted to our service with the diagnosis of pyo-pneumopericardium due to a gastro-pericardial fistula caused by an incarcerated diaphragmatic hernia.

### Case presentation

A 65-year-old man presented in the emergency department at our hospital with thoracic pain, dyspnea and

Pervenuto in Redazione Luglio 2015. Accettato per la pubblicazione Settembre 2015.

Correspondence to: Opris Mihaela, Tg Mures, Str. Saliste 2, 540520, Tg. Mures, Romania(e-mail: drmihaelaopris@gmail.com)

tachypnea, tachycardia, fever and severe fatigue. The patient had been experiencing constant thoracic pain for a few months which had worsened in the last week. From his medical history we noticed that he had not had gastro-duodenal ulcers, or undergone any surgical treatments. The patient had not previously been diagnosed with a diaphragmatic hernia. He reported no cough, upper respiratory symptoms other than aforementioned dyspnea and tachypnea, edema or pain in the legs; and no weight change, diarrhea, jaundice, or joint pain.

On examination the pain was located in the epigastric region and was non-radiating; this did not alter with a change in position or with food intake. His pulse was 125 beats per minute (bpm) and regular, blood pressure 100/85 mmHg, the respiratory rate was 22 breaths per minute, and an oxygen saturation of 94% while he was breathing ambient air, the temperature was 38. Cardiac examination revealed a regular tachycardia and a holosystolic apical murmur, with no appreciable gallop, heave or thrill. Examination of the lungs revealed rales at the left base. The abdomen was soft and non-tender, without abdomino-jugular reflex. The liver edge, which was palpable, 4 cm below the costal margin, was not tender. Distal pulses were thread.

At the time laboratory tests were normal except for elevated white blood cells. The results from the enhanced computed tomography of the thorax and abdomen showed pericardial effusion and a thickened pericardium caused by a gastro-pericardic fistula. The electrocardiogram showed a normal sinus rhythm, left ventricular hypertrophy by voltage, subtle PR-segment depression, and ST-segment elevations. A diagnosis of pericarditis was made.

Surgical treatment was performed. We used a combined surgical approach: a left postero-lateral thoracotomy combined with a median laparotomy. We also carried out a phrenotomy and pericardiectomy. Intraoperatively we discovered the existence of an abscess in the pericardial cavity. We also found a gastro-pericardial fistula as a complication of an intrapericardial necrosis of the gastric fundus due to an incarcerated diaphragmatic hernia. We resected the hernia strangulation ring; numerous tissue and fluid samples were sent for cultures and pathological evaluation. We carried out a splenectomy, for a clear access to the pericardial cavity from the trans-diaphragmatic approach because the patient had an enlarged spleen. A resection of the gastric fundus was performed and we performed surgery on the diaphragmatic hernia. At the end of the intervention drainage tubes were inserted in the pericardium, left pleural cavity and abdominal cavity.

Despite adequate debridement and antibiotic coverage, the patient's fever persisted postoperatively without a source. Ten days after the surgical intervention, the patient died.

Written informed consent was obtained from the patient for the publication of this case report.

## Discussion

Pyo-pneumopericardium is a very rare disease. For most patients it is a fatal condition because of the subsequent septic shock<sup>2</sup>. The main causes of the pyo-pneumopericardium are traumatic and non-traumatic conditions. Non-traumatic conditions are caused by thoracic

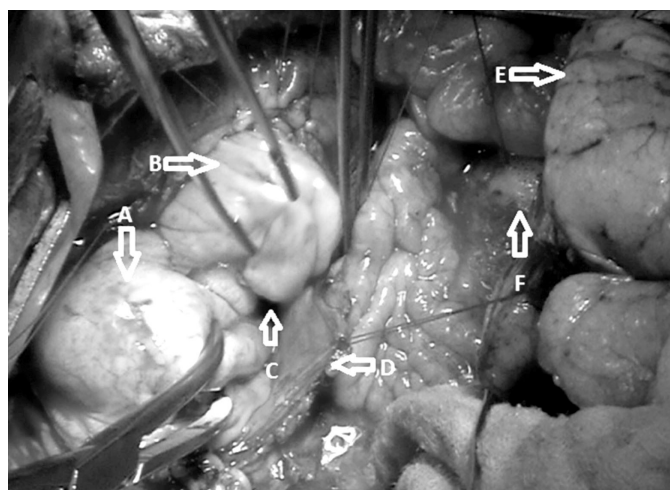


Fig. 1: Postero-lateral left thoracotomy with phrenotomy and pericardiectomy, (A) the gastric fundus is situated intrathoracic, (B) the great omentum, (C) the strangulation orifice of the diaphragmatic hernia, (D) the sectioned margin of the diaphragm, (E) the left inferior lung lobe, (F) the pericardiectomy orifice through which a purulent fluid is externalized.

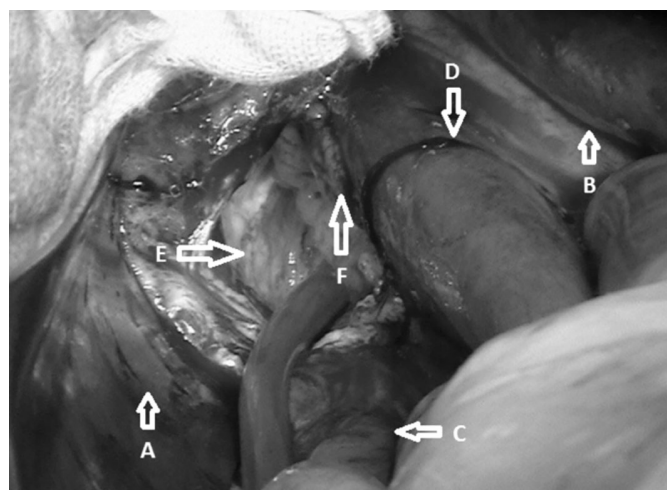


Fig. 2: Median laparotomy with phrenotomy and pericardiectomy, (A) the left lobe of the liver, (B) the spleen, (C) the abdominal esophagus, (D) the strangulation orifice of the diaphragmatic hernia, (E) the orifice of phrenotomy and pericardiectomy, intrapericardial abscess, (F) the necrotic margins of the stomach situated intrapericardiac, the gastric mucosa.

diseases: esophagus perforation with or without ulcerative lesions or malignancy of the esophagus, the abdominal source of the pyo-pneumopericardium could be liver abscesses that penetrate the diaphragm, a gastrointestinal fistula caused by incarcerated diaphragmatic hernias or gastric and intestinal ulcers. A literature review revealed 44 cases of gastro-pericardial fistulas published to date <sup>3</sup>. A gastro-pericardial fistula may occur due to a drilling of the wall caused by gastric ulcers, gastric cancer, incarcerated diaphragmatic hernia or secondary to surgery of the esophagus and stomach <sup>2</sup>. In 2004 Grandhi reported a rare case similar to ours but the difference was that in his case the patient did not have associated pyopericardium <sup>4</sup>.

Usually patients with diaphragmatic hernias have no specific symptoms, which is an important causal factor in the delayed diagnosis <sup>5</sup>. Our patient underwent extensive cardiac and pulmonary testing, but the lack of other cardiac or pulmonary signs or symptoms, made a diagnosis of the source of his thoracic pain unlikely. There was no evidence of painful rib lesions or costochondritis. The distribution of the pain radiating from the back to the anterior chest wall also made thoracic radiculopathy (neuropathic pain emanating from a thoracic root nerve or intercostal nerve) a significant diagnostic possibility. Chest radiography commonly shows pneumopericardium. Computed tomography also identifies pyo-pneumopericardium, and may reveal extravasation of contrast material in the pericardium. The electrocardiogram only shows signs of the pericarditis and the ecocardiography shows the presence of the pericardial collection.

Usually, a diagnosis of gastro-pericardial fistula is difficult to determine <sup>6</sup>. Modalities used to evaluate a gastro-pericardial fistula do not uniformly reveal a clear diagnosis. When a gastro-pericardial fistula is suspected, a water soluble contrast agent should be used and barium avoided. The rationale for the gastroscopy in this condition is questionable because it may depict the fistula or the associated lesions, but air insufflation could provoke tension pneumopericardium and consequent cardiac tamponade.

The mainstay of treatment for gastro-pericardial fistula is prompt surgery. Successful treatment includes early pericardial drainage by pericardial window and corrective surgery of the gastric fistula if possible. Other authors recommend conservative treatment of the gastro-pericardial fistula, serial pericardiocentesis, antibiotics and parenteral nutrition <sup>7</sup>, however the associated mortality of conservative treatment is high. In the medical literature there are only two cases cited of patients that survived after conservative treatment <sup>8</sup>.

Surgical intervention is the primary treatment if possible. It is extremely important to quickly evacuate the pericardial collection for heart decompression, suppression of the gastric fistula and perform a surgical correction of the diaphragmatic hernia. Positive outcomes are highly correlated with early correct diagnosis and surgical intervention even if the mortality of such cases is higher than 85%.

<sup>9,10</sup>. For patients treated either conservatively or surgically, the most common cause of death is septic shock, which is what happened to our patient.

To our knowledge this is the first case reported in the literature of gastro-pericardial fistula complicated with pyo-pneumopericardium due to an incarcerated diaphragmatic hernia. In such cases we consider that only by practicing a double surgical approach (thoracic and abdominal) we can provide a proper resolution of the case. Also based on the reality during surgery, the splenectomy can provide an easier approach to the diaphragmatic hernia.

## Acknowledgement

This study was supported by the University of Medicine and Pharmacy Târgu Mureș, with funds made available through internal competition for Scientific Research Grants 2013.

## Riassunto

**INTRODUZIONE:** Il pio – pneumopericardio è una complicanza particolarmente rara di un'ernia diaframmatica incarcerata. Di solito la causa del pio – pneumopericardio è rappresentata dall'esistenza di una fistola gastro – pericardica e nella maggior parte dei casi, è una complicanza mortale.

**OSSERVAZIONE PERSONALE:** Presentiamo il caso di un uomo di età 65 anni il quale è stato ricoverato nel nostro servizio di urgenza con segni clinici di shock settico. In seguito all'esame di tomografia computerizzata è stata messa la diagnosi di pio – pneumopericardio ed ernia diaframmatica incarcerata. Si è intervenuto chirurgicamente d'urgenza con doppio approccio (toracico e addominale), in via intraoperatoria, evidenziandosi l'esistenza di un ascesso pericardico dovuto a una fistola gastro - pericardica formata a seguito di un'ernia diaframmatica incarcerata. Si è praticata la resezione del fondo gastrico con la rimozione della fistola gastro – pericardica, l'evacuazione dell'ascesso pericardico, splenectomia (per avere un accesso chirurgico più facile) e il trattamento adeguato dell'ernia diaframmatica. Nonostante gli sforzi medici, il paziente è deceduto nel giorno 10° post – operazione a causa delle complicanze settiche.

Dalle nostre conoscenze, questo è il primo caso presentato nella letteratura di fistola gastroperocardica complicata con pio – pneumopericardio a causa di un'ernia diaframmatica incarcerata. In questi casi consideriamo che solo praticando un approccio chirurgico doppio (toracico e addominale) è possibile garantire una risoluzione corretta del caso; inoltre, a seconda della realtà intraoperatoria, l'effettuazione della splenectomia può garantire un approccio più adatto al livello dell'ernia diaframmatica.

## References

1. Chapman PA, Boals JR: *Pneumopericardium caused by giant gastric ulcer*. Am J Roentgenol, 1998; 171:1669-70.
2. Monro JL, Nicholls RJ, Hatley W, Murray RS, Flavell G: *Gastropericardial fistula a complication of hiatus hernia*. Br J Surg, 1974; 61, 6:445-47.
3. Imran HU, Booth K, McManus K: *Is the way to a man's heart through his stomach? Enteropericardial fistula: case series and literature review*. Dis Esophagus, 2013; 26(5):457-64.
4. Grandhi TM, Rawlings D, Morran CG: *Gastropericardial fistula: A case report and review of literature*. Emerg Med J, 2004; 21:644-45.
5. Jeyarajah R, Harford WV: *Abdominal hernias and gastric volvulus, Slisenge and Fordtran's gastrointestinal and liver disease*. 8<sup>th</sup> ed. Saunders: Elsevier; 2006.
6. Gabor S, Woltsche M, Maier A, Smolle-Juttner FM: *Pneumopericardium due to intrapericardial perforation of a gastric ulcer*. Eur J Cardiothorac Surg, 2003; 23:131-33.
7. Chauhan A, Perry I, Veitch A, Li P, Rattehalli D, Brookes MJ: *Gastropericardial fistula: A potential role for conservative treatment*. Eur J Gastroenterol Hepatol, 2012; 24, 11:1341-343.
8. Hall MN, Little Jr. JM: *Penetration of the pericardium by a gastric ulcer. Survival after pericardiocentesis*. J Am Board Fam Pract, 1990; 3:289-91.
9. Reicher JJ, Mindelzun R: *Case report: Benign gastric ulcer erosion leading to a gastropericardial fistula in a patient with no known risk factors*. Clinical Imaging, 2014; 38:547-49.
10. Bruhl SR, Lanka K, Colyer Jr. WR: *Pneumopericardial tamponade resulting from a spontaneous gastropericardial fistula*. Catheter Cardiovasc Interv, 2009; 73, 5:666-68.