

Pathology of dysplasia and cancer in inflammatory bowel disease



Ann. Ital. Chir., 2011 82: 11-18

Claudia Mescoli, Mauro Frego*, Massimo Rugge

Dept. of Diagnostic Medical Sciences & Special Therapies; Surgical Pathology & Cytopathology Unit, University of Padua, Italy

*Dept. of Surgical & Gastroenterological Sciences "PG. Cèvese", University of Padua, Italy

Pathology of dysplasia and cancer in inflammation bowel disease

In both Crohn's disease and Ulcerative Colitis, Colorectal Cancer (CRC) secondary prevention basically relies on the histology detection of dysplasia. In Inflammatory Bowel Diseases (IBD) setting, dysplasia identifies the subgroup of patients eligible to a (more) strict surveillance program (or prophylactic colectomy). In the clinical practice, a number of issues might affect the benefit of the clinico-pathological surveillance of the IBD-dysplasia-patients: sampling errors, inconsistency in biopsy assessment, patients' drop-out, etc. Even in such a multifaceted context, evidence has been provided that surveillance of dysplasia is effective in reducing both CRC mortality and morbidity. This manuscript focuses on current issues concerning the histology assessment of the IBD-associated dysplastic lesions.

KEY WORDS: Colorectal cancer, Dysplasia, IBD

Colorectal cancer in IBD: incidence and risk factors

The first case of adenocarcinoma complicating ulcerative colitis was reported in 1925¹. The prevalence of colorectal cancer (CRC) in inflammatory bowel diseases (IBD) is approximately 4% and it slightly increases (5.4%) in patients with pancolitis; the overall incidence rate per year is approximately 3x1000 persons/year duration². The results of clinical studies vary, but recent figures suggest that the risk of colon cancer for patients with IBD increases by 0.5-1.0% yearly, 8-10 years after diagnosis³. Rutter and colleagues, in their long term follow-up of UC patients, assessed a cancer prevalence of 2.5%, 7.6%, and 10.8% after 20, 30, and 40 years, respectively⁴. According to the results of their meta-analysis, Eaden et al.² reported a cumulative probab-

ity of CRC of 2%, 8% and 18% at 10, 20 and 30 years, respectively. In IBD patients, the magnitude of CRC risk increases with: (1) duration of colitis; (2) young age of IBD presentation, (3) extent of colonic involvement; (4) severity of inflammation; (5) family history of CRC; and (6) association with primary sclerosing cholangitis.

Clinical features of colitis-associated CRC

Compared with sporadic colorectal carcinoma (s-CRC), colitis-associated colorectal cancer (Ca-CRC) has several distinguishing clinical features:

- Ca-CRC affects individuals younger than s-CRC;
- Ca-CRC progresses to invasive adenocarcinoma from flat (non-polypoid) dysplasia more frequently than s-CRC;
- in Ca-CRC, the proportion of mucinous/signet-ring cell histology is higher than in s-CRC;
- Ca-CRC has a higher rate of two (or more) synchronous cancers, which reflects an inflammatory-related cancer "field effect".

Finally, the sequence of molecular events leading from dysplasia to invasive carcinoma differs between s-CRC and Ca-CRC⁵.

Correspondence to: Massimo Rugge, M.D., F.A.C.G., Professor of Pathology, Dept. Medical Diagnostic Sciences & Special Therapies, Chair of the Surgical Pathology Unit, University of Padua, Italy, Istituto Oncologico Veneto-IRCCS, Via Aristide Gabelli 61, 35121 Padova, Italy (E-mail: massimo.rugge@unipd.it)

Molecular features of colitis-associated CRC

As in s-CRC, the neoplastic transformation arising in IBD is thought to be a multistep sequence. Many of the molecular alterations responsible for s-CRC development also play a role in colitis-associated colon carcinogenesis. As consistently demonstrated in s-CRC, also Ca-CRCs may develop through both chromosomal (CIN) and microsatellite instability (MSI) and the prevalence of the two pathways seems consistent with that observed in s-CRC (85% CIN, 15% MSI).

Distinguishing features, however, of Ca-CRC have been demonstrated in both the timing and the prevalence of the molecular deregulations. *APC* loss of function, which occurs early in s-CRC, is much less frequent (and usually late) in colitis-associated dysplasia-carcinoma sequence. Conversely, *p53* mutations, which occur late in sporadic oncogenesis, are earlier detected in IBD patients (even in non-dysplastic mucosa). Methylation is assuming an increasing importance in contributing to the genetic alterations in Ca-CRC. Methylation of CpG islands in several genes seems to precede dysplasia and is more widespread throughout the mucosa of UC patients^{5,6}.

Dysplasia as a basis for CRC secondary prevention in IBD

Dysplasia, as assessed by conventional histology, is the most reliable marker of cancer-prone IBD patients⁷⁻¹².

Dysplasia detection depends on several variables: a) frequency and technique of colonoscopy procedure, b) quality and quantity of the obtained biopsy samples; c) pathologist and endoscopist expertise; d) patient's compliance to follow-up¹³.

Dysplasia assessment: endoscopy-related issues (i.e. timing of endoscopy surveillance and optimum number of required biopsies). Surveillance colonoscopy relies on the ability to detect precancerous lesions (dysplasia), before full-blown cancer is unequivocally faced^{12,14-18}. The number of biopsy samples to be obtained for assessing/excluding dysplasia is controversial. In his seminal study, Rubin¹⁹ demonstrated that the probability of detecting dysplasia was 90% and 95% when 33 and 64 random biopsies were respectively obtained. After that, different proposals for CRC screening in IBD have been produced, all of them differing in both the number of biopsies should be obtained and the technique of the endoscopy biopsy sampling^{17,20-23}.

The Crohn's and Colitis Foundation of America states that a screening colonoscopy should begin 8 to 10 years after the onset of symptoms; subsequent surveillance colonoscopies should be performed every 1 to 2 years for UC patients with extensive colitis or left-sided colitis and a negative screening colonoscopy. They suggest that no less than 32 biopsies should be obtained at each surveillance colonoscopy (4-quadrant biopsies every 10 cm each quartet being submitted in a separate vial). Separate containers should be used for any non-flat or suspicious lesions (namely nodules, masses or strictures).

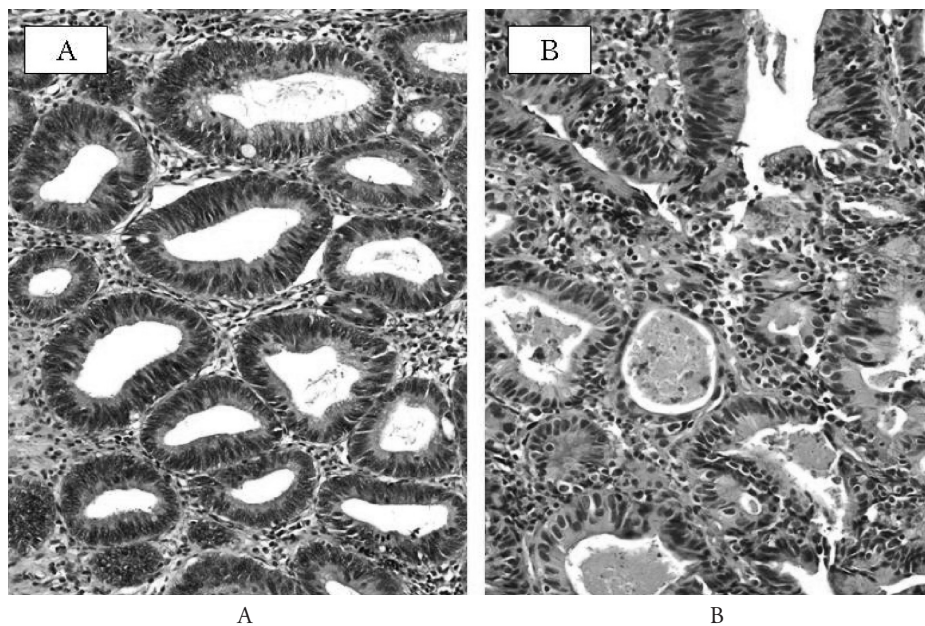


Fig. 1: A) Low-grade dysplasia in UC. The crypts are lined by columnar epithelium with crowded, hyperchromatic, elongated pencil-shaped nuclei. The nuclei are consistently basally located. B) High-grade dysplasia in UC. Crypts are irregular in shape and size and show back-to-back arrangement. The nuclei show severe atypia and loss of polarity; several mitotic figures are also present. Necrotic debris are present within the glandular lumens (Haematoxylin-Eosin, original magnification 200).

It has been additionally suggested that distal colon (“the elective” cancer-prone area) should be more extensively sampled (approximately every 5 cm)^{20,24}. The American College of Gastroenterology recommends annual or biannual surveillance colonoscopy with multiple biopsies after 8 to 10 years of colitis and states: “Although some data suggest a later onset of cancer risk in left-sided than in more extensive colitis²⁵, this evidence is not sufficiently strong to justify different guidelines for surveillance in the two groups”²¹. The British Society of Gastroenterology advocates an initial screening colonoscopy after 8 to 10 years of IBD symptoms but that surveillance intervals should vary based on extent of disease, duration of disease, and presence of PSC. They state that two to four random biopsy specimens every 10 cm should be taken from the entire colon with additional samples from suspicious areas such as raised lesions, irregular plaques, unusual ulcers, or strictures^{22,23}.

Questionnaire surveys, however, consistently demonstrated that -in routine practice- all the above-mentioned protocols are mostly unaccomplished^{26,27}. Obtaining random biopsies, however, is being increasingly criticized. Rutter²⁸ and Rubin²⁹, consistently demonstrated that, in UC patients, up to 73% to 77% of the dysplastic lesions and 89% to 100% of invasive cancers are endoscopically detectable. On the other hand, random biopsies visualize less than 0.05% of the total colonic mucosa surface area, which does result in a high sampling error when non-targeted biopsies samples are obtained from flat (dysplastic mucosa). Targeted biopsies may represent an alternative to randomly drilling mucosa. Newer imaging technologies such as chromoendoscopy, magnification endoscopy and confocal laser microscopy may potentially enhance detection of dysplasia, which could allow endoscopists to take fewer high-yield biopsies of targeted abnormal mucosa^{13,30}. All studies have confirmed an improved yield of surveillance colonoscopy by dye spraying (e.g. methylene blue or indigo carmine). When applied, random biopsies of apparently normal mucosa had no additional value compared to targeted biopsies obtained after dye staining of the mucosa³¹⁻³³.

Dysplasia assessment: pathology-related issues (i.e. inter-observer variation). The histology assessment of the biopsy specimens (wherever obtained) is determinant in the choice of patients’ management: ultimately, it is the pathologist’s interpretation that distinguishes high-risk from low-risk patients and he also triggers recommendations for either continued surveillance or colectomy. The histological spectrum of dysplasia is distinguished in three categories: negative for dysplasia, indefinite for dysplasia, and positive for dysplasia (distinguished in low-grade [LG-D] or high-grade [HG-D])⁹. Although this system remains widely employed, it has several well-recognized limitations, including its poor intra- and inter-observer variability (even among experts)^{9,34}. In both

prospective and retrospective studies, the inter-observer consistency in the histological assessment of dysplasia ranged between 42% to 72%³⁴⁻⁴⁰. In a more recent study, Lim et al⁴⁰ found that the kappa inter-observer coefficient between ten pairings of five GI-pathologists ranged from 0.06 (acceptable) to 0.39 (unacceptable). The best agreement obviously occurs when considering the two extremes of the histological spectrum of the lesions (no dysplasia *versus* HG-D); the poorest diagnostic consistency covers the distinction of indefinite for dysplasia *versus* LG-D, and LG-D *versus* HG-D^{5,24}. Based on this lack of concordance, the Crohn’s and Colitis Foundation of America consensus guidelines and the U.S. Multisociety Task Force strongly recommend that dysplasia, as assessed prior of any surgical treatment, has to be confirmed by a second experienced gastrointestinal pathologist^{20,41,42}.

Gross (endoscopy) features of dysplasia in IBD

A peculiar feature of IBD-dysplasia is its macroscopic variability⁴³. Grossly, dysplasia is distinguished as flat or elevated, depending on whether or not it corresponds to an endoscopically visible lesion^{28,44-48}. This distinction (while difficult) is important because it does result in different therapeutic strategies^{46,49}. Flat dysplasia is often found in random biopsy specimens obtained from unremarkable mucosa: as a consequence, its detection depends on how “aggressive” is the random sampling of the mucosa.

Dysplasia assessed in endoscopically elevated/visible lesions has been referred as DALMs (dysplasia associated lesion or mass)^{44,50}. DALM includes (endoscopically not amendable) single and/or multiple polyps, bumps, plaques, velvety patches or nodules^{44,51} and it can easily be camouflaged among the gross inflammatory abnormalities encountered in IBD (which makes their endoscopic detection a challenge even for experienced practitioners). More recently, the definition of adenoma-like lesion or mass (ALM) or adenoma-like dysplasia (ALD) has been proposed. ALM is applied to polypoid dysplasia without adjacent flat component, endoscopically indistinguishable from a sporadic (sessile or pedunculated) polyp^{52,53} and completely removable by endoscopy. Histology is not supportive in differentiating DALM *versus* ALM and this distinction basically lies on the endoscopy appearance⁵⁴. Separation of DALM from ALM is important, as the former requires colectomy, while the latter can be managed with polypectomy and endoscopic surveillance⁵⁵.

The clinical impact of DALM came from the high rates of synchronous cancers detected in DALM patients undergone colectomy^{44,51}. In 12 DALM-bearing colons, Blackstone et al reported 7 cancers (5/7 with mild or moderate dysplasia in the presurgical biopsies)⁴⁴. A subsequent compilation of results from ten surveillance pro-

grams reported 17 cancers among 40 colectomies performed because of a DALM⁵⁰. It was concluded that DALM is an indication for colectomy, irrespective of the grade of dysplasia in preoperative biopsies.

In contrast to DALMs, ALM can be safely managed by polypectomy with biopsies of the surrounding flat mucosa⁵⁶. A study from The Mount Sinai Hospital in New York reported that conservative management of 48 UC patients with a total 70 such polyps (3 of them with high-grade dysplasia) did not result in any adverse outcome during a mean follow-up period of 4.1 years⁵². Similar conclusions were achieved in a concurrent study⁵³, further confirmed upon longer follow-up⁵⁶.

It is important to realize that the burden of deciding whether a polyp qualifies as adenoma-like rests with the endoscopist. The differentiation of ALM, DALM and inflammatory polyps has now been tested endoscopically. The recent paper from Farraye *et al.* showed that even the expert gastroenterologists have difficulty in differentiating the above-mentioned categories⁵⁷.

Histology (microscopic features of dysplasia in IBD)

Dysplasia is synonym of intraepithelial or non-invasive neoplasia (unequivocal neoplastic epithelium confined to the basement membrane, with no invasion into the lamina propria)⁹. Dysplasia basically consists of two concurring alterations: disturbed architecture and cytological atypia^{9,58}. Theoretically, similar criteria should be consistently applied in the assessment of dysplasia of both sporadic polyps (adenomas) and in IBD setting. This is, however, only partially true; in fact, in grading dysplasia as part of a sporadic adenomas, the architectural criterion is largely prevalent, while both cytology and architecture are involved in the assessment and grading IBD-dysplastic lesions.

Regardless of the endoscopic appearance of a lesion (i.e. raised or flat), the histological criteria for reporting dysplasia in IBD are basically the same^{9,46,58}. The histological classification of dysplasia in IBD is based on Riddell *et al.*'s 1983 consensus report. In this seminal study, the Authors proposed classifying biopsy specimens into 5 categories: negative for dysplasia (which implies normal mucosa or mucosa with regenerative changes); indefinite for dysplasia; and positive for low-grade dysplasia (LG-D), high-grade dysplasia (HG-D), or invasive cancer⁹. Although they recommended a further subdivision of the indefinite category (probably negative, probably positive, unknown), many pathologists regard this as optional. It is generally believed that Ca-CRC occurs through a progression from normal mucosa, to LG-D, HG-D, and then finally to cancer⁵⁹. However, this classification in detecting and predicting CRC is not as reliable as one would expect, as LG-D can proceed to (or coexist with?) CRC without going through the HG-D phase.

Dysplasia is a combination of cytological (nuclear and cytoplasmic) and architectural abnormalities. The nuclear changes include hyperchromasia, nuclear pleomorphism (variability in the size/shape), prominent nucleoli, high nuclear-cytoplasmic ratio, crowding, stratification, and excessive and/or atypical mitoses. The cytoplasm is mostly basophilic and there is a reduction in (or absence of) goblet cell mucin, a feature similar to that seen in immature basal crypt epithelium. The maturation gradient of colocytes (typical of non-dysplastic crypts) is not featured by dysplastic epithelia, which are consistently monomorphic along the entire crypt axis. Architectural features include villiform surface and crypt budding, branching, and crowding (the latter commonly referred as a "back-to-back" growth pattern). The irregularity of the crypts' contour and the presence of intraluminal bridges ("cribriforming") are additional architectural features.

Negative for dysplasia. "Negative for dysplasia" applies to epithelium that is regenerative in nature. In the presence of active inflammation (cryptitis, crypt abscesses, or ulceration) epithelium can undergo impressive reactive changes that may mimic some of the "atypical" features of dysplasia. The presence of surface maturation is the most characteristic feature of non-dysplastic "regenerating" epithelium⁷.

Indefinite for dysplasia. In the setting of active inflammation/ulceration, regenerating epithelia may show atypia difficult to distinguish from true dysplasia: these features may be appropriately labelled as "indefinite for dysplasia". In the everyday diagnostic practice, this diagnostic category is most frequently applied when: a) technical issues (sectioning or staining) limit the interpretation of cytologic/architectural abnormalities; b) in cases of severe atypia coexisting with inflammation/ulceration; c) when dysplasia-like changes are only focal and/or restricted to in the crypt bases. The prevalence of indefinite for dysplasia lesions is basically proportional to the confidence that the pathologist has in dealing with IBD, and that's why it is generally recommended to confirm any potential diagnosis of dysplasia by the second opinion of an experienced IBD pathologist^{8,20}.

Low-grade dysplasia. In LG-D, crowded glands with minor size/shape abnormalities are basically similar to that seen in tubular adenomas. Dysplastic epithelium usually does not show surface maturation. Dysplastic cells have large cigar-shaped, basally orientated (i.e. limited to the basal half of the cell cytoplasm, without full thickness stratification) hyperchromatic nuclei. The cytoplasm is mucin-depleted and hyperosinophilic. Mitotic figures may be prominent, but atypical mitotic figures are usually few⁷.

High-grade dysplasia. In HG-D, both architectural disarrangement and cells atypia are prominent. Major architectural abnormalities of the glands (complex crypt budding, branching or a back-to-back growth pattern) are

usually present. Cystic change, villiform surface, and cribriforming can also be present. Cells consistently feature higher N/C, full-thickness nuclear stratification, loss of polarity, and nuclear pleomorphism. Mitoses are increased in number and often atypical (even at surface epithelium level). In some instances, high-grade nuclei are rounded, but nucleoli are always easy detectable and chromatin is "malignant" ^{60,61,62}.

Low-grade dysplasia versus high-grade dysplasia. Histology should assess dysplasia according to its most atypical component, but even detailed description do not prevent a significant inter-observer variability: even among GI pathologists, different perceptions of "cells atypia", "disturbed architecture", "cells differentiation" may result in inconsistent assessments. An adjunctive controversy regards the proportion of high-grade dysplastic crypts needed to upgrade a particular biopsy from low- to high-grade ^{9,43}. The IBD Dysplasia Morphology Study Group only suggests that a biopsy should not be considered high-grade "based solely on the presence of high-grade dysplasia in one or two crypts" ⁹, but how prevalent have to be the high-grade changes to promote a case from low- to high-grade is not established. Thus, the histological assessment of LG-D *versus* HG-D still remains largely subjective. As a consequence, the prognostic significance of the extent of dysplasia, both low- and high-grade, are unknown ⁷.

Intramucosal & invasive adenocarcinoma. Carcinoma is defined by true spreading of neoplastic cells beyond the basal membrane of the dysplastic crypts. Cancer cells invading the lamina propria or the *muscularis mucosa* are both defined as "intramucosal carcinoma"; in "submucosal carcinoma", cancer cells are unequivocally detected in the submucosal layer. The foci of early invasive adenocarcinoma often consist of small glands, single neoplastic clusters or isolated cancer cells. Infiltrating glands are variable in size and shape and may show intraluminal necrosis; peri-glandular desmoplasia is considered a reliable feature of invasive cancer and it is usually associated (at least) with submucosal extension ⁷.

Dysplasia as cancer predictor

In 1949, Warren and Sommers first suggested that UC-associated dysplasia was a cancer precursor ⁶³. Since then, growing evidence has unequivocally demonstrated that dysplasia is not only a precursor, but also a marker for co-existing CRC ⁶⁴. Carcinogenesis in IBD does not always follow a sequential progression from LG-D to HG-D, and eventually to cancer ²⁴. Ullman et al ⁶⁵ produced evidence that cancer can arise in patients with no prior dysplasia, or without first progressing from LGD to HGD. CRC arising in IBD is often multifocal and more aggressive than the sporadic variant ^{43,66,67}. Of course, in IBD patents sporadic non-IBD-related-cancer may occur coincidentally ^{46,58}.

Flat low-grade dysplasia. A number of studies refers that 16-54% of flat LG-D progress into more advanced lesions (either HGD or CRC) during a 5-year follow-up ^{4,37,65,68-71}. Among patients who underwent urgent colectomy for flat LG-D, the prevalence of coexisting HG-D/CRC has been found in 16%-34% of the surgical specimens; additionally, patients undergoing colectomy for flat LG-D were found to have much more advanced pathology on surgical specimens ^{4,50,65,72}. In the most recent meta-analysis, flat LG-D was found to be associated with a 9-fold increased risk of developing CRC (OR: 9.0, 95% CI: 4.0-20.5) and a 12-fold risk of developing advanced neoplasia (HDG or CRC) (OR: 11.9, 95% CI: 5.2-27) compared to no dysplasia. The positive predictive value of CRC for patients with flat LG-D was 22% ⁷³. It is also worth noting that in one study, unifocal LG-D was as likely to progress to HG-D or cancer as was multifocal LG-D ⁶⁵.

Flat high-grade dysplasia. In systematic reviews, 42% to 67% of patients undergone immediate surgery for flat HG-D were found to have CRC on colectomy specimens ^{4,50,74}. In Bernstein's experience, 32% of patients found to have flat HG-D after the initial colonoscopy developed cancer ⁵⁰.

Raised dysplasia. In Bernstein et al.'s review of ten prospective studies, 43% of patients who had colectomy for DALM had coexisting CRC (regardless of the grade of dysplasia in the DALM) ⁵⁰. Others have reported rates of coexisting CRC of 31% and 65% in the presence of DALMs ^{4,74}.

Indefinite for dysplasia. The clinico-pathological behaviour of "indefinite for dysplasia" lesions is poorly studied. In his review, Bernstein found that 28% of these cases progressed to HG-D and 9% to cancer ⁵⁰. Among 56 patients with "indefinite" lesions and followed up for 5 years, 9% progressed to HG-D or to CRC; the progression rate was intermediate between patients with no dysplasia and those with LG-D ⁷⁵.

No dysplasia. IBD patients with no dysplasia have the lowest rates of cancer progression. In Bernstein's review, these subjects showed a risk of developing HG-D or cancer lesser than 2.5% ⁵⁰. Among 311 non dysplastic UC patients followed up for 5 years, Ullman et al. reported a 1.1% incidence of colorectal ⁷⁵. Lim et al. showed that 4% of UC patients with no dysplasia developed HG-D or CRC after 10 years of follow-up ⁴⁰.

Occurrence and location of CRC-associated dysplasia

More than 90% of cancers arising in IBD coexist with dysplasia ^{72,76,77}, which is mostly found adjacent to carcinomas. Dysplasia may be also located distant from the invasive adenocarcinoma ^{76,78} and it may be isolated or multifocal (rarely diffuse) ^{72,76,77}.

Distant dysplasia may occur in any portion of the colon in IBD, but often parallels the same colonic segment of cancer ^{72,76-78}.

Riassunto

La prevenzione secondaria del Carcinoma Colo-Rettale (CRC) associato a Malattia Infiammatoria Cronica Intestinale si basa sull'identificazione istologica della displasia la quale, rappresentando il marcatore di un aumentato rischio di sviluppo neoplastico, identifica un sottogruppo di pazienti candidati ad un più stretto programma di sorveglianza. Nella pratica clinica, diversi fattori possono influenzare e condizionare il beneficio di tale sorveglianza interferendo con l'identificazione della displasia, in modo particolare errori di campionamento, durante la fase endoscopica, valutazione istologica inadeguata e scarsa aderenza del paziente al programma stesso. Ciò nonostante l'applicazione di protocolli per la sorveglianza endoscopico-biottica della displasia si è dimostrata efficace nel ridurre morbidità e mortalità dei pazienti con CRC associato ad IBD. Questo manoscritto tratta gli aspetti legati all'identificazione e valutazione istologica delle lesioni displastiche IBD-associate.

References

- 1) Crohn B, Rosenberg H: *The sigmoidoscopic picture of chronic ulcerative colitis (non-specific)*. Am J Med Sci, 1925; 170:220-28.
- 2) Eaden JA, Abrams KR, Mayberry JF: *The risk of colorectal cancer in ulcerative colitis: A meta-analysis*. Gut, 2001; 48:526-35.
- 3) Munkholm P: *Review article: the incidence and prevalence of colorectal cancer in inflammatory bowel disease*. Aliment Pharmacol Ther, 2003; 18 Suppl 2:1-5.
- 4) Rutter MD, Saunders BP, Wilkinson KH, et al: *A Thirty-year analysis of a colonoscopic surveillance program for neoplasia in ulcerative colitis*. Gastroenterology, 2006; 130:1030-8.
- 5) Xie J, Itzkowitz SH: *Cancer in inflammatory bowel disease*. World J Gastroenterol, 2008; 14:378-89.
- 6) Issa JP, Ahuja N, Toyota M, et al: *Accelerated age-related CpG island methylation in ulcerative colitis*. Cancer Res, 2001; 61:3573-7.
- 7) Odze RD: *Pathology of dysplasia and cancer in inflammatory bowel disease*. Gastroenterol Clin North Am, 2006; 35:533-52.
- 8) Ullman TA. *Dysplasia and colorectal cancer in Crohn's disease*. J Clin Gastroenterol, 2003; 36:S75-78.
- 9) Riddell RH, Goldman H, Ransohoff DF, et al: *Dysplasia in inflammatory bowel disease: Standardized classification with provisional clinical applications*. Hum Pathol, 1983; 14:931-68.
- 10) Judge TA, Lewis JD, Lichtenstein GR: *Colonic dysplasia and cancer in inflammatory bowel disease*. Gastrointest Endosc Clin N Am, 2002; 12:495-23.
- 11) Collins PD, Mpofu C, Watson AJ, et al: *Strategies for detecting colon cancer and/or dysplasia in patients with inflammatory bowel disease*. Cochrane Database Syst Rev, 2006; CD000279.
- 112) Harpaz N: *Neoplastic precursor lesions related to the development of cancer in inflammatory bowel disease*. Gastroenterol Clin North Am, 2007; 36:901-26.
- 13) Zisman TL, Rubin DT: *Colorectal cancer and dysplasia in inflammatory bowel disease*. World J Gastroenterol, 2008; 14:2662-669.
- 14) Lakatos PL, Lakatos L: *Risk for colorectal cancer in ulcerative colitis: Changes, causes and management strategies*. World J Gastroenterol, 2008; 14:3937-647.
- 15) Ullman T, Odze R, Farraye FA: *Diagnosis and management of dysplasia in patients with ulcerative colitis and Crohn's disease of the colon*. Inflamm Bowel Dis, 2009; 15:630-38.
- 16) Itzkowitz SH: *Cancer prevention in patients with inflammatory bowel disease*. Gastroenterol Clin North Am, 2002; 31:1133-144.
- 17) Rubin DT, Kavitt RT: *Surveillance for cancer and dysplasia in inflammatory bowel disease*. Gastroenterol Clin North Am, 2006; 35:581-604.
- 18) Mitchell PJ, Salmo E, Haboubi NY: *Inflammatory bowel disease: The problems of dysplasia and surveillance*. Tech Coloproctol, 2007; 11:299-309.
- 19) Rubin CE, Haggitt RC, Burmer GC, et al: *DNA aneuploidy in colonic biopsies predicts future development of dysplasia in ulcerative colitis*. Gastroenterology, 1992; 103:1611-20.
- 20) Itzkowitz SH, Present DH, Odze RD, et al: *Crohn's and Colitis Foundation of America Colon Cancer in IBD Study Group. Consensus conference: Colorectal cancer screening and surveillance in inflammatory bowel disease*. Inflamm Bowel Dis, 2005; 11:314-21.
- 21) Kornbluth A, Sachar DB: *Ulcerative colitis practice guidelines in adults (update): American College of Gastroenterology, Practice Parameters Committee*. Am J Gastroenterol, 2004; 99:1371-385.
- 22) Carter MJ, Lobo AJ, Travis SP: *Guidelines for the management of inflammatory bowel disease in adults*. Gut, 2004; 53(Suppl 5):V1-V16.
- 23) Eaden JA, Mayberry JF: *Guidelines for the screening and surveillance of asymptomatic colorectal cancer in patients with inflammatory bowel disease*. Gut, 2002; 51:10-12.
- 24) Itzkowitz SH, Harpaz N: *Diagnosis and management of dysplasia in patients with inflammatory bowel diseases*. Gastroenterology 2004; 126:1634-1648.
- 25) Greenstein AJ, Sachar DB, Smith H, et al: *Cancer in universal and left-sided ulcerative colitis: Factors determining risk*. Gastroenterology, 1979; 77:290-94.
- 26) Bernstein CN, Weinstein WM, Levine DS, et al: *Physicians' perceptions of dysplasia and approaches to surveillance colonoscopy in ulcerative colitis*. Am J Gastroenterol, 1995; 90:2106-114.
- 27) Eaden JA, Ward BA, Mayberry JF: *How gastroenterologists screen for colonic cancer in ulcerative colitis: An analysis of performance*. Gastrointest Endosc, 2000; 51:123-28.
- 28) Rutter MD, Saunders BP, Wilkinson KH, et al: *Most dysplasia in ulcerative colitis is visible at colonoscopy*. Gastrointest Endosc, 2004; 60:334-39.
- 29) Rubin DT, Rothe JA, Hetzel JT, et al: *Are dysplasia and colorectal cancer endoscopically visible in patients with ulcerative colitis?* Gastrointest Endosc, 2007; 65:998-1004.
- 30) Marion JF, Wayne JD, Present DH, et al: *Chromoendoscopy-targeted biopsies are superior to standard colonoscopic surveillance for detecting dysplasia in inflammatory bowel disease patients: A prospective endoscopic trial*. Am J Gastroenterol, 2008; 103:2342-349.

- 31) Rutter MD, Saunders BP, Wilkinson KH, et al: *Cancer surveillance in longstanding ulcerative colitis: endoscopic appearances help predict cancer risk*. Gut, 2004; 53:1813-816.
- 32) Kiesslich R, Fritsch J, Holtmann M, et al: *Methylene blue-aided chromoendoscopy for the detection of intraepithelial neoplasia and colon cancer in ulcerative colitis*. Gastroenterology, 2003; 124:880-88.
- 33) Hurlstone DP, Sanders DS, Lobo AJ, et al: *Indigo carmine-assisted high-magnification chromoscopic colonoscopy for the detection and characterisation of intraepithelial neoplasia in ulcerative colitis: A prospective evaluation*. Endoscopy, 2005; 37:1186-192.
- 34) Odze RD, Goldblum J, Noffsinger A, et al: *Interobserver variability in the diagnosis of ulcerative colitis-associated dysplasia by telepathology*. Mod Pathol, 2002; 15:379-86.
- 35) Eaden J, Abrams K, McKay H, et al: *Inter-observer variation between general and specialist gastrointestinal pathologists when grading dysplasia in ulcerative colitis*. J Pathol, 2001; 194:152-7.
- 36) Dixon MF, Brown LJ, Gilmour HM, et al: *Observer variation in the assessment of dysplasia in ulcerative colitis*. Histopathology, 1988; 13:385-97.
- 37) Connell WR, Lennard-Jones JE, Williams CB, et al: *Factors affecting the outcome of endoscopic surveillance for cancer in ulcerative colitis*. Gastroenterology, 1994; 107:934-44.
- 38) Riddell RH: *Grading of dysplasia*. Eur J Cancer, 1995; 31A:1169-170.
- 39) Melville DM, Jass JR, Morson BC, et al: *Observer study of the grading of dysplasia in ulcerative colitis: Comparison with clinical outcome*. Hum Pathol, 1989; 20:1008-14.
- 40) Lim CH, Dixon MF, Vail A, et al: *Ten year follow up of ulcerative colitis patients with and without low grade dysplasia*. Gut, 2003; 52:1127-132.
- 41) Greenson JK: *Dysplasia in inflammatory bowel disease*. Semin Diagn Pathol, 2002; 19:31-37.
- 42) Winawer S, Fletcher R, Rex D, et al: *Colorectal cancer screening and surveillance: Clinical guidelines and rationale-Update based on new evidence*. Gastroenterology, 2003; 124:544-60.
- 43) Harpaz N, Talbot IC: *Colorectal cancer in idiopathic inflammatory bowel disease*. Semin Diagn Pathol, 1996; 13:339-57.
- 44) Blackstone MO, Riddell RH, Rogers BGH, et al: *Dysplasia-associated lesion or mass (DALM) detected by colonoscopy in long-standing ulcerative colitis: An indication for colectomy*. Gastroenterology, 1981; 80:366-74.
- 45) Itzkowitz S, Ullman T: *The world isn't flat*. Gastro Endoscop, 2004; 60:426-27.
- 46) Odze RD: *Adenomas and adenoma-like DALMs in chronic ulcerative colitis: A clinical, pathological, and molecular review*. Am J Gastroenterol, 1999; 94:1746-50.
- 47) Rutter M, Bernstein C, Matsumoto T, et al: *Endoscopic appearance of dysplasia in ulcerative colitis and the role of staining*. Endoscopy, 2004; 36:1109-14.
- 48) Ahmadi A, Polyak S, Draganov PV: *Colorectal cancer surveillance in inflammatory bowel disease: The search continues*. World J Gastroenterol, 2009; 15:61-66.
- 49) Odze RD: *Recent advances in inflammatory bowel disease*. Mod Pathol, 2003; 16:347-58.
- 50) Bernstein CN, Shanahan F, Weinstein WM: *Are we telling patients the truth about surveillance colonoscopy in ulcerative colitis?* Lancet, 1994; 343:71-4.
- 51) Butt JH, Konishi F, Morson DM, et al: *Macroscopic lesions in dysplasia in carcinoma complicating ulcerative colitis*. Dig Dis Sci, 1983; 28:18-26.
- 52) Rubin PH, Friedman S, Harpaz N, et al: *Colonoscopic polypectomy in chronic colitis: Conservative management after endoscopic resection of dysplastic polyps*. Gastroenterology, 1999; 117:1295-300.
- 53) Englesjerd M, Farraye FA, Odze RD: *Polypectomy may be adequate treatment for adenoma-like dysplastic lesions in chronic ulcerative colitis*. Gastroenterology, 1999; 117:1288-294.
- 54) Schneider A, Stolte M: *Differential diagnosis of adenomas and dysplastic lesions in patients with ulcerative colitis*. Z Gastroenterol, 1993; 31:653-56.
- 55) Ludeman L, Shephard NA: *Problem areas in the pathology of chronic inflammatory bowel disease*. Curr Diagn Pathol, 2006; 12:248-60.
- 56) Odze RD, Farraye FA, Hecht JL, et al: *Longterm follow-up after polypectomy treatment for adenoma-like dysplastic lesions in ulcerative colitis*. Clin Gastroenterol Hepatol, 2004; 2:534-41.
- 57) Farraye FA, Wayne JD, Moscandrew M, et al: *Variability in the diagnosis and management of adenoma-like and non-adenoma-like dysplasia-associated lesions or masses in inflammatory bowel disease: An Internetbased study*. Gastrointest Endosc, 2007; 66:519-29.
- 58) Torres C, Antonioli D, Odze RD, et al: *Polypoid dysplasia and adenomas in inflammatory bowel disease*. Am J Surg Pathol, 1998; 22:275-84.
- 59) Itzkowitz SH, Yio X: *Inflammation and cancer. Colorectal cancer in inflammatory bowel disease: The role of inflammation*. Am J Physiol Gastrointest Liver Physiol, 2004; 287:G7-G17.
- 60) Rubio CA, Johansson P, Slezak U, et al: *Villous dysplasia. An ominous histologic sign in colitic patients*. Dis Colon Rectum, 1984; 27:283-87.
- 61) Anderson SN, Lovig T, Clausen OPF, et al: *Villous, hypermucinous mucosa in long standing ulcerative colitis shows high frequency of K-ras mutation*. Gut, 1999; 45:686-92.
- 62) Rubio CA, Befrits R, Jaramillo E, et al: *Villous and serrated adenomatous growth bordering carcinomas in inflammatory bowel disease*. Anticancer Res, 2000; 20:4761-2.
- 63) Warren S, Sommers SC: *Pathogenesis of ulcerative colitis*. Am J Pathol, 1949; 25:657-79.
- 64) Bernstein CN: *Natural history and management of flat and polypoid dysplasia in inflammatory bowel disease*. Gastroenterol Clin North Am, 2006; 35:573-79.
- 65) Ullman T, Croog V, Harpaz N, et al: *Progression of flat low-grade dysplasia to advanced neoplasia in patients with ulcerative colitis*. Gastroenterology, 2003; 125:1311-319.
- 66) Greenstein AJ, Slater G, Heimann TM, et al: *A comparison of multiple synchronous colorectal cancer in ulcerative colitis, familial polyposis coli, and de novo cancer*. Ann Surg, 1986; 203:123-28.
- 67) Delaunoit T, Limburg PJ, Goldberg RM, et al: *Colorectal cancer prognosis among patients with inflammatory bowel disease*. Clin Gastroenterol Hepatol, 2006; 4:335-42.

- 68) Ullman T, Odze R, Farraye FA: *Diagnosis and management of dysplasia in patients with ulcerative colitis and Crohn's disease of the colon*. *Inflamm Bowel Dis*, 2009; 15:630-38.
- 69) Linberg B, Perrson B, Veress B, et al: *Twenty years' colonoscopic surveillance of patients with ulcerative colitis. Detection of dysplastic and malignant transformation*. *Scand J Gastroenterol*, 1996; 31:1195-204.
- 70) Eaden J: *Review article: colorectal carcinoma and inflammatory bowel disease*. *Aliment Pharmacol Ther*, 2004; 20 Suppl 4:24-30.
- 71) Ullman TA, Loftus EV Jr, Kakar S, et al: *The fate of low grade dysplasia in ulcerative colitis*. *Am J Gastroenterol*, 2002; 97:922-927.
- 72) Taylor BA, Pemberton JH, Carpenter HA, et al: *Dysplasia in chronic ulcerative colitis: Implications for colonoscopic surveillance*. *Dis Colon Rectum*, 1992; 32:950-6.
- 73) Thomas T, Abrams KA, Robinson RJ, et al: *Meta-analysis: Cancer risk of low-grade dysplasia in chronic ulcerative colitis*. *Aliment Pharmacol Ther*, 2007; 25:657-68.
- 74) Collins RH, Feldman M, Fordman JS: *Colon cancer, dysplasia, and surveillance in patients with ulcerative colitis: A critical review*. *N Engl J Med*, 1987; 316:1654-58.
- 75) Ullman TA, Croog V, Harpaz N, et al : *Progression to colorectal neoplasia in ulcerative colitis: Effect of 5-aminosalicylic acid*. *Clin Gastroenterol Hepatol*, 2008; 6:1225-230.
- 76) Friedman S, Rubin PH, Bodian C, et al: *Screening and surveillance colonoscopy in chronic Crohn's colitis*. *Gastroenterology*, 2001; 120:820-26.
- 77) Webb BW, Petras RE, Bozdech JM, et al: *Carcinoma and dysplasia in mucosal ulcerative colitis: A clinicopathologic study of 44 patients*. *Am J Clin Pathol*, 1991; 96:403-7.
- 78) Connell WR, Talbot IC, Harpaz N, et al : *Clinicopathological characteristics of colorectal carcinoma complicating ulcerative colitis*. *Gut*, 1994; 35:1419-23.