



# Osteosarcoma-like divergent differentiation in sarcomatoid renal cell tumor

A rare entity whose diagnosis may be difficult



Ann. Ital. Chir.

Published online (EP) 23 April 2013

pii: S2239253X13021051

[www.annitalchir.com](http://www.annitalchir.com)

Francesco Ziglioli, Paolo Del Rio\*, Francesco Dinale, Matteo Ciuffreda, Umberto Maestroni

Department of Surgery, Unit of Urology, University-Hospital of Parma, Italy

\*Department of Surgery, Unit of General Surgery and Organ Transplantation, University-Hospital of Parma, Italy

**Osteosarcoma-like divergent differentiation in sarcomatoid renal cell tumor. A rare entity whose diagnosis may be difficult**

*A sarcomatoid component can occur in all histologic subtypes of renal cell carcinoma (RCC) and indicates an aggressive tumor. It is reported in literature that the sarcomatoid component can resemble fibrosarcoma, malignant fibrous histiocytoma or rhabdomyosarcoma. We describe the case of a 59-years old patient diagnosed with a chromophobe renal cell carcinoma, presenting a very rare osteosarcoma-like differentiation of the sarcomatoid component. The differential diagnosis with retroperitoneal calcifying masses is also discussed.*

KEY WORDS: Sarcomatoid RCC, Renal carcinoma, Osteosarcoma

## Introduction

Renal Cell Carcinomas (RCCs) are a group of solid renal tumors that represents about 3% of all the malignancies in adult. Sarcomatoid Renal Cell Carcinoma is a histological variant of RCC. Since its first description, the sarcomatoid renal cell carcinoma has been considered to have a poor prognosis, independent of the primary histologic feature.

We present the case of a woman diagnosed with Chromophobe RCC who developed dedifferentiation accompanied by osteosarcoma-like divergent differentiation, a very rare entity, not described in the largest series

of sarcomatoid RCCs reported in the literature.

We also discuss the clinical outcome and the most important aspects of the differential diagnosis with other retroperitoneal calcifying tumors.

## Case report

A 59-year-old woman was admitted to our department with weakness, acute left flank pain and anemia. The anamnesis was unremarkable. On palpation, a mass located in left abdominal size was identified. At ultrasonography, a 8 x 7 x 7 cm left renal mass was detected. A thoracic and abdominal CT scan was performed (Fig. 1), that demonstrated a tumoral mass (9 x 7,5 x 7) in the upper pole of the left kidney, with involvement of the adrenal gland, of the left lobe of the liver, and of the lumbar-aortic lymph nodes. The tumour was hypervascular and characterized by a nonhomogeneous pattern with several areas with either calcification or ossification. The presence of sub-pleural and diaphragmatic metastatic lesions (smaller than 1 cm) was also found. A complete bone scan did not report any involvement of bone

*Pervenuto in Redazione Dicembre 2012. Accettato per la pubblicazione Febbraio 2013*

*Correspondence to: Francesco Ziglioli, Department of Surgery, Unit of Urology, University-Hospital of Parma, Via Gramsci 14, 43126 Parma, Italy (e-mail: [ziglioli@hotmail.it](mailto:ziglioli@hotmail.it))*

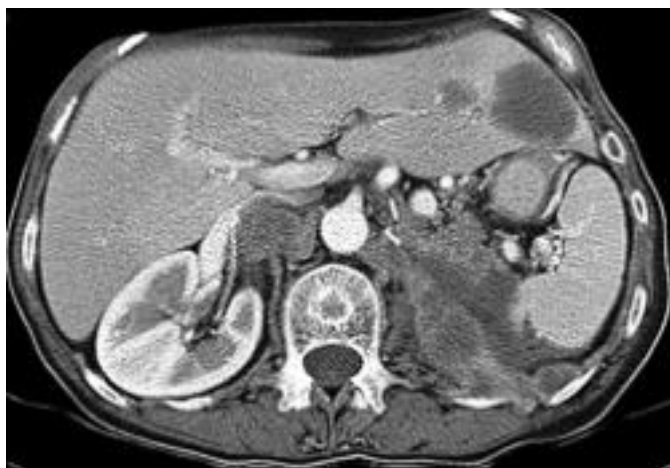

Fig. 1: Pre-operative CT scan.

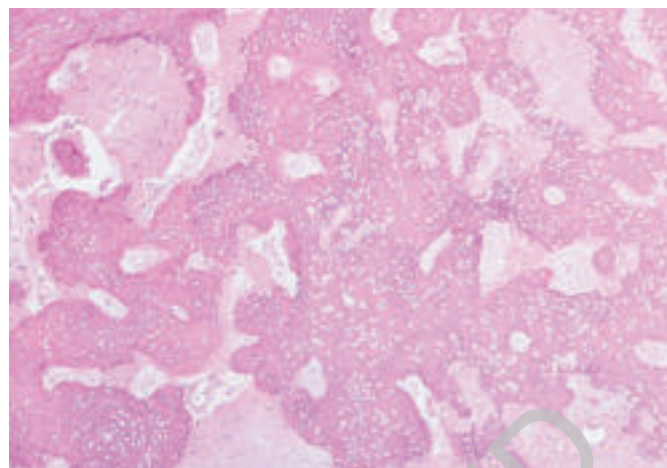


Fig. 4: Diffuse interstitial osteo-sarcomatoid deposition.

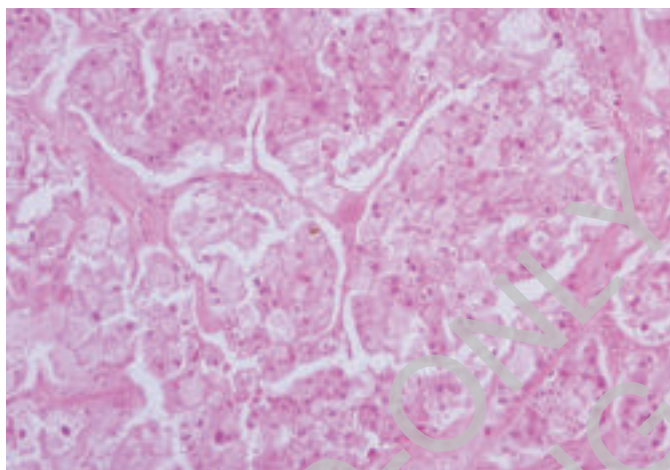


Fig. 2: Areas of classic chromophobe renal cell carcinoma.

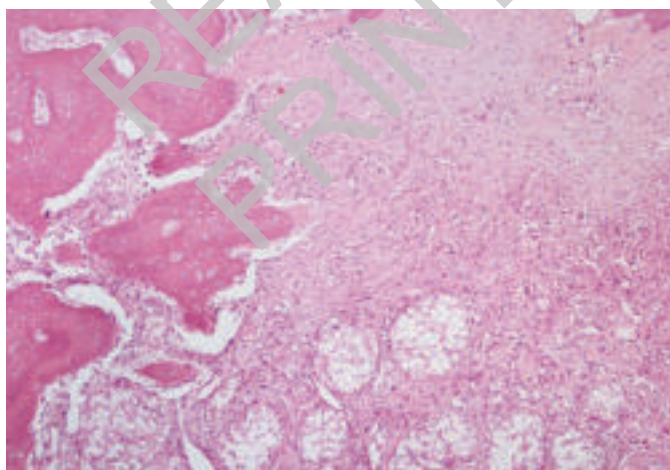


Fig. 3: Areas of classic chromophobe renal cell carcinoma together with areas of osteosarcoma-like divergent differentiation.

tissue. The patient underwent left radical nephrectomy and adrenalectomy; iliac and lateroaortic lymph nodes dissection was also performed. The surgical mass measured cm 14 x 6 x 5 and the kidney was considerably deformed by the massive tumor (9,5 x 7,5 x 7 cm). Macroscopically, the mass appeared gray and whitish, with large vessels, no clear margins and presented areas of calcified consistency. Post-operative time was uneventful and the patient was discharged on day 7 after surgery. Histologically, about 30% of the neoplasm was composed of a classic chromophobe renal cell carcinoma with polygonal cells with eosinophilic cytoplasm, prominent cell membranes and nucleolated nuclei (Fig. 3). The chromophobe zone turned into high-grade sarcomatoid neoplasm with diffuse interstitial osteoid deposition (Fig. 4). At immunohistochemistry, these areas showed vimentin, EMA and cytokeratin pool staining. The histopathologic diagnosis was sarcomatoid renal cell carcinoma with osteosarcoma-like divergent differentiation. In the following months, the patient underwent chemotherapy. She died 7 months after as a consequence of the disseminated disease.

## Discussion

Chromophobe renal cell carcinoma was first described by Thoenes et al in 1985. It is an uncommon subtype with distinct histologic, histochemical, ultrastructural and genetic characteristics<sup>1,2</sup>. Its histopathologic features are compact architecture, prominent cytoplasmic membranes and pale flocculent cytoplasm, perinuclear halos and binucleation. The cytoplasm is positive for Hale's colloidal iron stain. Immunohistochemically, tumor cells are negative for vimentin, although clear cell type RCC is usually positive. Cytoplasmic microvesicles are observed in electron microscopy.

Sarcomatoid renal cell carcinoma is not a distinct histologic entity and represents high-grade transformation in different subtypes of renal cell carcinoma. In a series of 101 sarcomatoid RCC, de Peralta-Venturina and colleagues found that the chromophobe renal carcinoma had a incidence rate of 9%<sup>3</sup>. The higher incidence of chromophobe renal cell carcinoma with sarcomatoid transformation is reported by Akhtar et al in a study carried out in Saudi Arabia<sup>4</sup>, but it may be the result of a geographic predilection of the chromophobe renal cell carcinoma in that region.

However, the sarcomatoid renal tumor is highly aggressive and the primary histologic feature does not influence the prognosis, as already reported also by Ro et al and Mian et al.<sup>3,7,8,10</sup>. This implies that the sarcomatoid transformation is a phenomenon prognostically more critical than the primary histologic subtype of renal cell carcinoma<sup>3</sup>.

In the same series, de Peralta-Venturina and colleagues found that the sarcomatoid transformation with divergent differentiation could be fibrosarcoma-like (54%), malignant fibrous histiocytoma-like (43%), rhabdomyosarcoma-like (2%), or undifferentiated (1%). No cases showed osteosarcoma-like divergent differentiation. This divergent differentiation is very very uncommon and only two cases are reported in literature to our knowledge<sup>5,6</sup>.

Yung et al. reported a case of sarcomatoid change with osteogenic differentiation in benign oncocytoma [9]; interestingly, however, osteosarcoma-like differentiation in chromophobe renal cell carcinoma remains extremely rare.

In the de-Peralta-Venturina series the disease-specific survival rate was 59% after 1 year and only 22% after 5 years, while in RCC without sarcomatoid differentiation is reported to be 79%<sup>3</sup>. This percentage demonstrates the rapid growth and the very poor prognosis of this tumor and the surgeon must also consider the metastatic potential of this disease. Unfortunately, it remains unknown whether and how the presence of the osteosarcoma-like differentiation affects the prognosis compared to other sarcomatoid tumors, because of the rarity of this phenomenon.

In addition, the rarity of this phenomenon must lead to consider the pathological differential diagnosis with other entities, such as retroperitoneal neoplasm with osteosarcomatous phenotype originating from the kidney or secondarily involving the kidney (both very rare). Although the differential diagnosis between these tumors and the osteosarcoma-like divergent renal carcinoma can be difficult, we argue that the clinical diagnosis can be corroborated by X-Ray and CT scan showing a variable level of mineralization, with cloud-like areas of opacity on CT. At the same time, we maintain that the contemporaneous presence of a *chromophobe* renal cell carcinoma can encourage the diagnosis of osteosarcoma-like divergent RCC.

Moreover, it is important to consider that some retroperitoneal non-sarcomatous tumors may contain calcifications (e. g. mature teratomas, immature teratomas): they also have to be considered within radiological differential diagnosis.

Another pathology has to be considered by the clinician, the myositis ossificans, a benign pathology characterized by deposition of bone into intra-abdominal soft tissue, whose diagnosis is definitively provided by biopsy.

In summary, we describe a case of chromophobe renal cell carcinoma showing osteosarcoma-like differentiation with an aggressive clinical course. Moreover, we deal with the main difficulties that the clinician has to face in order to provide a correct diagnosis.

### RIASSUNTO

La componente sarcomatoide può essere presente in tutti i sottotipi istologici del carcinoma a cellule renali (RCC) e indica un tumore aggressivo. È riportato in letteratura che la componente sarcomatoide può mimare fibrosarcoma, istiocitoma fibroso maligno, rhabdomyosarcoma. Noi descriviamo il caso di un paziente di 59 anni che presentava una rara forma di differenziazione simil osteosarcoma della forma sarcomatoide.

La diagnosi differenziale con le masse calcifiche retroperitoneali viene discussa.

### References

1. Thoenes W, Storkel S, Rumpelt HJ: *Human chromophobe cell renal carcinoma*. Virchows Arch B Cell Pathol Mol Pathol, 1985; 48:207-17.
2. Kuroda N, Toi M, Hiroi M, et al: *Review of chromophobe renal cell carcinoma with focus on clinical and pathological aspects*. Histol Histopathol, 2003; 18:165-71.
3. De Peralta-Venturina M, Moch H, Amin M, et al: *Sarcomatoid differentiation in renal cell carcinoma. A study of 101 cases*. Am J Surg Pathol, 2001; 25:275-84.
4. Akhtar M, Tulbah A, Kardar AH et al: *Sarcomatoid renal cell carcinoma: the chromophobe connection*. Am J Surg Pathol, 1997; 21:1188-95.
5. Itoh T, Chikai K, Ota S, et al: *Chromophobe renal cell carcinoma with osteosarcoma-like differentiation*. Am J Surg Pathol, 2002; 26:1358-62.
6. Gira FA, Barbieri A, Fellegara G, et al: *Dedifferentiated Chromophobe renal cell carcinoma with massive osteosarcoma-like divergent differentiation: A singular entity in the spectrum of retroperitoneal calcifying tumors*. Int J Surg Pathol, 2009; 20:1-5.
7. Ro JY, Ayala AG, Sella A, et al: *Sarcomatoid renal cell carcinoma: clinicopathologic*. A study of 42 cases. Cancer, 1987; 59:516-26.
8. Mian BM, Bhadkamkar N, Slaton JW, et al: *Prognostic factors and survival of patients with sarcomatoid renal cell carcinoma*. J Urol, 2002; 167:65-70.

9. Yung RH, Dunn J, Dickersin GR: *An unusual oncocytic renal tumor with sarcomatoid foci and osteogenic differentiation*. Arch Pathol Lab Med, 1988; 112:937-40.
10. Nelson EC, Evans CP, Lara PN Jr: *Renal cell carcinoma: current status and emerging therapies*. Cancer Treat Rev, 2007; 33:299-313.

READ-ONLY COPY  
PRINTING PROHIBITED