



# Incarcerated Amyand's hernia

## Personal experience and literature review



Ann. Ital. Chir.  
Published online (EP) 4 May 2015  
pii: S2239253X15023798  
[www.annitalchir.com](http://www.annitalchir.com)

Paolo Caiazzo\*, Pierpaolo Di Lascio\*, Alessandro Crocoli\*\*, Antonio Zaccara\*\*,  
Maria Esposito\*\*\*, Massimo Rivosecchi\*\*

\*UOC Chirurgia d'Urgenza, AOR "S. Carlo", Potenza, Italy

\*\*Centro Peridatrico Bambin Gesù Basilicata, AOR "S. Carlo", Potenza, Italy

\*\*\*UOC Chirurgia Pediatrica, Seconda Università degli Studi di Napoli, Italy

### Incarcerated Amyand's hernia. Personal experience and literature review

*The finding of vermiform appendix in an inguinal hernia is called Amyand's hernia. Two cases of a 30 days and 4 months old children respectively are presented; they had been visited a month earlier and scheduled for inguinal herniotomy in elective surgery.*

*On admission both the patients presented a non-reducible mass in the right inguinal region. Surgical exploration was performed under general anaesthesia. Inguinal canal is opened through transverse lower abdominal skin incision. We palpated a tubular swelling, of tense-elastic consistence through swollen cremaster muscle and hernial sac. Separating cremaster muscle, we opened swollen hernia sac and we found the vermiform appendix, not inflamed. We easily reduced the appendix into the peritoneum cavity, and then we performed the herniotomy according to the Mugnai-Ferrari technique. No post-operative morbidity was reported. The patients was discharged in the first postoperative. We did not have any doubt about avoiding appendectomy in both cases presented; in fact such an intervention, especially in so young patients, had no pathophysiological justification, while it increases the postoperative mortality rate.*

KEY WORDS: Amyand's hernia, Appendectomy, Inguinal hernia

### Introduction

The finding of vermiform appendix in an inguinal hernia is called Amyand's hernia. The Amyand's hernia was described for the first time in a 11-year-old boy who presented with the inflamed appendix in an inguinal hernia sac, perforated by a pin. In treatment of this case Claudius Amyand, (1680-1740) a French refugee sur-

geon, sergeant surgeon to King George II and principal surgeon to the St. George's and the Westminster hospitals of London performed appendiceal resection in 1735<sup>1</sup>. He is credited for the first successful appendectomy. In his honor inguinal hernia containing vermiform appendix is so called. Claudius Amyand

### Cases presentation

A 30 days old newborn and a 4 months old infant had been visited a month earlier and scheduled for inguinal herniotomy in elective surgery.

On admission the patients presented a non-reducible mass in the right inguinal region.

Surgical exploration was performed under general anaesthesia. Inguinal canal is opened through transverse low-

Pervenuto in Redazione Gennaio 2015. Accettato per la pubblicazione Aprile 2015

Correspondence to: Paolo Caiazzo, Via Lisbona 7 85100, Potenza (e-mail: [paolocai@virgilio.it](mailto:paolocai@virgilio.it))

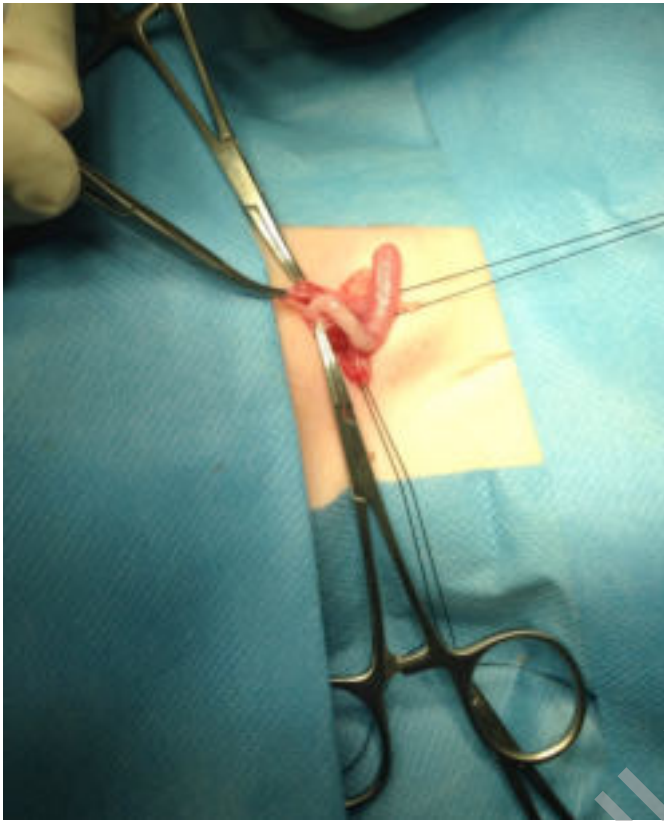


Fig. 1

er abdominal skin fold. Through swollen cremaster muscle and hernia sac we palpated a tubular swelling, of tense-elastic consistence.

Separating cremaster muscle we opened swollen hernia sac and we found the vermiform appendix, non inflamed (Fig. 1).

We easily reduced the appendix into the peritoneum cavity, and then we performed the herniotomy according to the technique of Mugnai-Ferrari.

No post-operative morbidity was reported. The patients were discharged the next morning.

## Discussion

The presentations of vermiform appendix within inguinal hernia sac is called Amyand's hernia. In children, non inflamed appendix is found in about 1% of herniotomies, usually as incidental finding.

Amyand's hernia is extremely rare in children, especially in infants and neonates. Unusual contents may be encountered in an inguinal sa, such as Meckel's diverticulum (Littre's hernia), or a portion of circumference of intestine (Richter's hernia). The presence of vermiform appendix within femoral hernia sac is referred as De Garengeot hernia. A normal appendix within inguinal hernia is estimated to be found in 1%. The finding of

inflamed vermiform appendix within the inguinal hernia is only 0.1% <sup>2-4</sup>.

Most of the cases occur on the right side, probably as a consequence of the normal anatomical position of the appendix and also because right-sided inguinal hernias are more common than left-sided hernias <sup>5</sup>. Although Amyand's hernia has also been reported on the left side, this is a rare condition. There are four conditions responsible for left sided Amyand hernia: situs inversus, mobile cecum, malrotation of intestine, and excessively long appendix.

The most of reported cases discloses with the features of an obstructed or strangulated inguinal hernia, with or without features of appendicitis <sup>6-8</sup>. The diagnosis is made intraoperatively as the patient undergoes surgical exploration for a complicated inguinal hernia, as it happened in the case we are presenting, where appendix was incidentally found in the hernial sac. A preoperative ultrasonography <sup>9</sup> and computed tomography scanning of the abdomen could be helpful for diagnosis, but this is not a routine practice after the clinical suspicion of a complicated inguinal hernia.

The presence or absence of inflammation of the appendix is a very important determinant of appropriate treatment. If inflammation of the organ and incipient necrosis are present, a transherniotomy appendectomy should be performed. The most of Authors agree that a normal appendix within the hernial sac does not require appendectomy, and that every effort should be made to preserve the organ found in the hernia sac for an uneventful postoperative course <sup>10</sup>.

Losanoff described management of Amyand hernia in all the patients (adults and children). Losanoff type I (Normal appendix within sac) should be managed by hernioplasty without appendectomy and Losanoff type II-IV (acute appendicitis within sac) requires appendectomy followed by hernia repair without prosthesis <sup>11</sup>.

Johari et al suggested appendectomy in case of left sided Amyand hernia irrespective of condition of the appendix. The reason for appendectomy in normal looking appendix on left side is that any future appendicitis will have an atypical presentation and can cause diagnostic confusion <sup>12</sup>.

An asymptomatic appendix lying in an inguinal hernia is not suspected preoperatively. The incidence of this finding is not known.

The natural tendency to perform an appendectomy may be overwhelming, but appendectomy is not necessarily beneficial and may be detrimental. In surgical literature debate continues about the advisability of 'incidental' appendectomy during abdominal operations. Guidelines have been promulgated but the issue is far from resolved. Advocates of 'incidental' appendectomy cite decreased future morbidity, mortality and cost of acute appendicitis, without increase in anaesthetic risk, as sufficient justification for removal of the appendix. Opponents of 'incidental' appendectomy suggest that violation of asep-

tic surgical technique by transection of a faecal-containing organ in an otherwise clean operation increases morbidity and mortality from septic complications. Whether or not the appendix should be excised during 'routine' inguinal herniotomy is even less clear. The appendix-conservers are concerned about the theoretically increased risk of wound infection and hernia recurrence if appendectomy is performed<sup>13-23</sup>.

They also point to an increase in operating time as possibly detrimental to the generally elderly patients undergoing herniotomy who may have coincidental medical problems. Additionally, patients in this age group are at low risk of developing acute appendicitis so 'incidental' appendectomy is unlikely to be of prophylactic benefit. 'Incidental' appendectomy was therefore advocated. The correct management of the asymptomatic appendix in Amyand's hernia is unlikely to be defined because controlled trials are difficult to mount in this rare condition. Appendectomy or surgical restraint will continue to depend on the personal beliefs of the surgeon and his or her assessment of the future risk of acute appendicitis versus the risks of wound infection and hernia recurrence.

## Conclusions

The correct management of the healthy vermiform appendix in Amyand's hernia is unlikely to be defined because controlled trials are difficult to perform in this rare condition. Appendectomy or conservative management will continue to depend on the personal beliefs of the surgeon and his or her assessment of the future risk of acute appendicitis versus the risks of wound infection and hernia recurrence.

However, according to the most of Authors, appendectomy is not a necessity unless there are circulatory or inflammatory injuries.

We did not have any doubt about avoiding appendectomy in both cases presented; in fact such an intervention, especially in so young patients, had no pathophysiological justification, while it increases the postoperative mortality rate.

## Riassunto

Il ritrovamento dell'appendice vermiforme nel sacco di un'ernia inguinale è definito ernia di Amyand. Vengono presentati due casi clinici consecutivi riguardanti un neonato di 30 giorni di vita ed un lattante di 4 mesi. Al momento del ricovero i pazienti presentavano una massa non riducibile a livello della regione inguinale destra. L'esplorazione chirurgica è stata eseguita in anestesia generale. Il canale inguinale è stato aperto attraverso un'incisione trasversale a livello di una piega cutanea in regione inguinale destra. A livello del dotto peritoneo

vaginale pervio si palpava una formazione tubulare, di consistenza teso-elastica. Dopo la viscerolisi e l'apertura del dotto peritoneo-vaginale abbiamo rinvenuto l'appendice vermiforme, non infiammata. Abbiamo ridotto facilmente l'appendice nella cavità peritoneale, e quindi effettuato l'erniotomia classica con una plastica del canale inguinale secondo la tecnica di Mugnai-Ferrari. Non abbiamo riportato morbidità post-operatoria. I pazienti sono stati dimessi la mattina successiva. Nei casi presentati, non abbiamo avuto alcun dubbio sul dover evitare l'appendicectomia, che dal punto di vista fisiopatologico aveva alcuna giustificazione, per lo più aggravata dal pericolo di aggravare il rischio di morbidità dopo appendicectomia in pazienti così piccoli.

## References

1. Amyand C: *Of an inguinal rupture, with a pin in the appendix caeci, incruised with stone; and some observations on wounds in the guts.* Phil Trans Royal Soc, 1736; 39:329.
2. Luch JS, Halpern D, Katz DS: *Amyand's hernia: Prospective CT diagnosis.* J Comput Assist Tomogr, 2000; 24:884-86.
3. Logan MT, Nottingham JM: *Amyand's hernia: A case report of an incarcerated and perforated appendix within an inguinal hernia and review of the literature.* Am Surg, 2001; 67:628-29.
4. Thomas WE, Vowles KD, Williamson RC: *Appendicitis in external herniae.* Ann R Coll Surg Engl, 1982; 64:121-22.
5. Pellegrino JM, Feldman SD: *Case report: Acute appendicitis in an inguinal hernia.* N J Med, 1992; 89:225-26.
6. Livaditi E, Mavridis G, Christopoulos-Geroulanos G: *Amyand's hernia in premature neonates: Report of two cases.* Hernia, 2007; 11:547-49.
7. Nigri G, Costa G, Valabrega S, Aurello P, D'Angelo F, Bellagamba R, et al.: *A rare presentation of Amyand's hernia. Case report and review of the literature.* Minerva Chir, 2008; 63:169-74.
8. Solecki R, Matyja A, Milanowski W: *Amyand's hernia: A report of two cases.* Hernia, 2003; 7:50-51.
9. Celik A, Ergun O, Ozbek SS, Dokumcu Z, Balik E: *Sliding appendiceal inguinal hernia: Preoperative sonographic diagnosis.* J Clin Ultrasound, 2003; 31:156-58.
10. Franko J, Raftopoulos I, Sulkowski R: *A rare variation of Amyand's hernia.* Am J Gastroenterol, 2002; 97:2684-685.
11. Losanoff JE, Basson MD: *Amyand hernia: What lies beneath. A proposed classification scheme to determine management.* Am Surg, 2007; 73:1288-90.
12. Johari HG, Paydar S, Davani SZ, et al.: *Left-sided Amyand hernia.* Ann Saudi Med, 2009; 29:321-22.
13. D'Alia C, Lo Schiavo MG, Tonante A, Taranto F, Gagliano E, Bonnano L, et al.: *Amyand's hernia: Case report and review of the literature.* Hernia, 2000; 7:89-91.
14. Breitenstein S, Eisenbach C, Wille G, Decurtins M: *Incarcerated vermiform appendix in a left-sided inguinal hernia.* Hernia, 2005; 9:20-22.

15. Malik KA: *Left sided Amyand's hernia*. J Coll Physicians Surg Pak, 2010; 20:480-81.
16. Hutchinson R: *Amyand's hernia*. J R Soc Med, 1993; 86(2):104-104.
17. Giorgetta C, Caputo P, Zuccon W, D'Angelo C, Balduzzi V, Tagliabue F, Bonandrini L: *Amyand's hernia. Clinical Case*. Ann Ital Chir, 2007; 78:521-23.
18. Ryan WJ: *Hernia of the vermiform appendix*. Ann Surg, 1937; 106:135-39.
19. Apostolidis S, Papadopoulos V, Michalopoulos A, Paramythiotis D, Harlaftis N: *Amyand's Hernia: A case report and review of the literature*. The Internet Journal of Surgery, 2005; 6:1.
20. Leopoldo C, Francisco M, David B, Sofia V: *Amyand's Hernia: Case report with review of literature*. The Internet Journal of Surgery, 2007; 12:2.
21. Meinke AK: *Review article: appendicitis in groin hernias*. J Gastrointest Surg, 2007; 11:1368-372.
22. Sharma H, Gupta A, Shekhawat NS, Memon B, Memon MA: *Amyand's hernia: A report of 18 consecutive patients over a 15-year period*. Hernia, 2007; 11(1):31-35.
23. Kajmakci A, Akillioglu I, Akkoyum I, Guven S, Ozdemir A, Gulen S: *Amyand's hernia: A series of 30 cases in children*. Hernia, 2009; 13(6):609-12.
24. Park J, Hemani M, Milla SS, Rivera R, Nadler E, Alukal JP: *Incarcerated Amyand's hernia in a premature infant associated with circumcision: A case report and literature review*. Hernia, 2010; 14(6):639-42.

READ-ONLY COPY  
PRINTING PROHIBITED