

Study of the antireflux function of the Roux-en-y jejunal loop in reconstruction following gastrectomy



Ann. Ital. Chir., LXXIII, 3, 2002

N. Picardi*, E. Santeusano**, G. Tucci*

*I Div. Clinicizzata di Chirurgia Generale
Università "G. d'Annunzio" di Chieti

**Medicina Nucleare - Osp. SS. Salvatore di Pescara

Introduction

The different reconstruction methods adopted in the past years, after a gastric resection or a total gastrectomy sign the various phases of the evolution of pathophysiological knowledge from the late 800s with Billroth to now. In the last 25 years spreading of staplers has favored further technical innovations, so allowing new, easier solutions. Physionomy of stomach demolitive surgery has been substantially changed all around the world due to two different reasons:

1. the new pharmacological therapies of ulcer and the assessment of new causing agents has reduced and reduces the necessity for surgical treatment of gastroduodenal ulcers, which enter the operating room only occasionally.
2. the incidence of gastric cancer is reduced all over the world, although the increase of mean life reduces the entity of such a reduction, and modernization of surgical techniques, not of intraoperatively but also pre- and postoperatively, widens indications for gastric resections even in the elderly.

Reconstruction of gastric continuity after Billroth I resection is aimed at restoring duodenal transit, so to optimize absorption, especially of iron.

The pathophysiological price to pay for this type of reconstruction is alkaline reflux in the proximal digestive tract, resulting in gastritis and esophagitis. Such price is so high

Abstract

Persistence of global orthograde peristaltic propulsion in the Y jejunal loop according to Roux makes this latter adequate for reconstruction of digestive transit after gastric resection or total gastrectomy, simultaneously avoiding reflux. Ectopic pacemakers can set in its proximal tract and favor intestinal and bile juice reflux in the gastric stump or esophagus, especially if the loop is too short and the new pacemaker is far from its superior margin. Moreover, the slower peristaltic waves can favor a relative stasis and, thus, a containing function, which could represent an element of morbidity over a certain limit.

If the Y loop is not too long, but long enough to include the higher frequency ectopic pacemaker, which overcomes the lower frequency ones located distally, the positive aspects of both these characteristics can be exploited for satisfying and free of morbidity results. We believe that the best length is 35-40 cm, with positive clinical results. ⁹⁹Tc-HIDA sequential scintigraphy clearly shows the absence of bile material reflux in the digestive tract proximal to the anastomosis.

Key words: Roux-en-Y jejunal loop, total gastrectomy, gastric resection, antireflux ileal loop.

Riassunto

STUDIO DELLA FUNZIONE ANTIREFLUSSO DELL'ANSA DIGIUNALE AD Y SECONDO ROUX NELLA RICOSTRUZIONE DOPO GASTRECTOMIA TOTALE

La persistenza di una propulsione peristaltica globale di tipo ortograde nell'ansa digiunale ad Y secondo Roux fa sì che essa sia adeguata per ricostruire il transito digestivo dopo resezione gastrica o dopo gastrectomia totale, evitando nello stesso tempo i reflussi.

Pacemakers ectopici possono attivarsi nel suo tratto proximale e favorire un reflusso biliare ed enterico nel moncone gastrico o nell'esofago, specie se l'ansa è troppo breve ed il nuovo pace-maker si localizza lontano dal suo margine superiore. Inoltre le lente onde peristaltiche possono favorire una stasi relativa e quindi una funzione di serbatoio, che può rappresentare però un elemento di morbidità se eccessiva.

Se però l'ansa ad Y non è troppo lunga, ma abbastanza

da comprendere il pacemaker ectopico alla frequenza più alta, che sovrasta quello a frequenza più bassa localizzato più distalmente, gli aspetti positivi di entrambe queste due caratteristiche possono essere utilizzate per ottenere risultati soddisfacenti e privi di morbidità. Crediamo che per i migliori risultati clinici si ottengono con una lunghezza dell'ansa compresa tra 35 e 40 cm. La scintigrafia sequenziale con ⁹⁹Tc-HIDA mostra chiaramente l'assenza di reflusso di materiale biliare nel tratto digestivo prossimale all'anastomosi.

Parole chiave: Ansa ileale antireflusso, gastrectomia totale, resezione gastrica, ansa a Y secondo Roux.

that this solution has to be rationally discarded because it only apparently privileges the anatomic solution at the expense of heavy exposition to future morbidity causes. Other methods aimed at anatomical restoration try to reconstitute gastric "container". Thus, surgeon fantasy has outlined many solutions which are all more or less complex, since they tend to maintain duodenal transit and prevent gastro-esophageal reflux.

For example, through a jejunal loop interposed between the esophagus or the gastric stump and post-pyloric duodenum. The weak points of almost all these solutions are possible ingest stasis and the lack of attention to the meaning of the essential pyloric function, which is lost any ways.

On the other hand, many surgeons have for years adopted simplified reconstruction through Y jejunal loop according to Roux, and this technique has shown many advantages: a) easy and fast reconstructions; b) non-significant intrinsic morbidity; c) good recovery and maintenance of post-operative health.

A fundamental element in executing a reconstruction using an Y jejunal loop according to Roux is the attention that must be payed to the length of the loop to interpose. If it is adequate, the new higher frequency pacemaker, which takes over, has good chances of localizing itself relatively proximally, with the following advantages:

1. moderate stasis in the loop which works as temporary container, and without obstacles to emptying;
2. prevention of bile reflux in the digestive tract proximal to the loop.

As for post-operative control, the patient clinical and laboratory status can witness the relative importance of duodenal transit sparing. Reflux prevention is generally controlled only by endoscopy based on patient subjective claims. Therefore, we have decided to verify effectiveness of these functional elements of the loop isolated according to Roux for preventing bile reflux.

We believe that this latter is extremely important for quality of life and prognosis of possibile future morbidity. Therefore study of HIDA route during follow-up in a series of patients subjected to gastric resection or total gastrectomy seemed useful. Indeed, possibile reflux in the Roux loop and up to the superior digestive tract is easily revealed by sequential scintigraphy.

Material and Methods

Patients in our series, previously subjected to total gastrectomy or to gastric resection were followed-up. They all had had uniform reconstruction of the digestive transit, using always a 35 and 40 cm jejunal loop according to Roux. The gastro-jejunal or esophageal-jejunal anastomosis was performed with 25 or 28 mm circular staples. Likewise, the lower jejunal-jejunal anastomosis was performed before the superior one using a 25 mm circular staple. All patients were subjected to a series of nutritional, blood, and x-ray controls of the esophageal-gastric-jejunal or esophageal-jejunal transit. Furthermore, where indicated, patients underwent tumor investigations. In order to follow in time bile bolus characteristics of progression, sequential scintigraphy after ⁹⁹Tc-HIDA administration represented the main means to verify results and effectiveness of our reconstruction strategy. Table I reports the series of patients subjected to such controls.

Tab. I – SERIES FROM I DIVISIONE CLINICIZZATA DI CHIRURGIA GENERALE (1993-2000)

<i>Non-tumor diseases – Total number of patients</i>	45	F	M
Resection after Billroth II	8	4	4
Subtotal gastrectomy + Roux-en-Y	37	15	22
<i>Tumor diseases – Total number of patients</i>	36	F	M
Superior Gastric Resection	1	–	1
Resection after Billroth II	6	3	3
Subtotal gastrectomy + Roux-en-Y + LN R3	21	4	17
Total gastrectomy + Roux-en-Y + LN R3	8	3	5

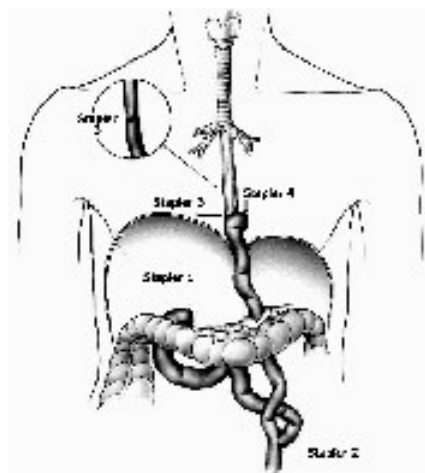


Fig. 1: Reconstruction using Y jejunal loop according to Roux.

Imaging Results

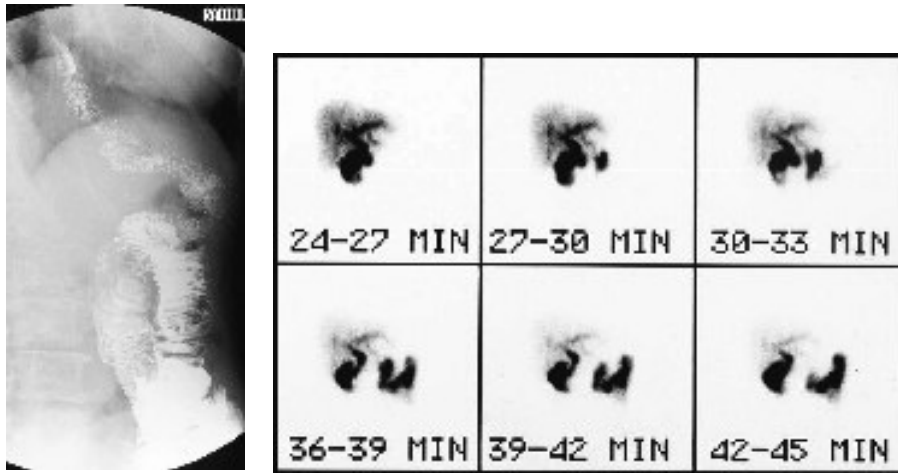


Fig. 2: a) Esophageal-jejunal transit after total gastrectomy and esophageal-jejunal reconstruction using Roux Y jejunal loop. b) Sequential control of transit with 99Tc-HIDA without esophageal reflux.

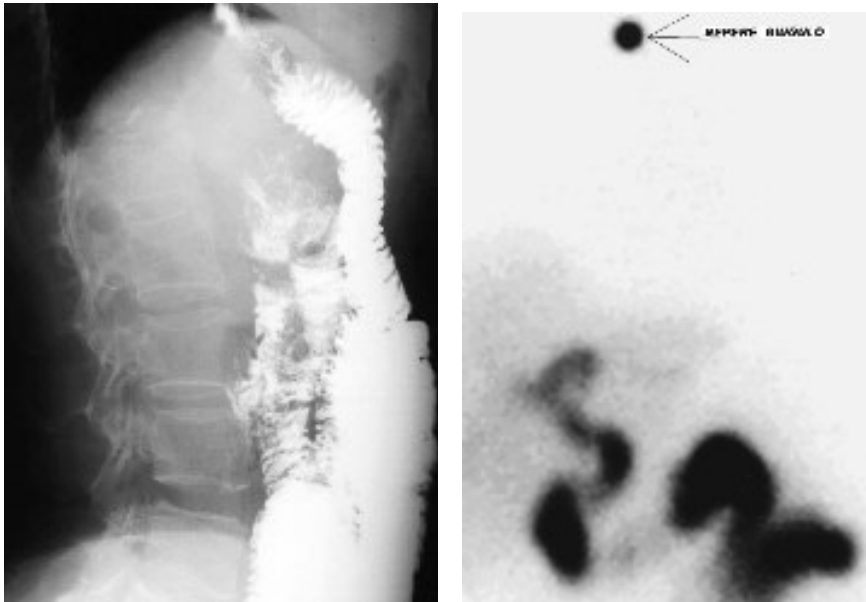


Fig. 3: a) Esophageal-jejunal transit after total gastrectomy and esophageal - jejunal reconstruction using Roux Y jejunal loop. b) Sequential control of transit with 99Tc-HIDA without esophageal reflux.

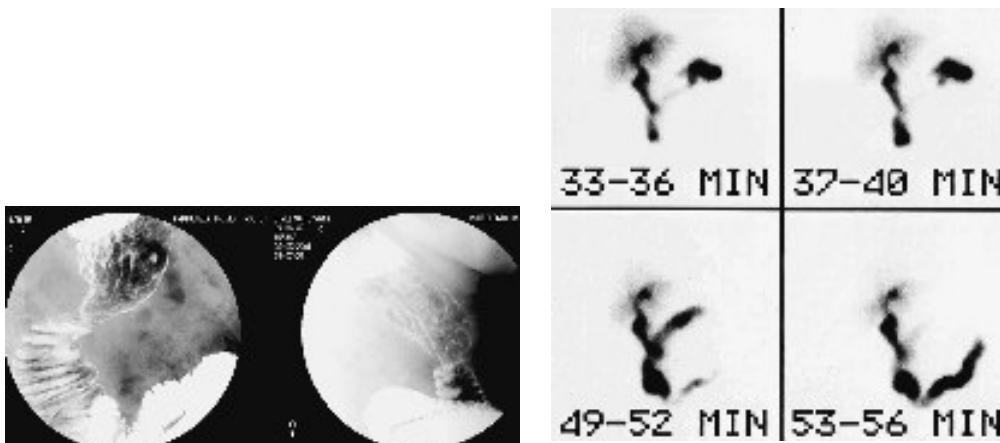


Fig. 4: a) Esophageal-je-junal transit after sub total gastrectomy and esophageal-jejunal reconstruction using Roux Y jejunal loop. b) Sequential control of transit with 99 Tc-HIDA without gastric stump reflux.

Discussion and Conclusions

Thanks to reflex intrinsic motility of muscular layers, which is spared in an isolated jejunal loop (4), the orobal sense of "Bayliss and Sterling peristaltic reflex" is likewise spared (3).

However, if the jejunal loop is not interrupted bipolarly but only proximally – loop according to Roux – then, in its median tract, at variable distance from the proximal end, a series of ectopic pacemakers fire. The most proximal pacemaker is capable of triggering an orthodromic peristaltic wave only in its distal tract, while the proximal loop is run by a retrograde wave (5).

This condition results in: firstly, slowing down of orobal progression of the bolus in the Roux proximal tract (1); and secondly, the possibility to trigger reflux (5) of the proximal content in oral direction.

Jejunal section located after Treitz loop interrupts the progression of the peristaltic wave triggered by the duodenal pacemaker, and the slower ectopic jejunal pacemakers gain value, since freed from duodenal control (5). The impulses generated by the most proximal ectopic pacemaker are slowly transmitted orally, so favoring reflux. Consequently, if Roux loop is too long a pathologic stasis can develop (1, 2). On the other hand, if it is too short, then reflux can result (6, 2).

In cases of reconstruction with Roux loop after total gastrectomy or gastric resection, such reflux of intestinal and bile juice would provoke alkaline stump gastritis or esophagitis.

The ideal Roux loop lengths are 35-40 cm (7). In our patients this is confirmed by the constant absence of morbidity due to Roux loop motility: neither stasis nor reflux. This latter aspect was demonstrated through ⁹⁹Tc-HIDA sequential scintigraphy.

Dilation of the proximal tract of Roux loop is somehow auspicable, since it represents some kind of food container which substitutes the stomach. Contrarily, a possible reflux must be avoided.

This can be obtained limiting the length of the loop between 35 and 40 cm. Forty cm length must not be overcome so to avoid excessive slow down of emptying peristalsis in the Roux loop. Moreover, loop length must be at least 35 cm so to avoid reflux of intestinal and bile juice in the gastric stump and esophagus as a result of ectopic pacemaker firing.

References

- 1) Eagon J.C., Miedema B.W., Kelly K.A.: *Postgastrectomy syndromes*. Surg Clin North Am, 72/2, 445, 1992.
- 2) Gustavsson S., Illstrup D.M., Morrison P.: *Roux Y stasis syndrome after gastrectomy*. Am J Surg, 155, 490-494, 1988.
- 3) Kosterlitz H.W.: *Intrinsic and extrinsic nervous control of motility of the stomach and intestine*. In: *Handbook of physiology*, Sect. 6, Vol. 4, C.F. Code Ed., Washington D.C., American Physiology Society, 2147, 1968.
- 4) Macagno E., Melville J., Christensen J.: *A model for longitudinal motility of the small intestine*. Biorheology, 12, 369, 1975.
- 5) Miedema B.W., Kelly K.A., Camilleri M., Hanson R.B., Zinsmeister A.R., O'Connor M.K., Brown M.L.: *Human gastric and jejunal transit and motility after Roux gastrojejunostomy*. Gastroenterology, 103, 1133-1143, 1992.
- 6) Perino L.E., Adcock K.A., Goff J.S.: *Gastrointestinal symptoms, motility and transit after Roux-en-Y operation*. Am J Gastroenterol, 83, 280-385, 1988.
- 7) Picardi N., Leombruni E., Bartolacci M., Ghimenti A.: *Fisiopatologia motoria dell'ansa isolata del tenue in chirurgia ricostruttiva funzionale. Dati della ricerca chirurgica sperimentale*. Ann. Ital Chir, 65/4, 399-405, 1994.

Address for correspondence:

Prof. Nicola PICARDI
Via Montevideo, 6
00198 ROMA - ITALIA
E-mail: picardi@unich.it