



Combining traditional and microsurgical reconstruction after a complex hand trauma with multiple tissue defects.

A case report



Ann Ital Chir, 2021; 10 - July 12

pii: S2239253X21035581

Online Epub

Francesco Messina, Diego Faccio, Sandro Rizzato, Paolo Marchica, Franco Bassetto, Vincenzo Vindigni, Cesare Tiengo

Clinic of Plastic Surgery, University of Padua; Padua, Italy

Combining traditional and microsurgical reconstruction after a complex hand trauma with multiple tissue defects. A case report.

Complex injuries involving bones, tendons and soft tissues of the hand still represent a difficult challenge for reconstructive surgeons. Hereby, we present a case of a man suffering from a complex crush injury of the right hand that led to a wide three-dimensional defect with loss of two metacarpal bones, extensor tendons and skin.

For composite hand defects, the most common surgical approach provides for a one-stage composite reconstruction or for an early restoration of bone and skin, with delayed tendon grafts. For the peculiarity of the defect, a one-stage reconstruction was not feasible. Hence, we opted for a two-stage reconstruction but the usual surgical steps have been inverted.

First we secured tendon and skin restoration through a composite teno-cutaneous radial free flap. A month later, we reconstructed the two metacarpals with a modified Masquelet technique using fibular cortical graft. This strategy allowed the patient to start an early rehabilitation program and obtain a satisfactory recovery of his dominant hand.

KEY WORDS: Composite flap, Hand trauma, Hand reconstruction, Microsurgery

Introduction

Large composite defects of the hand still represent a difficult challenge for reconstructive surgeons. The complexity of these defects relies on the multiple damage involving bones, tendons and soft tissues. The prolonged recovery time makes rehabilitation even more challenging, because of the high risk of scar adhesions ¹. To date, literature reports one-stage composite reconstructions to have the best outcomes ². Success can be achieved through locoregional or free tissue transfer. The main

decisional criteria are the size of the defect and the nature of the tissues involved. Defect <20cm² are properly reconstructed through locoregional solutions. Otherwise, the best treatment for wider defects is the microsurgical approach. The ipsilateral forearm provides several locoregional reconstructive options, while for free tissue transfer the upper and lower limb represent the best donor sites ³.

Hereby, we present a case of a work-related complex trauma of the dorsum of the hand in an adult male patient. The man suffered from severe loss of substance involving two metacarpal bones (MC), their extensor tendons and the overlying skin. After debridement, we performed a two-stage reconstruction, which started with a contralateral radial teno-cutaneous free flap for soft tissue reconstruction. Afterwards, using a modified Masquelet technique, fibular cortical bone grafts were performed for metacarpal restoration.

The unicity of this case resides on the combination of a traditional technique (Masquelet) and a modern one

Pervenuto in Redazione Dicembre 2020. Accettato per la pubblicazione Marzo 2021

Correspondence to: Francesco Messina, MD, Clinic of Plastic Surgery, University of Padua, Via Nicolò Giustiniani 2, Padua, PD, 35128, Italy (e-mail: dott.fmessana@gmail.com)

(composite flap), and on its particular timeline, since the usual surgical steps are reversed. Indeed, to manage a complex hand reconstruction, most authors report the bone and skin reconstruction as the first step, followed by a delayed tendon transfer or graft⁴. Since the satisfying results, we may recommend this approach as a safe option when facing composite hand reconstruction.

Case Report

A caucasian 58-year-old male, with Huntington disease and no other medical issues, presented at the ER in October 2018 suffering from a complex trauma involving his dominant hand. An industrial machinery caused a severe crush injury on the right hand dorsum. Physical examination revealed a large contaminated wound with exposed MC bones (Fig. 1A). Extensor digitorum tendons of the II and III finger and the extensor indicis proprius tendon were missing. Finger vascularization and innervation were preserved but sensitiveness of the dorsum was compromised. Hand radiographs showed comminuted and plurifragmentary fractures of the II and III MC with loss of substance.

Immediate antibiotic prophylaxis was administered. After debridement, the proximal half, part of the head of the II MC and the proximal third of the III MC were left in place. A 1.6mm K-wire was used to stabilize the second ray (Fig. 1B). Four days later, we performed further debridement and positioned two external fixators. The overlying skin suffered from full-thickness necrosis causing a gap of 45cm².

Twenty days later, the resulting bony gaps (about 3.6 cm and 3.7 cm respectively for the II and the III MC

bones) were filled with antibiotic-loaded cement spacers to induce the formation of a pseudo-synovial membrane that could host a bone graft as described by Masquelet⁵. A composite teno-cutaneous flap based on the contralateral radial artery was harvested to restore the soft tissues. Portions of flexor carpi radialis and brachioradialis tendons were harvested within the flap, together with a part of the left medial antebrachial cutaneous nerve. The palmaris longus tendon was not used because congenitally absent. End-to-end anastomoses were performed between the flap vessels (radial artery and cephalic vein) and the recipient site (deep branch of radial artery and cephalic vein). The medial antebrachial cutaneous nerve was anastomosed with a sensitive branch of the recipient radial nerve (Figs. 2 A-D). Integra® (Integra Life Sciences, Plainsboro, NJ, USA) and a split-thickness skin graft were used for donor site closure and rehabilitation started the following week.

Four weeks later, we completed the Masquelet procedure, preceded by the removal of the external fixators. The cement spacers were replaced by solid fibular cortical grafts, synthesized with plates and screws at the shaft and K-wires at the metacarpophalangeal (MCP) joints (Fig. 3 A-D).

No post-op complications occurred but the patient developed MCP joint stiffness, which led to revision surgery. The plate of II MC was removed and concurrent tenolysis of both the extensor tendons was needed to improve range of motion.

18-months follow-up showed an effective morphofunctional outcome. Bone grafts fully integrated, sensitiveness of the dorsum, flexor and extension functions were satisfactorily restored (Fig. 4 A-E). The patient was able to use his hand without further significant impairment,

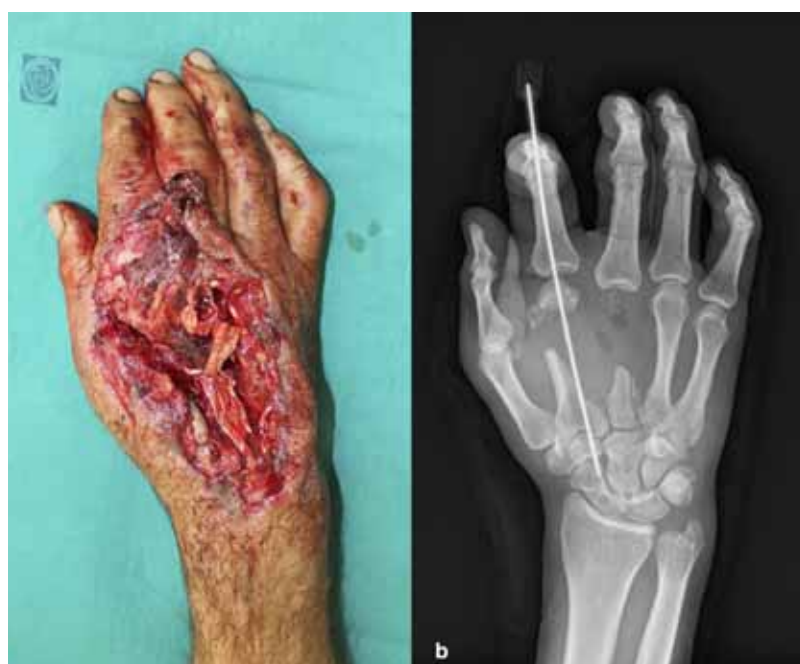

Fig. 1. A) Acute trauma showing loss of cutaneous and subcutaneous tissues. Extensor tendons for the 2nd and 3rd digit appear extensively compromised. B) Radiogram after initial debridement showing the bony gap at the 2nd and 3rd metacarpal bones.

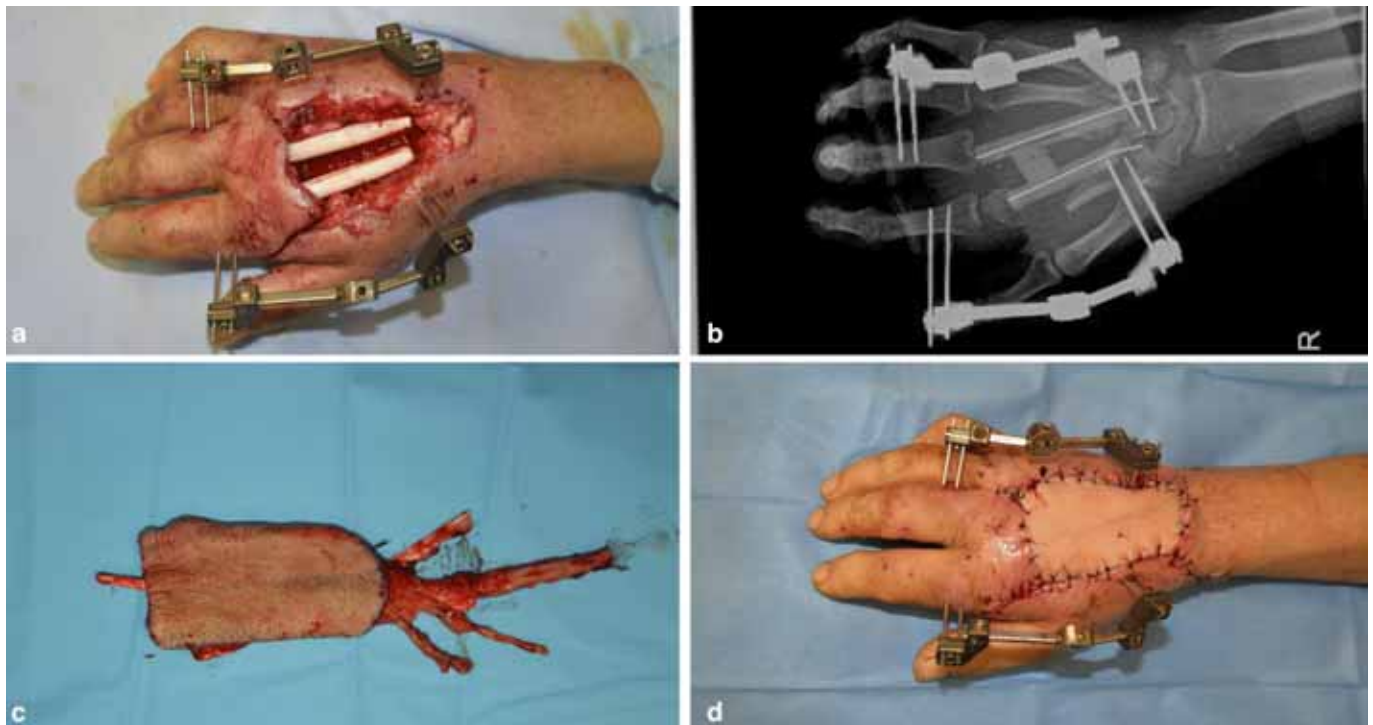


Fig. 2. First reconstructive stage. A) Hand dorsum after further debridement. Cement spacers for 2nd and 3rd metacarpal bones, and external fixators in place. B) Post-op radiogram of the hand. C) Composite tenocutaneous radial flap. It is possible to see portions of the brachioradialis and flexor carpi radialis tendons, sensitive branches of the radial nerve and the radial artery. D) Immediate post-op picture.

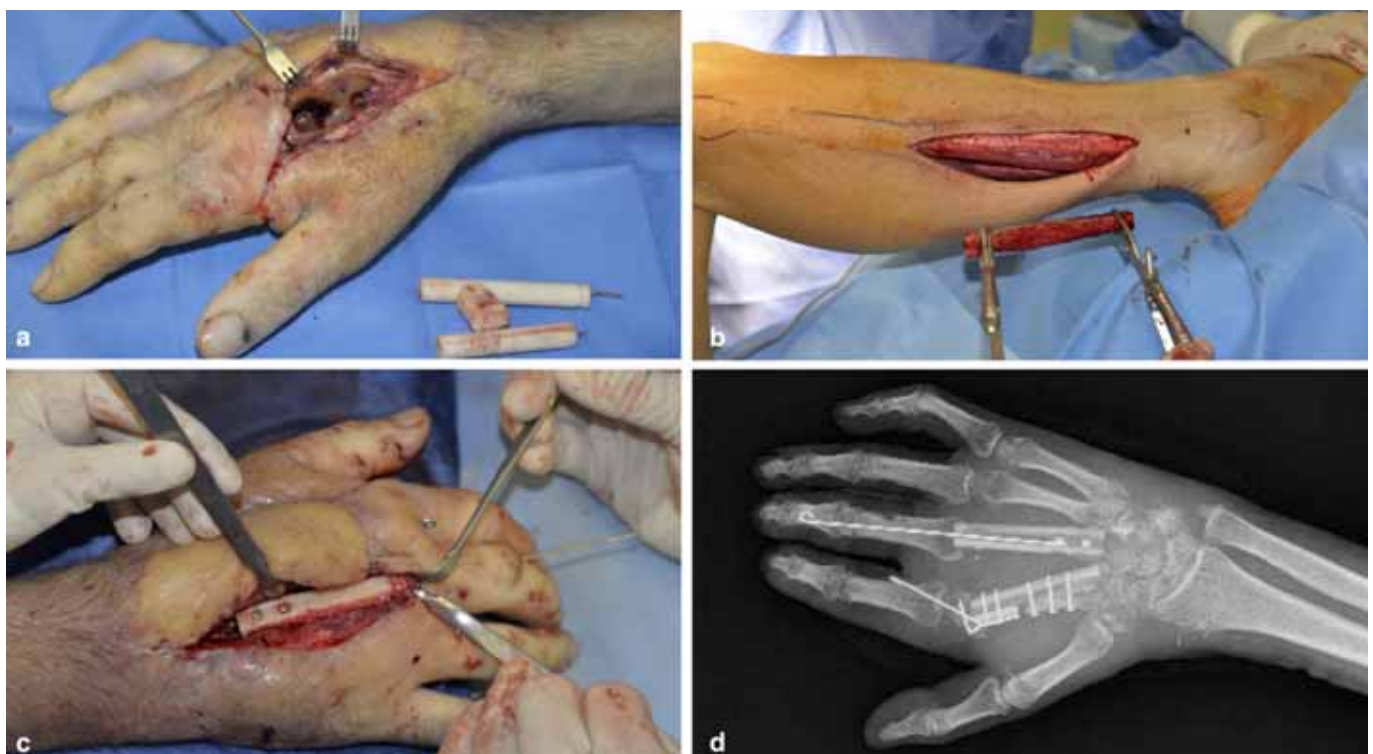

Fig. 3. Second reconstructive stage. A) Removal of the cement spacer. B) Harvest of the fibular cortical graft. C) Insetting the bone grafts into the recipient site. D) Immediate post-op radiogram.

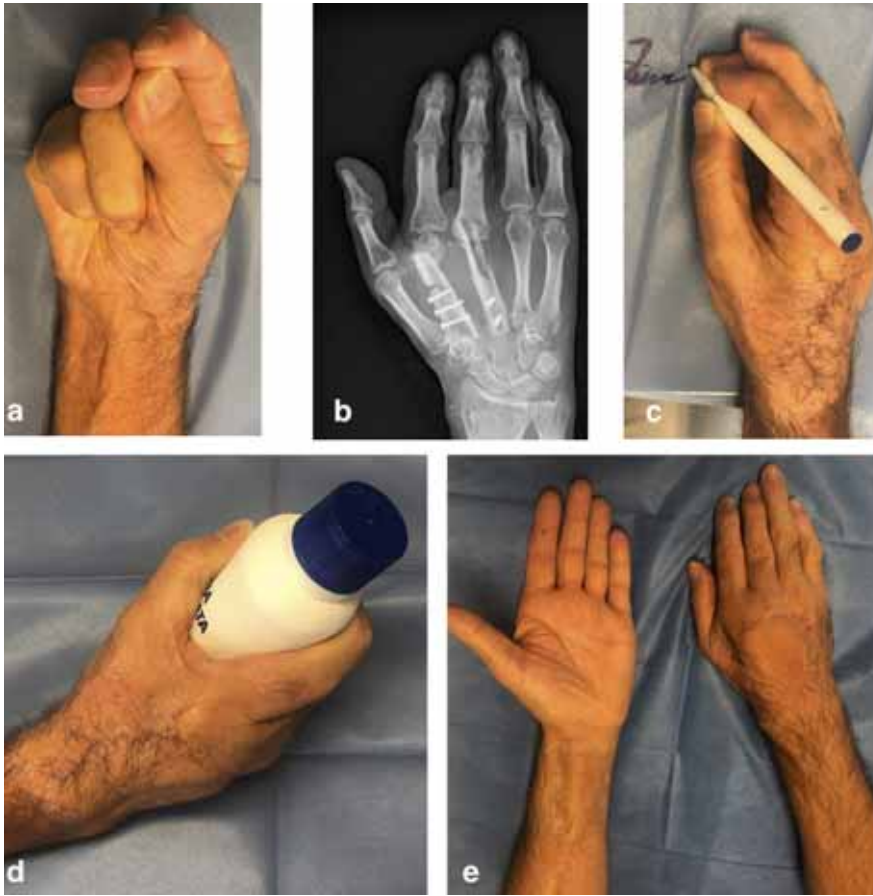

Fig. 4. Control at 18 months. A-C-D) Functional recovery with pinch and grasp movements. B) Control radiogram showing bone's full integration. E) Aesthetic outcome.

allowing return to work 8 months after the trauma. All the surgeries were performed by the same team, composed by a senior plastic surgeon and the assistant residents, under general anaesthesia and arm tourniquet.

Discussion

Three-dimensional hand defects and function's recovery represent a challenge both for the patient and the surgeon, thus we presented our two-step experience of reconstruction with a composite teno-cutaneous radial forearm flap and modified Masquelet procedure with fibular bone grafts.

Different options are suitable to reconstruct hand injuries involving bones, tendons and skin ³. The treatment of cutaneous defects may be achieved with pedicled or free flaps. The pedicled posterior interosseous flap is one of the most useful for the coverage of soft tissue defects of the dorsum. Nonetheless, it does not allow harvesting vascularized tendons ⁶. Distally based radial and ulnar flaps represent valid coverage options. Although, they require the sacrifice of one of the main arterial vessels of the forearm, and this could jeopardize the vascular supply of an already compromised hand ⁷. Finally, local perforator flaps spare the main arteries, but provide coverage for moderate-sized defects ⁸. Therefore, we opted

for a microsurgical reconstruction.

Formerly, extensor tendon defects of the hand have been secondarily reconstructed through a combination of tendon transfers and grafts, hindering early mobilization and resulting in possible joint stiffness and tendon adhesions, with impaired functional outcome. Contrariwise, vascularized free tendon transfers heal faster and develop less adhesions as they retain the tendon sheaths. Besides, postoperative rehabilitation starts earlier because the tendons' continuity occurs faster than tendon grafts ¹.

Bone continuity and stabilization, together with an adequate soft tissue coverage, are pivotal to the reconstructive program ⁹. Literature reports many composite flaps including skin, bones, and tendons, and each one has specific issues regarding the prompt return to a proper hand function, the restoration of a fair aesthetic appearance, and the residual morbidity of the donor site.

Our choice ranged between two different composite free flaps: the contralateral radial or the dorsalis pedis. To date, the latter is rarely used because of the donor site morbidity, especially if two metatarsal bones have to be harvested, thus we preferred the radial forearm flap [3]. The reconstruction of missing bone segments may be achieved through different procedures: autologous bone grafts, allogenic bone grafts, vascularized bone free flaps. Each technique is characterized by different qualities, indications, and osteogenic properties, thus a careful

selection is necessary. The Masquelet technique represents an alternative to the bone flaps. The induction of a pseudo-synovial membrane creates a biological chamber, which can accommodate and favours the integration of bone grafts⁷. The original technique provides for the graft of crushed bone. Although, we preferred solid fibular bone graft because it very much resembled the MC for dimension and cortical component. Also, it allowed us to ensure immediate bone stability and to continue the rehabilitation program. In our case, the radius and the iliac crest could not supply the quantity of bone required to reconstruct two MC. Bone free flaps are valid options but a second free flap on the same site was judged too risky. Worse and unsatisfactory healing and higher infective risk were observed in bone allografts compared to autologous grafts¹⁰.

Several authors state that free composite osteo-cutaneous flaps allow adequate soft tissue coverage, bone stability and reduced immobilization time⁴. Nonetheless, our case suggests that firstly providing a free composite teno-cutaneous reconstruction, followed by an autologous bone graft could lead to comparable outcomes. Hence, we propose this multi-staged reconstruction as a safe and effective option for hand reconstruction.

Riassunto

I traumi complessi interessanti le ossa, i tendini e i tessuti molli della mano rappresentano ancora oggi una sfida impegnativa per i chirurghi ricostruttivi. Presentiamo in questo nostro lavoro un caso di un paziente affetto da un trauma complesso da schiacciamento della mano destra che ha causato un ampio difetto tridimensionale con la perdita di due ossa metacarpali, dei tendini estensori e della cute.

Per i difetti compositi della mano, l'approccio chirurgico più comune consiste in una ricostruzione multi-tissutale in un unico o in due step successivi, rispettivamente dell'osso e della cute, e solo in seguito dei tendini. Per via della peculiarità del trauma in oggetto, una ricostruzione one-stage non è stata possibile. Pertanto si è optato per una ricostruzione in due step, invertendo tuttavia le procedure chirurgiche abituali.

Primariamente si è proceduto alla ricostruzione dei tendini e della cute tramite un lembo libero microchirurgico radiale composito teno-cutaneo. Un mese dopo sono state ricostruite le due ossa metacarpali mancanti con la tecnica di Masquelet modificata utilizzando un innesto osseo corticale di perone. Questa strategia ha consentito al paziente di iniziare un programma di riabilitazione precoce e di ottenere un recupero soddisfacente delle funzioni della sua mano dominante.

References

1. Adani R, Marcoccio I, Tarallo L: *Flap coverage of dorsum of hand associated with extensor tendons injuries: A completely vascularized single-stage reconstruction*. Microsurgery 2003; 23(1):32-9.
2. Sundine M, Scheker LR: *A comparison of immediate and staged reconstruction of the dorsum of the hand*. J Hand Surg Br, 1996; 21(2):216-21.
3. Adani R, Tarallo L, Fonzone Caccese A, Delcroix L, Cardin-Langlois E, Innocenti M: *Microsurgical soft tissue and bone transfers in complex hand trauma*. Clin Plast Surg, 2014; 41:361-83.
4. Addosooki A, Said E, Kenaway M, Yousef MA: *Reconstruction of complex hand defects using trapezoidal osteocutaneous free fibular flap*. Microsurgery, 2020; 40(3):306-14.
5. Wong TM, Lau TW, Li X, Fang C, Yeung K, Leung F: *Masquelet technique for treatment of posttraumatic bone defects*. Scientific World Journal, 2014; 710302.
6. Barin EZ, Cinal H, Kara M, Çakmak MA, Tan Ö: *Versatile use of the posterior interosseous flap in the reconstruction of complex upper limb defects*. Ulus Travma Acil Cerrahi Derg 2019; 25(6):597-602.
7. Acar MA, Güleç A, Aydin BK, Erkoçak ÖF, Elmadag M, Türkmen F: *Reconstruction of dorsal hand and finger defects with reverse radial fasciocutaneous forearm flaps*. Eur J Orthop Surg Traumatol, 2015; 25(4):723-29.
8. Ho AM, Chang J: *Radial artery perforator flap*. J Hand Surg Am, 2010; 35(2):308-11.
9. Wink JD, Gandhi RA, Ashley B, Levin LS: *Flap Reconstruction of the Hand*. Plast Reconstr Surg 2020; 145(1):172e-183e.
10. Wang W, Yeung KWK: *Bone grafts and biomaterials substitutes for bone defect repair: A review*. Bioact Mater, 2017; 2(4):224-47.