



# Nonoperative management for major blunt hepatic trauma

## A case report



Ann. Ital. Chir.

Published online (EP) March 2015

pii: S0003469X15022320

[www.annitalchir.com](http://www.annitalchir.com)

Andrea Mingoli, Andrea Saracino, Gioia Brachini, Giovanni Mariotta, Emanuele Migliori, Vania Silvestri

UO Chirurgia del Politrauma, Department Emergenza e Accettazione, Department of Surgery P. Valdoni, Policlinico Umberto I, Sapienza University, Rome, Italy

### Nonoperative management for major blunt hepatic trauma. A case report

**INTRODUCTION:** Over the past 20 years the management of blunt liver trauma has evolved from a primary operative approach to a nonoperative one, for both low and high grade injuries, only on the basis of hemodynamic stability. However, in spite of a high success rate of non operative management, it is frequently observed, also in our country, an old fashioned way to approach these patients, based on habit more than observation and evidence based medicine.

**CASE REPORT:** We present a case of successful nonoperative treatment of a grade IV blunt liver trauma (lacerato-contusive injury of V, VI and VII segments) in a 34-year-old woman.

**DISCUSSION:** Nowadays more than 85% of liver injuries are managed without operative intervention, irrespective of the injury grade. Success rate of the conservative approach ranges from 82% to 100% and almost all complications (14% in high grade injuries) can be managed with interventional radiology procedures, still avoiding major surgery.

**CONCLUSION:** Today, in the absence of other abdominal injuries requiring surgical exploration, hemodynamic instability from ongoing hemorrhage after primary evaluation and resuscitative treatment, is the only indication to an operative management of traumatic liver injuries.

**KEY WORDS:** Blunt hepatic trauma, Hemoperitoneum, Liver complications.

### Introduction

Over the past 20 years there have been important changes in the management of blunt hepatic trauma and major injuries have been more often conservatively treated<sup>1,2</sup>. Nowadays Evidence Based Medicine (EBM) has demonstrated the cruciality of hemodynamic conditions,

instead of grade of liver injury and hemoperitoneum volume, as a main criterion in deciding between nonoperative management and surgery<sup>3,4</sup>.

However, even if modern international guidelines and algorithms on management of blunt liver trauma are widely available, it is frequent to observe an old-fashioned way to approach this matter, based on habit more than observation and EBM<sup>5</sup>.

We describe a clinical case of major (grade IV) liver injury in a young woman successful treated with non operative management.

### Case Report

A 34-year-old female sustained a blunt trauma of the right hemithorax due to an accidental fall on a bedhead from 1.5 m high ladder. Approximately 1 hour after the

Pervenuto in Redazione Ottobre 2013. Accettato per la pubblicazione Gennaio 2014

Correspondence to Andrea Mingoli, M.D. Associate Professor of Surgery Chief UO Chirurgia del Politrauma Dept. Emergenza e Accettazione, Dept. of Surgery "P. Valdoni", Sapienza University, Policlinico "Umberto I", Viale del Policlinico 155, 00161 Rome, Italy (e-mail [andrea.mingoli@uniroma1.it](mailto:andrea.mingoli@uniroma1.it))

injury, the patient was admitted to our Emergency Department. She was conscious, but her physical examination revealed pallor, marked dyspnea, tachypnea (Respiratory Rate 24/min), tachycardia (Heart Rate 104 bpm), intense right upper quadrant pain and blood pressure (BP) of 90/60 mm/Hg. She received intensive fluid administration (2000 cc crystalloid intravenous fluid) with prompt recover of blood pressure (130/70 mmHg) and heart rate (84 bpm). Chest examination showed bruises and crepitation on right hemithorax for multiple rib fractures and there was abdominal tenderness without signs of peritoneal irritation. Laboratory and arterial blood gas (ABG) analyses showed normal values, but haemoglobin 11.2 g/dl (normal range 12.0-15.5 g/dl),

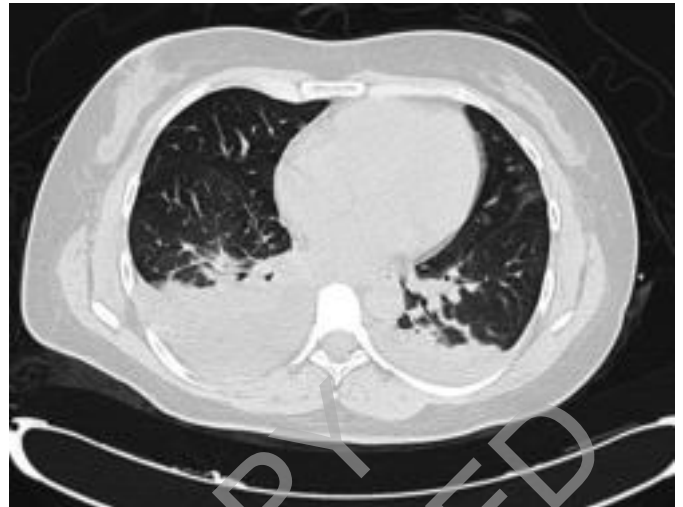

Fig. 3: CT scan (two days after trauma) showing bilateral pulmonary contusion and right pleural effusion.

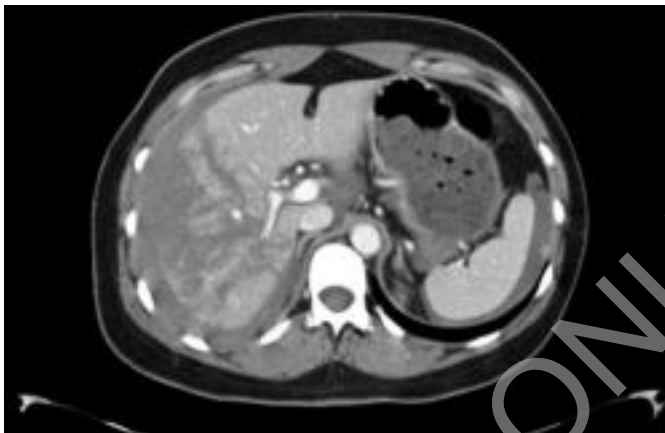


Fig. 1: CT scan showing a large liver laceration affecting V, VI and VII segments, associated with intraperitoneal perihepatic hemorrhage.

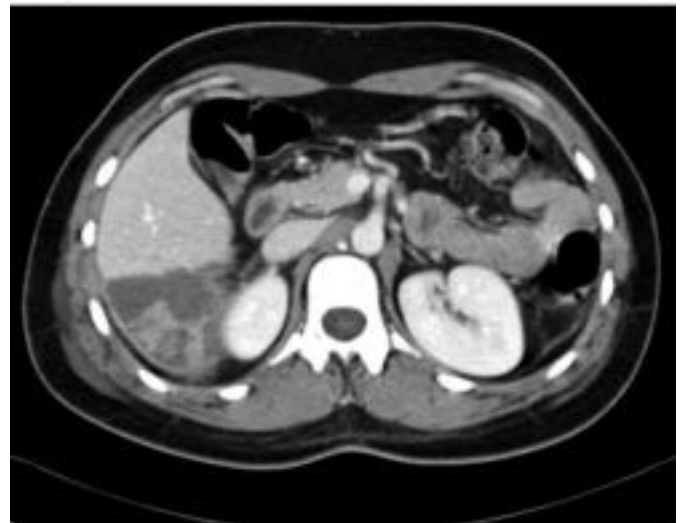
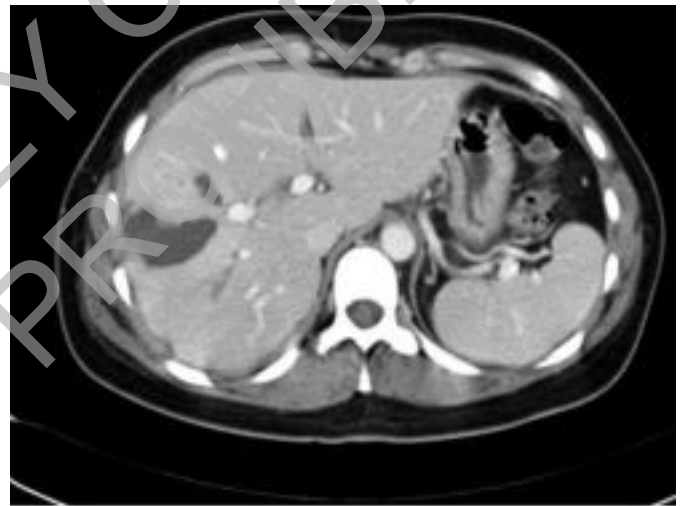
Fig. 4: CT scan (seven days after trauma) showing volumetric reduction of the liver lacerations, which appear to be more hypodense in relation to phenomena of parenchymal necrosis.

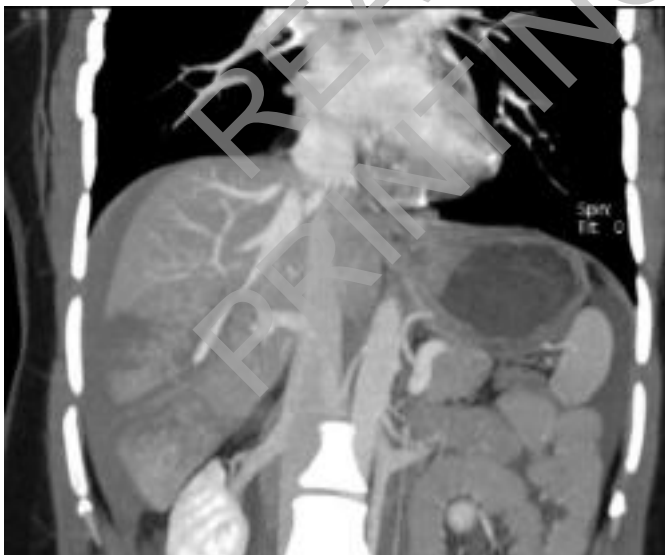

Fig. 2: CT scan (coronal view) – Some peripheral ramifications of the right branch of the portal vein are unrecognizable; in addition, one of the branches of the right suprahepatic vein appears reduced at its middle third and only distally returns to its regular caliber.

total leucocyte count of  $17.7 \times 10^3/\text{microL}$  (normal range  $4-10 \times 10^3 \text{ microL}$ ) and platelet count of  $495 \times 10^3 \text{ microL}$  (normal range  $150-450 \times 10^3 \text{ microL}$ ). A focused assessment sonography for trauma (F.A.S.T.) revealed the presence of a significant perihepatic and pelvic free fluid volume.

A thoraco-abdominal CT scan showed fracture of the lateral arch of VI, VII, VIII, IX ribs of the right hemithorax, with a mild contusion of the lower right lung lobe; a wide lacero-contusive area of V, VI and VII liver segments was present without evidence of active bleeding, but with a massive hemoperitoneum (Fig. 1 and 2). In spite of a second hemoglobin value of 8.5 g/dl, the hemodynamic stability with a blood pressure of 130/80 mmHg, pushed trauma leader to decide for a conservative non-operative treatment. The patient was transferred to the sub-intensive care unit and 2 blood red cell units were infused. Forty-eight hours after injury, the patient complained shortness of breath with a  $\text{pO}_2$  decrease (39 mmHg) and a  $\text{pCO}_2$  increase (37 mmHg). A new CT scan showed bilateral pulmonary contusion and pleural effusion, but a reduction in size of the lacero-contusive hepatic area (Fig. 3). A thoracentesis of the right hemithorax was performed (800cc of serosanguinous exudates) and continuous positive airway pressure (CPAP) therapy was started. After 4 days, the normal respiratory function was restored and a new CT scan demonstrated a definitive improvement of pulmonary and liver conditions (Fig. 4). At a 48-month follow-up the patient is going well without any trouble.

## Discussion

The liver is the most commonly injured organ in trauma<sup>2</sup>. In 95% of cases the cause of blunt trauma is a car accident. The mechanism of injury is most often indirect, like a deceleration, causing damage on capsule and parenchyma at the level of peritoneal reflections, usually between the anterior and posterior Couinaud segments of the right lobe. In other cases the injury mechanism is a direct one, a crushing trauma of the abdominal right upper quadrant, causing, as in our case, the compression of the ribs into the liver and a stellate-type injury.

Before the 1990s almost all blunt hepatic trauma were treated operatively. It was because liver hemorrhage was considered unable to stop without surgical intervention, bile was considered to be drained not to cause biliary fistulas or septic complications and because a positive diagnostic peritoneal lavage (DPL) could be considered due to other unexplored causes<sup>1-4</sup>. The wide diffusion of high-resolution CT scan and interventional radiology procedures together with several important clinical observations, transformed the diagnosis and management of blunt abdominal trauma<sup>1,6-14</sup>. Besides the successful

experiences with nonoperative management in pediatric patients<sup>4,7,15</sup>, it has been shown that 60% to 80% of the hepatic hemorrhage after blunt trauma had spontaneously stopped before laparotomy and that the absence of biliary drainage did not change morbidity<sup>16-19</sup>. Furthermore, despite concerns that nonoperative treatment could increase the need of transfusions and the length of hospital stay, most clinical studies reported exactly the opposite<sup>3,9</sup>.

According to the data of the National Trauma Data Bank, Tinkoff et al.<sup>20</sup> demonstrated that more than 85% blunt liver injuries are now managed nonoperatively, regardless of the injury severity. Overall success rates of the conservative approach ranges from 82% to 100%<sup>10,11,20-22</sup>, with decreasing success rates on the basis of the injury grade: 91.5% in grade I and II injuries, 79% in grade III, 72.8% in grade IV, and 62.6% in grade V injuries (5,22). In these series, it has been demonstrated that mortality rates have sensibly decreased passing from an operative treatment in all patients with hepatic injuries to a conservative management when possible<sup>1</sup>. In the 80s Cogbill et al. reported an overall mortality rate of 46% and a liver related mortality rate of 30% when all high grade liver traumas were operatively treated<sup>23</sup>. Asensio et al., using angioembolization combined to surgery, had an overall mortality of 9% for grades IV-V<sup>24,25</sup> and Patcher et al. reported a hepatic related mortality rate of 0.4%<sup>9</sup> considering all grades of liver injuries. More recently, Kozar et al. referring to high grade (III-V) injuries reported an overall mortality rate of 4.3% and only one liver related death among patients with grade V injuries<sup>21</sup>.

With the diffusion of NOM also for high grade liver injuries, it had been supposed that complication rates would have hugely increased, but conversely many studies showed that there has been a decrease of them<sup>5</sup>. Hepatic-related complication rates in most series are between 0% and 7%, also including low grade injuries<sup>26</sup>. Complications seems to be more closely related to the grade of liver injury and to the need for transfusion, with a reported rate of 14% among high grade injuries<sup>8</sup>. Kozar et al. reported an overall complication rate of 11% in high grade injuries nonoperatively treated: less than 1% for grade III, 21% for grade IV and 63% for grade V<sup>10,21</sup>. The most frequent postinjury complication is bleeding<sup>9,27,28</sup>, especially within the first 72 hours after trauma (27<sup>3</sup>); less common are hepatic and perihepatic abscesses, biloma, bile leak, biliary fistula and bile peritonitis<sup>4,29</sup>. Most of complications are usually managed with interventional radiology techniques like angioembolization, percutaneous or endoscopic drainage, biliary stenting, but sometimes surgery is required<sup>4,26</sup>.

Criteria for nonoperative management of liver injuries are hemodynamic stability, the absence of other abdominal injuries requiring surgical exploration, a hospital organization that allows immediate availability of analy-

sis laboratory, good quality CT imaging, interventional radiology and operating room, and 24-hour alert and experienced surgeons <sup>6,8</sup>. To monitor these patients we need serial hematocrit evaluations, coagulation value optimization and bed rest in subintensive or intensive care facilities <sup>6</sup>. A second CT scan is required only when unexpected abdominal pain, hemoglobin loss, jaundice, systemic inflammatory response syndrome (SIRS) occur <sup>30</sup> and not to check the injury evolution.

## Conclusions

Nonoperative management of blunt hepatic trauma should be the first choice when hemodynamic parameters are stable because of the many advantages in terms of morbidity, mortality and costs. It does not mean "no therapy", but it is instead synonymous of intense clinical observation of the patient, specific medical therapy, blood transfusion, high quality diagnostic evaluation, interventional radiology procedures, highly qualified nursing staff and, often, intensive care unit observation.

## Riassunto

Negli ultimi 20 anni il trattamento del trauma epatico chiuso si è modificato radicalmente passando da una gestione quasi costantemente chirurgica ad una non operativa in tutti i casi in cui non vi siano le condizioni di instabilità emodinamica o di variazione nella clinica del paziente traumatizzato. A tutt'oggi però non è raro osservare un approccio a tale condizione clinica seguendo criteri che la Medicina Basata sull'Evidenza dimostra essere superati.

Presentiamo in questo lavoro il caso clinico di una donna di 34 anni che subiva un trauma diretto della regione postero-laterale dell'emitorace destro cadendo accidentalmente da una scala. Nonostante la gravità della lesione evidenziata dalla TC (IV grado secondo AAST Liver Injury Scale), si è optato per un trattamento non operativo data la condizione di stabilità emodinamica ottenuta con un primo bolo di cristalloidi. Una complicanza di tipo respiratorio ha complicato il quadro in terza giornata dal trauma richiedendo una toracentesi e dei cicli di ventilazione non invasiva. A 4 anni di distanza dal trauma la paziente sta bene e non lamenta disturbi.

La letteratura mostra che il trattamento conservativo viene impiegato oggi in oltre l'85% dei traumi epatici, indipendentemente dall'entità della lesione. Il successo del trattamento conservativo varia nelle diverse casistiche dall'82% al 100% dei casi, e le sue complicanze, quando si verificano (14% dei traumi maggiori) possono spesso essere trattate con procedure di radiologia interventistica, evitando ancora l'intervento chirurgico. Oggi, in assenza di altre lesioni addominali che richiedano

l'esplorazione chirurgica, l'indicazione al trattamento operativo è solo l'instabilità emodinamica del paziente che persiste o si ripresenta subito dopo un corretto trattamento rianimatorio iniziale.

## References

1. Richardson DJ, Franklin GA, Lukan JK, Carrillo EH, Spain DA, Miller FB, Wilson MA, Polk HC Jr, Flint LM: *Evolution in the management of hepatic trauma: A 25-year perspective*. Ann Surg, 2000; 232:324-30.
2. Moore EE, Shackford SR, Pachter HL, McAninch JW, Browner BD, Champion HR, Flint LM, Gennarelli TA, Malangoni MA, Ramenofsky ML, Trafton PG: *Organ injury scaling: spleen liver and kidney*. J Trauma, 1995; 29:1664-666.
3. Croce MA, Fabian TC, Menke PG, Waddle-Smith L, Minard G, Kudsk KA, Patton JH Jr, Schurr MJ, Pritchard FE: *Nonoperative management of blunt hepatic trauma is the treatment of choice for hemodynamically stable patients. Results of a prospective trial*. Ann Surg, 1995; 221:744-55.
4. Piper GL, Peitzman AB: *Current management of hepatic trauma*. Surg Clin N Am, 2010; 90:775-85.
5. Kozar RA, Moore FA, Moore EE, West M, Cocanour CS, Davis J, Biffl WL, McIntyre RC Jr.: *Western Trauma Association critical decisions in trauma: Nonoperative management of adult blunt hepatic trauma*. J Trauma, 2009; 67:1144-148.
6. Hoff WS, Holevar M, Nagy KK, Patterson L, Young JS, Arrillaga A, Najarian MP, Valenziano CP: *Practice management guidelines for the evaluation of blunt abdominal trauma: the EAST practice management guidelines work group*. J Trauma, 2002;53:602-15.
7. Badger SA, Barclay R, Campbell P, Mole DJ, Diamond T: *Management of liver trauma*. World J Surg, 2009; 33:2522-537.
8. Polanco P, Leon S, Pineda J, Puyana JC, Ochoa JB, Alarcon L, Harbrecht BG, Geller D, Peitzman AB: *Hepatic resection in the management of complex injury to the liver*. J Trauma, 2008; 65:1264-270.
9. Pachter HL, Knudson MM, Esrig B, Ross S, Hoyt D, Cogbill T, Sherman H, Scalea T, Harrison P, Shackford S, Ochsner MG, Mucha Peter, Hofstetter SR, Guth A, Coffey S, Kataju S, Marburger R, Garcia J, Savage B, Henry S, Lippold, D, Trevesani, G, Steinig J: *Status of nonoperative management of blunt hepatic injuries in 1995: A multicenter experience with 404 patients*. J Trauma, 1996; 40:31-38.
10. Carrillo EH, Spain DA, Wohltmann CD, Schmieg RE, Boaz PW, Miller FB, Richardson JD: *Interventional techniques are useful adjuncts in nonoperative management of hepatic injuries*. J Trauma, 1999; 46:619-24.
11. Trunkey DD: *Hepatic trauma: Contemporary management*. Surg Clin N Am, 2004; 84:437-50.
12. Malhotra AK, Fabian TC, Croce MA, Gavin TJ, Kudsk KA, Minard G, Pritchard FE: *Blunt hepatic injury: A paradigm shift from operative to nonoperative management in the 1990s*. Ann Surg, 2000; 231:804-13.
13. Basile G, Chiarenza S, Di Mari P, Primus A, Boscarelli G, Buffone A, Cirino E: *The treatment of blunt abdominal trauma. Personal experience*. Ann It Chir, 2006; 77:149-54.

14. Chiara O, Cimbanassi S, Bini R, Pavesi L, Rampoldi A, Colombo F, Sansonna F, Pugliese R: *Nonoperative management of traumatic liver injuries*. Ann It Chir, 2005; 76:161-65.
15. Jiang H, Wang J: *Emergency strategies and trends in the management of liver trauma*. Front Med, 2012; 6:225-33.
16. Fabian TC, Croce MA, Stanford GG, Payne LW, Mangiante EC, Voeller GR, Kudsk KA: *Factors affecting morbidity following hepatic trauma. A prospective analysis of 482 patients*. Ann Surg, 1991; 213:540-48.
17. Meredith JW, Ditesheim JA, Stonehouse S, Wolfman N: *Computed tomography and diagnostic peritoneal lavage: complementary roles in blunt trauma*. Am Surg, 1992; 58:44-48.
18. Costa G, Tierno SM, Tomassini F, Venturini L, Frezza B, Cancrini G, Stella F: *The epidemiology and clinical evaluation of abdominal trauma. An analysis of a multidisciplinary trauma registry*. Ann It Chir, 2010; 81:95-102.
19. Clemente N, Di Saverio S, Giorgini E, Biscardi A, Villani S, Senatore G, Filiconi F, Antonacci N, Baldoni F, Tugnoli G: *Management and outcome of 308 cases of liver trauma in Bologna Trauma Center in 10 years*. Ann It Chir, 2011; 82:351-59.
20. Tinkoff G, Esposito TJ, Reed J, Kilgo P, Fildes J, Pasquale M, Meredith JW: *American Association for The Surgery of Trauma Organ Injury Scale I: Spleen, liver, and kidney, validation based on the National Trauma Data Bank*. J Am Coll Surg, 2008; 207:646-55.
21. Kozar RA, Moore JB, Niles SE, Holcomb JB, Moore EE, Cothren CC, Hartwell E, Moore FA.: *Complications of nonoperative management of high-grade blunt hepatic injuries*. J Trauma, 2005; 59:1066-71.
22. Leppäniemi AK, Mentula PJ, Streng MH, Koivikko MP, Handolin L: *Severe hepatic trauma: non operative management, definitive repair or damage control surgery?* World J Surg, 2011; 35:2643-49.
23. Cogbill TH, Moore EE, Jurkovich GJ, Feliciano DV, Morris JA, Mucha L: *Severe hepatic trauma: A multi-center experience with 1, 335 liver injuries*. J Trauma, 1988; 28:1433-438.
24. Asensio JA, Demetriades D, Chahwan S, Gomez H, Hanpeter D, Velmahos G, Murray J, Shoemaker W, Berne TV: *Approach to the management of complex hepatic injuries*. J Trauma, 2000;48:66-69.
25. Asensio JA, Roldán G, Petrone P, Rojo E, Tillou A, Kuncir E, Demetriades D, Velmahos G, Murray J, Shoemaker WC, Berne TV, Chan L: *Operative management and outcomes in 103 AAST-OIS grades IV and V complex hepatic injuries: trauma surgeons still need to operate, but angioembolization helps*. J Trauma, 2003; 54:647-54.
26. Velmahos GC, Toutouzas K, Radin R, Chan L, Rhee P, Tillou A, Demetriades D: *High success with nonoperative management of blunt hepatic trauma*. Arch Surg, 2003; 138:475-81.
27. Kozar RA, Moore FA, Cothren CC, Moore EE, Sena M, Bulger EM, Miller CC, Eastridge B, Acheson E, Brundage SI, Tataria M, McCarthy M, Holcomb JB: *Risk factors for hepatic morbidity following nonoperative management*. Arch Surg, 2006; 141:451-59.
28. Lee SK, Carrillo EH: *Advances and changes in the management of liver injuries*. Am Surg, 2007; 73:201-06.
29. Kozar RA, McNutt MK: *Management of adult blunt hepatic trauma*. 2010; 16:596-601.
30. Cuft RF, Cogbill TH, Lambert PJ: *Nonoperative management of blunt liver trauma: The value of follow up abdominal computed tomographic scans*. Am Surg, 2000; 66:332-36.

READ-ONLY COPY  
PRINTING PROHIBITED